



ELSEVIER

Available online at

ScienceDirect

www.sciencedirect.com

Elsevier Masson France

EM|consulte

www.em-consulte.com/en



CLINICAL RESEARCH

Transcatheter pulmonary valvuloplasty in neonates with pulmonary atresia and intact ventricular septum

Valvuloplastie pulmonaire percutanée chez les nouveau-nés ayant une atrésie pulmonaire à septum intact

Sébastien Hascoët*, Suzanne Borromée, Nabil Tahhan, Jérôme Petit, Angele Boet, Lucile Houyel, Emmanuel Lebret, Mohammed Ly, Régine Roussin, Emre Belli, Virginie Lambert, Daniela Laux

Pôle des cardiopathies congénitales de l'enfant et de l'adulte, centre de référence malformations cardiaques congénitales complexes (M3C), hôpital Marie-Lannelongue, université Paris-Sud, université Paris-Saclay, 133, avenue de la Résistance, 92350 Le Plessis-Robinson, France

Received 29 April 2018; received in revised form 20 November 2018; accepted 21 November 2018

KEYWORDS

Pulmonary atresia with intact ventricular septum; Pulmonary valve stenosis; Balloon valvuloplasty; Catheterization; Radiofrequency perforation

Summary

Background. — Transcatheter pulmonary valvuloplasty in neonates with pulmonary atresia and intact ventricular septum (PA-IVS) or duct-dependent pulmonary valve stenosis (DD-PVS) has become a reasonable alternative to surgical right ventricle decompression.

Aim. — To investigate mid-term outcomes following pulmonary valvuloplasty.

Methods. — Sixty-five neonates with PA-IVS ($n = 29$) or DD-PVS ($n = 36$) (median age 4 days; mean weight 3.0 kg) undergoing pulmonary valvuloplasty were reviewed retrospectively. Procedural data and clinical outcomes were assessed.

Results. — Pulmonary valvuloplasty was successful in 59 patients (90.8%). Preterm birth, larger tricuspid valve annulus diameter and PA-IVS correlated with procedural failure. Eleven patients (18.6%) required a Blalock-Taussig shunt during early follow-up, despite valvuloplasty. These

Abbreviations: BT, Blalock-Taussig; CI, Confidence Interval; DD-PVS, Duct-Dependent Pulmonary Valve Stenosis; PA-IVS, Pulmonary Atresia and Intact Ventricular Septum; PV, Pulmonary Valve; TV, Tricuspid Valve.

* Corresponding author.

E-mail address: s.hascoet@hml.fr (S. Hascoët).

<https://doi.org/10.1016/j.acvd.2018.11.015>

1875-2136/© 2019 Elsevier Masson SAS. All rights reserved.

Please cite this article in press as: S. Hascoët, S. Borromée, N. Tahhan, et al.. Transcatheter pulmonary valvuloplasty in neonates with pulmonary atresia and intact ventricular septum. Arch Cardiovasc Dis (2019), <https://doi.org/10.1016/j.acvd.2018.11.015>

neonates had smaller tricuspid and pulmonary valve annulus Z-scores (-1.9 vs. -0.8 [$p=0.04$] and -2.5 vs. -0.9 [$P=0.005$], respectively) and a higher incidence of “bipartite” right ventricle ($P=0.02$). Mean follow-up was 5.4 ± 3.3 years. Mortality after successful valvuloplasty was 8.5% ($n=5$). Among the 54 survivors, biventricular repair was achieved in 52 patients (96.3%), including nine with a previous Blalock-Taussig shunt. The cumulative rate of subsequent surgery (excluding Blalock-Taussig shunt) was 13.7% (95% confidence interval 6.8–26.7%) and 16.4% (95% confidence interval 8.5–30.4%) at 2 and 4 years, respectively. Secondary surgery was significantly more frequent in PA-IVS compared with DD-PVS, and in neonates with a Blalock-Taussig shunt ($P=0.003$ and 0.01, respectively).

Conclusions. – Selected neonates with DD-PVS or PA-IVS managed by transcatheter pulmonary valvuloplasty had a good mid-term outcome. In neonates with a borderline small right ventricle, a hybrid strategy with a supplementary source of pulmonary blood flow can be efficient to achieve biventricular repair.

© 2019 Elsevier Masson SAS. All rights reserved.

MOTS CLÉS

Intervention
cardiovasculaire ;
Valvuloplastie
pulmonaire
percutanée ;
Perforation par radio
fréquence

Résumé

Contexte. – La valvuloplastie pulmonaire percutanée est devenue une alternative à la décompression chirurgicale du ventricule droit chez les nouveau-nés ayant une atrésie pulmonaire à septum intact (APSI) ou une sténose valvulaire pulmonaire critique (SVPC).

Objectif. – Nous avons étudié les résultats de cette procédure et le devenir à moyen terme.

Méthodes. – Soixante-cinq nouveau-nés ayant une APSI ($n=29$) ou une SVPC ($n=36$) (âge médian 4 j ; poids moyen 3 kg) et ayant eu une valvuloplastie pulmonaire percutanée ont été rétrospectivement inclus. Les données des procédures et le devenir clinique à moyen terme ont été étudiés.

Résultats. – La valvuloplastie pulmonaire percutanée a été réussie dans 59 cas (90,8 %). Les prématurés, un anneau tricuspide large et l’APSI étaient corrélés au risque d’échec. Onze patients (18,6 %) ont nécessité une anastomose de Blalock-Taussig durant le suivi précoce malgré la valvuloplastie. Ces nouveau-nés avaient des Z-scores des anneaux tricuspide et pulmonaire plus bas ($-1,9$ vs $-0,8$ [$p=0,04$] et $-2,5$ vs $-0,9$ [$p=0,005$], respectivement) et une incidence plus élevée de ventricule droit bipartite ($p=0,02$). Le suivi moyen a été de $5,4 \pm 3,3$ ans. La mortalité après valvuloplastie pulmonaire a été de 8,5 % ($n=5$). Parmi les 54 survivants, 52 (96,3 %) ont évolué vers une circulation biventriculaire, incluant 9 patients avec précédemment une anastomose de Blalock-Taussig. L’incidence cumulée d’une réintervention chirurgicale (autre qu’une anastomose de Blalock-Taussig) durant le suivi était de 13,7 % (IC95 % 6,8–26,7 %) et 16,4 % (IC95 % 8,5–30,4 %) à 2 et 4 ans respectivement. Une réintervention était plus fréquente chez les nouveau-nés avec APSI et chez les nouveau-nés ayant eu une anastomose de Blalock-Taussig ($p=0,003$ et 0,01, respectivement).

Conclusions. – Les nouveau-nés ayant une APSI ou une SVPC sélectionnés pour la valvuloplastie pulmonaire percutanée ont un bon devenir à moyen terme. Chez les nouveau-nés avec un ventricule droit moyennement hypoplasique, une stratégie hybride avec source additionnelle de flux pulmonaire est efficace pour obtenir une circulation biventriculaire à terme.

© 2019 Elsevier Masson SAS. Tous droits réservés.

Background

Transcatheter pulmonary valvuloplasty in neonates with pulmonary atresia and intact ventricular septum (PA-IVS) has become a reasonable alternative to surgical right ventricle decompression [1]. Several techniques have been developed to perforate the atretic pulmonary valve (PV), such as puncturing with the stiff end of a guidewire and laser and radiofrequency perforation. Complications were common in the early stages of use – particularly right

ventricular outflow tract perforation. Recently, transcatheter pulmonary valvuloplasty has become a valuable therapeutic option in current practice [1]. However, given the rarity of this congenital heart disease, there is a paucity of data regarding clinical outcomes [1–4].

PA-IVS is a complex disease with significant morphological variability. The feasibility of biventricular repair is mainly related to the size of the right ventricle and to coronary anatomy. Transcatheter pulmonary valvuloplasty is currently recommended in neonates with favourable right

ventricular anatomy, excluding right ventricle-dependent coronary circulation [1,5,6]. In neonates with borderline small right ventricles, it remains unclear which patients will benefit from valvuloplasty. Few data are available on mid- and long-term outcomes. This study reviews our clinical results in neonates with PA-IVS managed with transcatheter pulmonary valvuloplasty.

Methods

Study design

Using a prospective database of catheterizations at a national referral centre for complex congenital heart disease (M3C network), we retrospectively reviewed 65 consecutive neonates with PA-IVS or duct-dependent PV stenosis (DD-PVS) undergoing pulmonary valvuloplasty from 2003 to 2015. DD-PVS was defined as critical PV stenosis, with cyanosis related to right-to-left shunt through a patent foramen ovale, and duct-dependent pulmonary artery circulation [1]. DD-PVS was included in this study as it shares a common neonatal clinical presentation and management strategy with PA-IVS [3,7]. Anatomically there can be an overlap between these two defects, as a tiny hole is sometimes observed in the PV during catheterization in neonates previously diagnosed as having PA-IVS on echocardiography. These neonates were then classified as having DD-PVS in this study.

Neonates were considered suitable for transcatheter pulmonary valvuloplasty when the right ventricle morphology was tripartite or bipartite, the tricuspid valve (TV) annulus diameter was > 7 mm and the TV annulus Z-score was > -2 . Neonates with DD-PVS and PA-IVS considered unsuitable candidates for transcatheter valvuloplasty were excluded; this included neonates with right ventricular duct-dependent circulation and/or severe right ventricle hypoplasia, who were managed surgically with a palliative approach for subsequent univentricular repair.

Demographic, clinical and echocardiographic data were collected. Catheterization data were analysed regarding technical details, results and complications. Echocardiograms were reviewed for primary diagnosis, TV annulus diameter, regurgitation peak gradient, PV annulus diameter and associated cardiac malformations. The TV annulus was measured in an apical four-chamber view in early diastole, and the PV annulus was measured in a short-axis parasternal view in early systole [8]. PV and TV annulus Z-scores were established based on weight and height at time of echocardiography, according to the methods described by Cantinotti et al. [9].

Catheterization was performed under conscious sedation in spontaneously breathing neonates or under mechanical ventilation, depending on haemodynamics and clinical condition. Femoral venous access was used in all neonates. Haemodynamic assessment and angiograms of the left and right ventricles were performed. The PV annulus was measured. Absence of right ventricle-dependent coronary circulation was assessed. In case of PV atresia, PV perforation was performed using radiofrequency. A 4-French Judkins right catheter or a Bernstein catheter was positioned along the right ventricular outflow tract.

Appropriate positioning was confirmed by repeated small manual injections of iodine contrast in a lateral view. A 0.025-inch Nykanen radiofrequency wire (Baylis Medical Company Inc., Montreal, Quebec, Canada) was introduced into the catheter positioned in the right ventricular outflow tract, directly beneath the atretic PV. Perforation was performed with 5–7 W of energy delivered, with up to 20–25 W in exceptional cases. A 0.014-inch guidewire was then positioned in the descending aorta across the PV and the ductus arteriosus. Balloon pulmonary valvuloplasty was performed in two steps. First a coronary balloon was used to dilate the valve and allow valve crossing with a bigger balloon. Then a Tyshak balloon (Numed, Inc. Hopkinton, NY, USA) corresponding to PV annulus size was used. Procedural success was defined by the establishment of an efficient antegrade flow through the PV, as assessed by angiography.

In neonates with a borderline small right ventricle size, a hybrid strategy, with supplementary Blalock-Taussig (BT) shunt serving as additional pulmonary blood flow, was used. The timing of the BT shunt surgery was not standardized, and was assessed in a case-by-case fashion. Ductus arteriosus stenting was not part of the management of PA-IVS and DD-PVS during the study period in our institution.

All complications occurring during the catheterization and index hospitalization were recorded. Major adverse events were defined as the need for permanent or temporary pacemaker, cardiac arrest, pericardial tamponade, embolic stroke, unplanned cardiac surgery or any complication leading to death. Otherwise, recorded adverse events were defined as minor. To assess short-term outcome, data on duration of mechanical ventilation, prostaglandin E1 infusion, in-hospital stay, need for early reintervention and morbidity were collected. Morbidity included all complications occurring after the procedure or during the index hospitalization: arrhythmia, leg ischaemia, pericardial or pleural effusions, digestive disorders (from mild to enterocolitis) and infections (defined by positive blood culture or cerebrospinal fluid, seizures, embolic stroke and haemodynamic shock). Early reintervention was defined as the need for surgery or another cardiac catheterization during the index hospitalization. Long-term follow-up was assessed in terms of catheterization, surgery and vital status. The latest follow-up data were collected at the end of the study period.

Statistical analysis

Statistical analyses were performed using Stata[®] software, version 11.2 (StataCorp, College Station, TX, USA). Continuous variables are expressed as means \pm standard deviations for normally distributed variables. The Shapiro-Wilk test was used to test the normality of the distribution of the variables. Otherwise, variables are expressed as medians [interquartile ranges]. Comparisons between measurements were performed using paired *t* tests or the Wilcoxon signed-rank test. A paired *t* test was used when variables were normally distributed, and after the homogeneity of variance was checked. Levene's test was used to assess the homogeneity of variance. When these conditions were not satisfied, a non-parametric Wilcoxon test was used. Categorical data was compared using a χ^2 test or Fisher's exact test.

Table 1 Demographics and procedural data.

	Total population (n = 65)	PA-IVS (n = 29)	DD-PVS (n = 36)	P
Gestational age (weeks)	38.1 ± 2.5	38.1 ± 2.0	38.1 ± 2.8	0.8
Intrauterine growth retardation < 10th percentile	8 (12.3)	2 (6.9)	6 (16.7)	0.3
Antenatal diagnosis	22 (33.8)	14 (48.3)	8 (22.2)	0.03
Male	42 (64.6)	20 (69.0)	22 (61.1)	0.5
Extracardiac anomalies	6 (9.2)	3 (10.3)	3 (8.3)	1.0
Associated cardiac malformations	20 (30.8)	10 (34.5)	10 (27.8)	0.6
Twins	11 (16.9)	2 (6.9)	9 (25.0)	0.09
Monochorionic diamniotic	8 (12.3)	2 (6.9)	6 (16.7)	0.3
Procedural data				
Age (days)	4 [2; 7]	2 [1; 6]	5 [2; 9]	0.1
Weight (kg)	3.0 ± 0.6	2.9 ± 0.5	3 ± 0.6	0.8
TV annulus diameter (mm)	9.6 [8.9; 12.7]	10.5 [9.2; 14.0]	9.0 [8.0; 11.8]	0.04
TV annulus Z-score	-0.8 ± 0.7	-0.4 ± 1.7	-1.2 ± 1.5	< 0.05
PV annulus diameter (mm)	6.8 ± 1.5	6.5 ± 1.8	7.0 ± 1.2	0.3
PV annulus Z-score	-1.4 [-2.3; -0.2]	-1.4 [-2.7; -0.2]	-1.1 [-2.0; -0.2]	0.5
Bipartite right ventricle	13 (20.0)	9 (31.0)	4 (11.1)	0.06
Tricuspid regurgitation ≥ grade 3	34 (52.3)	17 (58.6)	17 (47.2)	0.5
Mechanical ventilation	33 (50.8)	20 (69.0)	13 (36.1)	0.008
PV dilation	59 (90.8)	23 (79.3)	36 (100)	0.006
Maximum balloon diameter (mm)	8 [6; 8]	8 [6; 8]	8 [8; 8]	0.09
Balloon/PV diameter	1.2 [1.1; 1.4]	1.2 [1.1; 1.6]	1.2 [1.1; 1.4]	0.8

Data are expressed as mean ± standard deviation, number (%) or median [interquartile range]. DD-PVS: duct-dependent pulmonary valve stenosis; PA-IVS: pulmonary atresia and intact ventricular septum; PV: pulmonary valve; TV: tricuspid valve.

Kaplan-Meier curves of time to clinical events (i.e. re-intervention by surgery or catheterization) were plotted using months since neonatal percutaneous pulmonary valvuloplasty as the time scale. Differences between cumulative rates of reintervention among patients with DD-PVS or PA-IVS and among patients with or without BT shunt were assessed using the log-rank test. A *P*-value < 0.05 was considered statistically significant. The study was approved by the local ethics research committee. The study database was declared to the National Commission on Data Processing and Freedoms (Commission nationale de l'informatique et des libertés; CNIL n° 1837880).

Results

During the study period, 65 neonates underwent transcatheter pulmonary valvuloplasty: 29 had PA-IVS (44.6%) and 36 had DD-PVS (55.4%) (Table 1). The median age at the time of the procedure was 4 [2; 7] days (ranging from 0 to 22 days). The mean weight was 3.0 ± 0.6 kg (ranging from 1.4 to 4.3 kg). There were eleven twin pregnancies (16.9%), including eight monochorionic diamniotic twins (12.3%). Six patients had additional congenital disease, including Down syndrome (*n* = 1), Di-George syndrome (*n* = 1), corpus callosum agenesis with microcephalia (*n* = 1), ureterocele (*n* = 1), kidney dysplasia (*n* = 1) and choanal atresia (*n* = 1).

Associated cardiac abnormalities were observed in 20 patients (30.8%, 95% confidence interval [CI] 19.9–43.4%). These lesions were mostly tricuspid abnormalities (*n* = 17), including Ebstein's anomaly (*n* = 8), tricuspid stenosis (*n* = 5) and tricuspid dysplasia (*n* = 4). Two patients had coronary artery sinusoids without right ventricle-dependent coronary circulation in addition to Ebstein's anomaly. Two patients had small ventricular septal defects (one membranous, one muscular). One patient had a sinus venosus atrial septal defect.

Catheterization was performed in spontaneously breathing neonates under conscious sedation in 21 cases (32.8%). Median valvuloplasty balloon size was 8 [6; 8] mm (ranging from 4.5 to 12.0 mm). Median PV diameter to balloon ratio was 1.2 [1.1; 1.4] (ranging from 1.0 to 2.0). Transcatheter pulmonary valvuloplasty was successfully achieved in 59 patients (90.8%, 95% CI 81.0–96.5). The success rate was higher in neonates with DD-PVS than in neonates with PA-IVS (100%, 95% CI 90.3–100% vs. 79.3%, 95% CI 60.3–92.0; *P* = 0.006). The success rate tended to be higher in the last 5 years of experience (96.6%, 95% CI 82.2–99.9 vs. 86.5%, 95% CI 71.2–95.5). Before valvuloplasty, the mean right ventricular systolic pressure was 85.2 ± 23.9 mmHg. The left ventricular systolic pressure was 55.1 ± 9.2 mmHg. The right-to-left ventricle systolic pressure ratio was 1.6 ± 0.4. After successful pulmonary valvuloplasty, the right ventricular systolic pressure decreased to 43.3 ± 16.1 mmHg.

Table 2 Demographics and procedural data in neonates with versus without successful transcatheter pulmonary valvotomy.

	Failure (n = 6)	Success (n = 59)	P
Demographics			
PA-IVS	6 (100)	23 (39.0)	0.006
Male	3 (50.0)	39 (66.1)	0.7
Antenatal diagnosis	3 (50.0)	19 (32.2)	0.4
Premature	3 (27.2)	6 (11.1)	0.03
Intrauterine growth retardation < 10th percentile	0 (0.0)	8 (13.6)	1.0
Associated cardiac malformations	1 (16.7)	17 (28.8)	1.0
Extracardiac anomalies	1 (16.7)	7 (11.9)	0.6
Before catheterization			
Age (days)	3 [1; 6]	4 [2; 7]	0.4
Weight (kg)	2.8 ± 0.4	3.0 ± 0.6	0.5
Bipartite right ventricle	2 (33.3)	11 (18.6)	0.6
Tricuspid regurgitation ≥ grade 3	5 (83.3)	29 (49.2)	0.2
PV annulus diameter (mm)	6.8 ± 1.5	6.8 ± 1.5	0.9
PV annulus Z-score	-1.4 [-2.2; -0.2]	-1.5 [-2.5; -0.2]	0.8
TV annulus diameter (mm)	12.8 [11.0; 14.0]	9.5 [8.6; 12.0]	0.03
TV annulus Z-score	0.5 ± 1.0	-1.0 ± 1.6	0.03
RV/LV systolic pressure ratio	1.5 ± 0.5	1.6 ± 0.4	0.9

Data are expressed as number (%), median [interquartile range] or mean ± standard deviation. LV: left ventricular; PA-IVS: pulmonary atresia and intact ventricular septum; PV: pulmonary valve; RV: right ventricular; TV: tricuspid valve.

($P < 0.0001$) while the left ventricular systolic pressure remained stable (56.1 ± 10.9 mmHg; $P = 0.3$). The right-to-left ventricle systolic pressure ratio decreased to 0.8 ± 0.3 ($P < 0.0001$). Peripheral arterial oxygen saturation increased from $85.8 \pm 10.3\%$ to $92.8 \pm 6.6\%$ ($P < 0.0001$). Haemodynamics after successful transcatheter pulmonary valvuloplasty were similar in patients with PA-IVS and DD-PVS. Comparisons of baseline variables between neonates with successful and unsuccessful procedures are reported in Table 2. Failed procedures were only observed in PA-IVS, and more often in premature babies. Neonates with failed procedures had a larger TV annulus diameter ($P = 0.03$), and a trend towards more severe tricuspid regurgitation.

Early outcomes

Technical success (n = 59)

Forty cases (77.8%) required postprocedural admission to the intensive care unit. In these cases, median length of stay was 5 [2; 9] days. In neonates with a successful procedure performed under mechanical ventilation ($n = 43$), extubation occurred within 24 hours in 15 cases (23.4%). In other cases, ventilation duration ranged from 2 to 25 days. Postprocedural prostaglandin E1 infusion was required in 49 cases (83.1%), for a median of 4 [2; 9] days, ranging from 1 to 20 days. The median length of hospitalization after catheterization was 7 [4; 17] days.

Complications and mortality

Pulmonary valvuloplasty was unsuccessful in six cases. Two patients had a pericardial tamponade as a result of perforation of the pulmonary artery by the radiofrequency

guidewire; one died in the catheterization laboratory, and one underwent successful rescue surgery with surgical pulmonary valvotomy and BT shunt. The remaining four neonates with unsuccessful procedures were managed surgically with pulmonary valvotomy and a complementary BT shunt; one died of heart failure 2 days after the surgery.

Deaths occurred in five other cases, 2 to 10 days after successful catheterization (8.5%, 95% CI 2.8–18.7%); one had a complementary BT shunt. Deaths were related to septicaemia (*Staphylococcus aureus*, $n = 1$), necrotizing enterocolitis in a patient requiring prostaglandin E1 and heart failure ($n = 3$). Four of these five patients had severe tricuspid regurgitation.

Overall, mortality ($n = 7$ [10.8%], 95% CI 4.4–20.9%) was only observed in neonates with PA-IVS (24.1%, 95% CI 10.3–43.5%). Severe complications occurred in six patients (one severe stroke, four cases of septic shock, one operated necrotizing enterocolitis). Severe complications and death were observed in 13 cases (20.0%, 95% CI 11.1–31.8%). Considering only neonates with successful procedures, severe complications and death were observed in 11 cases (18.6%, 95% CI 9.7–30.9%).

Minor complications were reported in 19 patients (29.3%, 95% CI 18.6–41.8%), including minor digestive symptoms, resolved arrhythmia, transient leg ischaemia, transient renal failure ($n = 1$) and transient hypothyroidism ($n = 1$).

Overall, deaths, major adverse events and/or unsuccessful procedures occurred in 17 cases (26.2%, 95% CI 16.0–38.5%). Comparisons of baseline data between neonates with favourable versus unfavourable short-term outcomes are reported in Table 3. An unfavourable outcome was more often observed in neonates with PA-IVS ($P < 0.001$) and younger age at catheterization ($P = 0.0008$).

Table 3 Demographics and procedural data in neonates according to short-term outcome.

	Died/unsuccesful catheterization/major adverse events (n = 17)	Successful procedure with favourable early outcome (n = 48)	P
Demographics			
PA-IVS	14 (82.4)	15 (31.3)	<0.001
Male	10 (58.8)	32 (66.7)	0.6
Antenatal diagnosis	9 (52.9)	13 (27.1)	0.08
Premature	3 (17.7)	6 (12.5)	0.7
Intrauterine growth retardation < 10th percentile	1 (5.9)	7 (14.6)	0.7
Associated cardiac malformations	4 (23.5)	14 (29.2)	0.8
Extracardiac anomalies	2 (11.8)	6 (12.5)	1.0
Before catheterization			
Age (days)	2 [1; 4]	5 [2; 8]	0.0008
Weight (kg)	2.9 ± 0.4	3.0 ± 0.6	0.3
Bipartite right ventricle	5 (29.4)	8 (16.7)	0.3
Tricuspid regurgitation ≥ grade 3	12 (70.6)	22 (45.8)	0.1
PV annulus diameter (mm)	6.2 ± 1.9	7.0 ± 1.3	0.2
PV annulus Z-score	-1.4 [-2.9; -0.2]	-1.3 [-2.1; -0.2]	0.6
TV annulus diameter (mm)	11.5 [9.3; 13.8]	9.4 [8.5; 11.9]	0.1
TV annulus Z-score	-0.3 ± 1.8	-1.1 ± 1.5	0.1
RV/LV systolic pressure ratio	1.6 ± 0.5	1.6 ± 0.4	0.4

Data are expressed as number (%), median [interquartile range] or mean ± standard deviation. LV: left ventricular; PA-IVS: pulmonary atresia and intact ventricular septum; PV: pulmonary valve; RV: right ventricular; TV: tricuspid valve.

Table 4 Demographics and procedural data in neonates with versus without a Blalock-Taussig shunt after successful transcatheter pulmonary valvotomy.

	No BT shunt (n = 48)	BT shunt (n = 11)	P
Demographics			
PA-IVS	17 (35.4)	6 (54.6)	0.3
Intrauterine growth retardation < 10th percentile	5 (10.4)	3 (27.3)	0.2
Prematurity	6 (12.5)	0 (0.0)	0.6
Antenatal diagnosis	16 (33.3)	3 (27.3)	1.0
Male	32 (66.7)	7 (63.7)	1.0
Associated cardiac malformations	13 (27.1)	4 (36.4)	0.7
Extracardiac anomalies	4 (8.3)	2 (18.2)	0.3
Before catheterization			
Age (days)	4 [2; 7]	3 [2; 6]	0.4
Weight (kg)	3.0 ± 0.6	2.9 ± 0.6	0.8
PV annulus diameter (mm)	7.1 ± 1.2	5.4 ± 1.7	0.0003
PV annulus Z-score	-0.9 [-1.9; -0.1]	-2.5 [-5.0; -1.4]	0.005
TV annulus diameter (mm)	10.0 [8.9; 13.5]	9.0 [7.0; 9.5]	0.02
TV annulus Z-score	-0.8 ± 1.7	-1.9 ± 0.9	0.04
Tricuspid regurgitation ≥ grade3	24 (50.0%)	5 (45.5%)	1.0
Bipartite RV	6 (12.5%)	5 (45.5%)	0.02
RV systolic pressure (mmHg)	82.8 ± 22.7	98.0 ± 27.4	0.08
RV/LV systolic pressure ratio	1.5 ± 0.4	1.9 ± 0.6	0.03
After catheterization			
RV systolic pressure (mmHg)	42.0 ± 12.5	50.3 ± 28.7	0.2
RV/LV pressure ratio	0.8 ± 0.2	1.0 ± 0.6	0.07

Data are expressed as number (%), median [interquartile range] or mean ± standard deviation. BT: Blalock-Taussig; LV: left ventricular; PA-IVS: pulmonary atresia and intact ventricular septum; PV: pulmonary valve; RV: right ventricular; TV: tricuspid valve.

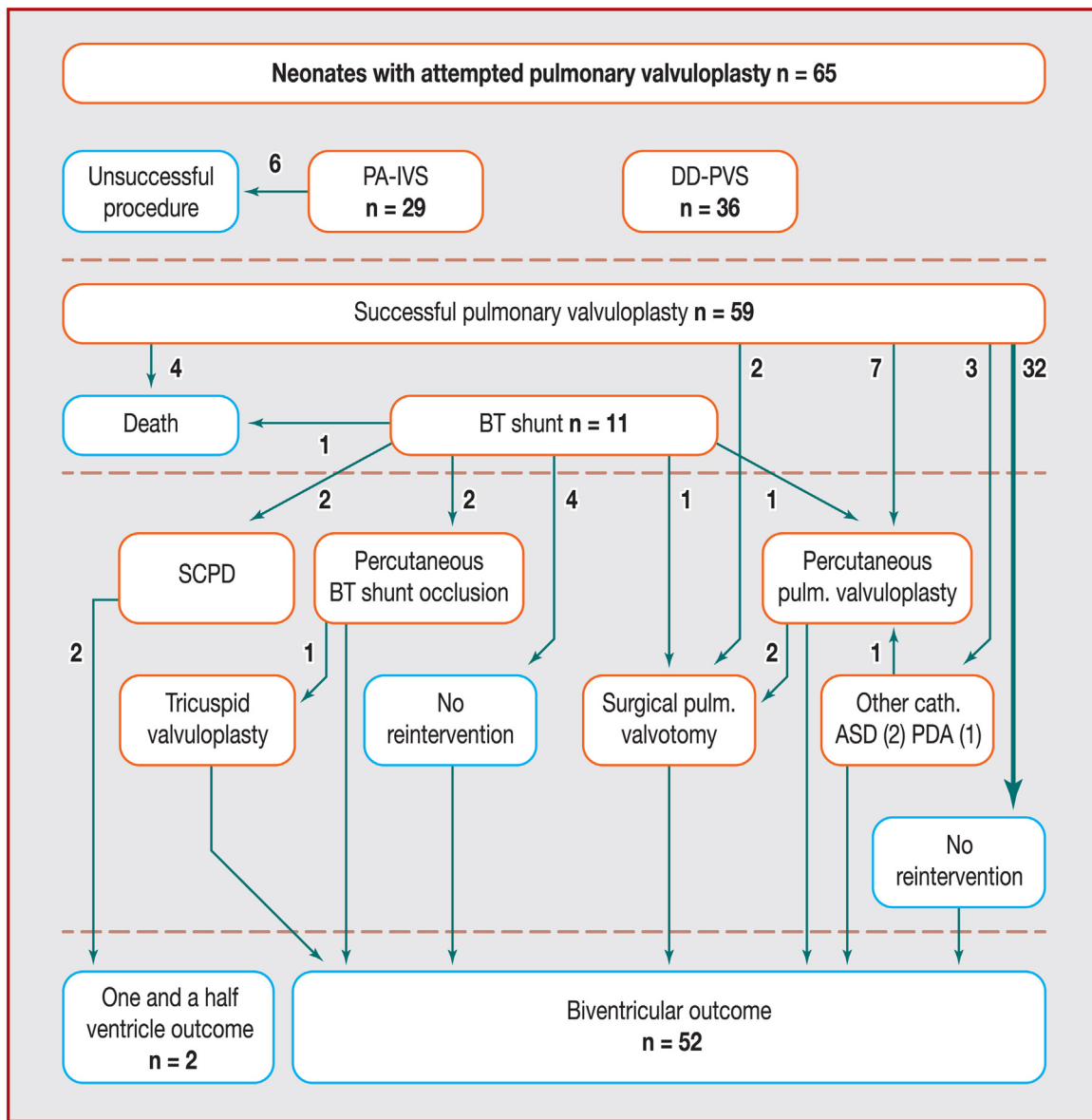


Figure 1. Flow chart displaying short- and long-term outcomes of neonates with attempted transcatheter pulmonary valvuloplasty. ASD: atrial septal defect; BT: Blalock-Taussig shunt; DD-PVS: duct-dependent pulmonary valve stenosis; PA-IVS: pulmonary atresia with intact ventricular septum; PDA: patent ductus arteriosus; Pulm.: pulmonary; SCPD: superior cavopulmonary derivation.

BT shunt

In neonates with successful transcatheter valvuloplasty, a BT shunt was required in 11 cases (18.6%, 95% CI 9.7–30.9%). No ductus arteriosus stenting was performed. Details of neonates with a BT shunt compared with neonates without a BT shunt are reported in Table 4. Neonates requiring a BT shunt had a smaller TV annulus ($P=0.02$; Z-score, $P=0.04$), a smaller PV annulus ($P=0.0003$; Z-score, $P=0.005$) and a higher incidence of bipartite right ventricle ($P=0.02$). Neonates with a BT shunt had a longer duration of mechanical ventilation (8 [3; 11] vs. 1 [0–; 3] days; $P<0.0001$), a longer intensive care unit stay (10 [7; 13] vs. 2 [0; 4] days; $P<0.0001$), a longer in-hospital stay (20 [14; 29] vs. 10 [7; 19] days; $P=0.008$) and a higher rate of major adverse events (12.5% vs. 45.5%; $P=0.02$).

Mid-term outcome (n = 54)

Mean follow-up duration was 5.4 ± 3.3 years. Four patients (7.4%) were lost to follow-up. No late death was reported. Patient outcomes are illustrated in Fig. 1. Kaplan-Meier curves displaying cumulative reintervention rate following successful pulmonary valvuloplasty are shown in Fig. 2. Complementary surgical procedures (excluding BT shunt during neonatal care) were required in eight cases, including bidirectional cavopulmonary anastomosis ($n=2$), surgical pulmonary valvotomy ($n=4$) with atrial septal defect closure ($n=1$) and tricuspid valvuloplasty ($n=1$). The cumulative need for late surgery was 13.7% (95% CI 6.8–26.7%) and 16.4% (95% CI 8.5–30.4%) at 2 and 4 years respectively; it was significantly higher in PA-IVS compared with DD-PVS, and

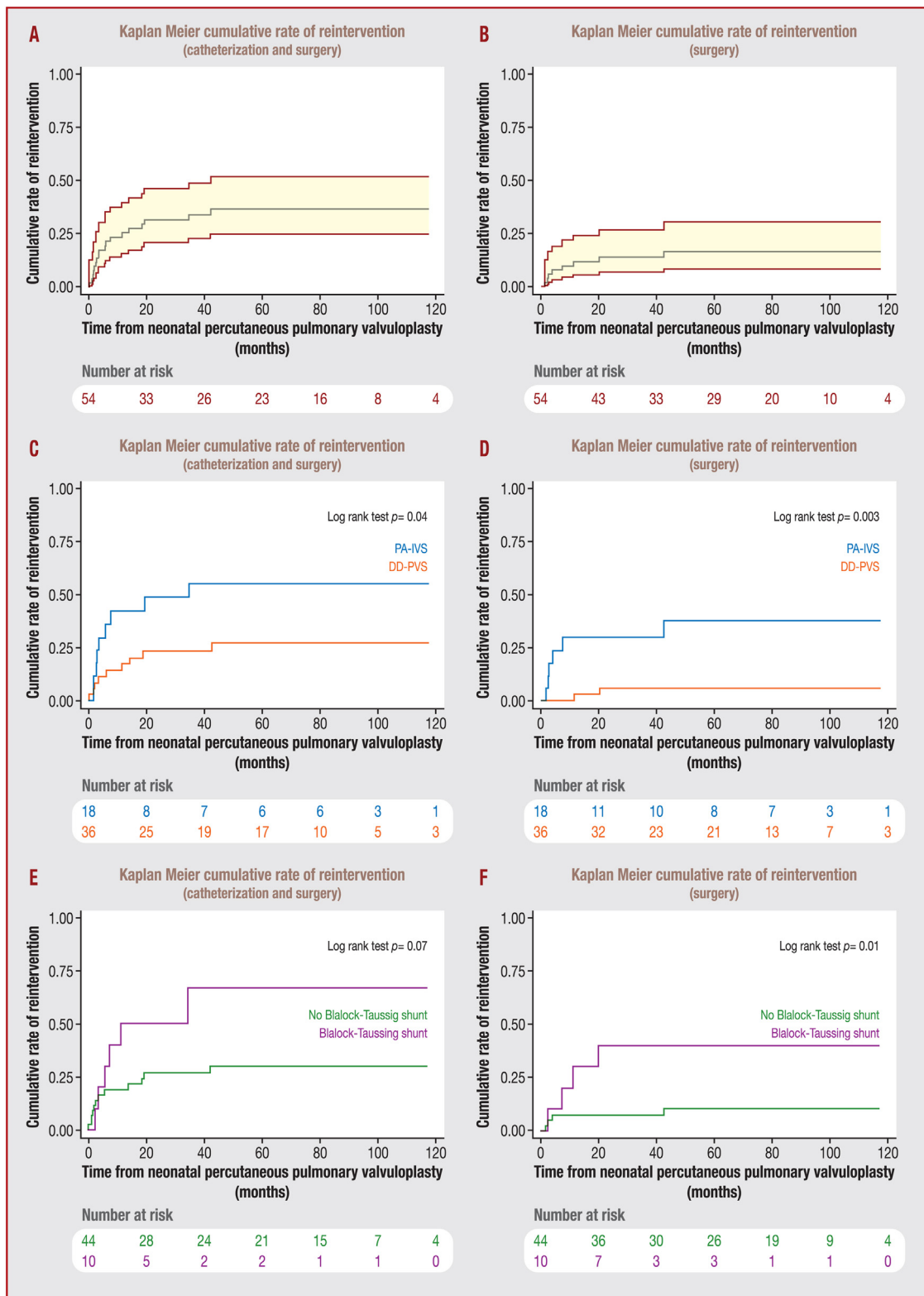


Figure 2. Kaplan-Meier curves displaying cumulative reintervention rate following successful pulmonary valvuloplasty. DD-PVS: duct-dependent pulmonary valve stenosis; PA-IVS: pulmonary atresia with intact ventricular septum.

in neonates with a BT shunt ($P=0.003$ and 0.01). Interventional catheterizations were required in 13 cases, including repeat transcatheter pulmonary valvuloplasty ($n=9$), atrial septal defect closure ($n=2$), patent ductus arteriosus

closure ($n=1$) and BT shunt occlusion ($n=2$). The cumulative reintervention rate by surgery or catheterization was 31.3% (95% CI 20.5–46.0%) and 36.4% (95% CI 24.6–31.7%) at 2 and 4 years, respectively; it was significantly higher

in PA-IVS compared with DD-PVS ($P=0.04$). At the end of follow-up, pulmonary regurgitation \geq grade 3, tricuspid regurgitation \geq grade 2 and dyspnoea were reported in 28.9%, 16.7% and 7.0%, respectively.

Discussion

This study reports early and mid-term outcomes of 65 consecutive neonates with PA-IVS or DD-PVS treated by transcatheter pulmonary valvuloplasty. The study included patients considered suitable to achieve biventricular repair, with a tripartite or bipartite right ventricle and mild tricuspid hypoplasia. The pulmonary valvuloplasty success rate was $> 90\%$. PA-IVS, preterm birth and younger age were associated with procedural failure, major adverse events and death. The postprocedural need for a BT shunt was associated with smaller PV and TV, and bipartite right ventricle. Neonates with a BT shunt had longer mechanical ventilation, a longer in-hospital stay and higher morbidity than those who did not require a source of supplementary pulmonary blood flow. Reintervention was a common event in this series, with 31% needing interventional or surgical reintervention in the 2 years following initial valvuloplasty.

Transcatheter pulmonary valvuloplasty for neonates with PA-IVS and DD-PVS has become the gold-standard procedure in appropriately selected patients [10]. In this single-centre study, the technical success of pulmonary valvuloplasty was high, particularly in the current era, as previously reported [2–4,11–17]. Procedural failures were mostly observed at the start of our experience, and were always related to the inability to perforate the atretic PV, which is the technical challenge. Despite DD-PS and PA-IVS sharing common anatomical features and management strategies, our series shows that valvuloplasty is more successful in DD-PS, and fails more often in PA-IVS. It is not the decompression of the right ventricle that represents the true procedural challenge, but more the valvular perforation that is technically complex, and can lead to catastrophic complications [4]. Transthoracic echocardiography may be useful to guide the procedure [18]. Additionally, premature infants appear to be at increased risk of procedural failure, potentially as a result of smaller vascular access and higher myocardial fragility.

Periprocedural mortality was high in early reports, approaching 50%. In our cohort, periprocedural complications leading to death were observed in 10% of cases, as similarly described in recent reports [2–4,19,20]. Mortality and morbidity are not only related to the technical aspects of the procedure, but also to associated cardiac abnormalities, particularly TV regurgitation or extracardiac malformations [7]. A 100% procedural success rate without mortality was reported in a selected patient group, with neither tricuspid hypoplasia nor anomalies of the TV [2]. Half of the neonates in our study had significant tricuspid regurgitation caused by a dysplastic valve or Ebstein's anomaly. A larger TV annulus (a surrogate of severe regurgitation) was associated with procedural failure in our study, but not with death and major adverse events. In patients with a patent ductus arteriosus, severe tricuspid regurgitation can lead to high-output cardiac failure after right ventricular decompression [19]. Interestingly, with regard

to mid-term outcomes, tricuspid regurgitation appeared to be a favourable marker of right ventricular development and growth and biventricular evolution in a multicentre study [7].

The BT shunt has long been established as the surgical approach to providing a supplementary source of pulmonary blood flow in patients with PA-IVS or DD-PS requiring prolonged postprocedural prostaglandin E1 support. Neonates with PA-IVS or DD-PS with smaller TVs and PVs, as well as bipartite right ventricle, were more likely to require subsequent intervention after valvuloplasty in our study and others [2–4,7,21]. BT shunt surgery carries an associated risk of mortality and morbidity. As expected, neonates having to undergo a BT shunt operation had longer intensive care unit and hospital stays, as well as a longer duration of mechanical ventilation. Twenty per cent of patients in our study needed a BT shunt as a complementary source of pulmonary blood flow—a higher rate than that reported in other studies. However, these studies included ductus arteriosus stenting, which provided complementary palliation in almost 50% of cases [19].

Ductus arteriosus stenting has become a valuable alternative to BT shunt palliation [3,22–24]; it is a complex procedure, with a failure risk of 17% in a multicentre study and an increased risk of complications compared with other stenting procedures in congenital heart disease [25,26]. Ductus arteriosus stenting is often performed at the same time as pulmonary valvuloplasty, and can reduce hospital stay in well-trained teams [19].

Thus far, our strategy has relied on the close follow-up of right ventricle evolution following the procedure. In the case of ductal-dependent pulmonary perfusion with bipartite right ventricle, BT shunt was performed after the initial catheterization. In other cases, with borderline right ventricular function, weaning of prostaglandin E1 support was feasible up to 2 weeks after the catheterization, and eliminated or postponed the need for complementary palliation. With this standardized approach, the rate of BT shunt was $< 3\%$ [20]. In this study, reintervention was only indicated in patients who failed to be weaned from prostaglandin E1 infusion 14 days after cardiac catheterization. Prostaglandin E1 was continued if oxygen saturation was $\leq 70\%$, or for metabolic acidosis. Prostaglandin E1 support carries an increased risk of adverse effects, such as enterocolitis; its potential side effects must be balanced against the expected benefits from postponing or avoiding a surgical procedure. Consequently, ductal stenting could be considered as a valuable alternative, especially in patients at risk of requiring a complementary source of pulmonary blood flow. In the future, one could imagine a tailored strategy of elective stenting of the duct at the time of pulmonary valvuloplasty in patients with bipartite right ventricle or small TVs and PVs.

With regard to mid-term outcome, the reintervention rate was high, with nearly one third of patients needing interventional catheterization and/or surgery during follow-up [7]. The nature and incidence of reinterventions were consistent with previous findings [7,19,20]. Significant PV regurgitation was observed in nearly 30% of cases. Pulmonary regurgitation is well tolerated for a long time, and PV replacement was not observed during the study period, but is to be expected in the future [27].

Study limitations

This was a retrospective study with the inherent limitations as a result of missing data or incomplete follow-up. Given the small number of patients, this study was underpowered to detect true differences between subgroups. Heterogeneity in follow-up duration limited analysis of predictive markers of events. There were no standardized patient selection criteria for the initial therapeutic approach. As the patients were cared for in a tertiary surgical centre, the local tendency to perform a BT shunt could represent bias. Finally, as explained above, ductal stenting has not been part of our management strategy, which excludes the opportunity to compare our data with other studies that employed the two techniques or to study the pros and cons of ductal stenting versus a BT shunt.

Conclusions

This large study confirms that neonates with DD-PS and PA-IVS and tripartite or bipartite ventricle will benefit from pulmonary valvulotomy as an initial treatment strategy. A large majority reach biventricular circulation despite notable initial mortality and the need for later reintervention. The procedure carries a higher risk in premature infants, neonates with PA-IVS and those with significant tricuspid regurgitation. TV and PV hypoplasia, as well as bipartite right ventricle, might be risk factors for early BT shunt or ductal stenting. Multicentre studies are needed to confirm the described risk factors for the need for supplementary pulmonary blood flow after pulmonary valvulotomy.

Sources of funding

The study was supported by réseau maladies rares M3C Marie-Lannelongue.

Disclosure of interest

The authors declare that they have no competing interest.

References

- [1] Feltes TF, Bacha E, Beekman 3rd RH, et al. Indications for cardiac catheterization and intervention in pediatric cardiac disease: a scientific statement from the American Heart Association. *Circulation* 2011;123:2607–52.
- [2] Schwartz MC, Glatz AC, Dori Y, Rome JJ, Gillespie MJ. Outcomes and predictors of reintervention in patients with pulmonary atresia and intact ventricular septum treated with radiofrequency perforation and balloon pulmonary valvuloplasty. *Pediatr Cardiol* 2014;35:22–9.
- [3] Cho MJ, Ban KH, Kim MJ, Park JA, Lee HD. Catheter-based treatment in patients with critical pulmonary stenosis or pulmonary atresia with intact ventricular septum: a single institute experience with comparison between patients with and without additional procedure for pulmonary flow. *Congenit Heart Dis* 2013;8:440–9.
- [4] Hasan BS, Bautista-Hernandez V, McElhinney DB, et al. Outcomes of transcatheter approach for initial treatment of

- pulmonary atresia with intact ventricular septum. *Catheter Cardiovasc Interv* 2013;81:111–8.
- [5] Giglia TM, Mandell VS, Connor AR, Mayer Jr JE, Lock JE. Diagnosis and management of right ventricle-dependent coronary circulation in pulmonary atresia with intact ventricular septum. *Circulation* 1992;86:1516–28.
- [6] Hascoët S, Combelles S, Acar P. Cardiac computed tomography of multiple coronary arteries to right ventricle fistulas in a newborn with pulmonary atresia and intact ventricular septum. *Can J Cardiol* 2014;30:247 e7-9.
- [7] Petit CJ, Glatz AC, Qureshi AM, et al. Outcomes after decompression of the right ventricle in infants with pulmonary atresia with intact ventricular septum are associated with degree of tricuspid regurgitation: results from the Congenital Catheterization Research Collaborative. *Circ Cardiovasc Interv* 2017;10:10.
- [8] Leung MP, Mok CK, Hui PW. Echocardiographic assessment of neonates with pulmonary atresia and intact ventricular septum. *J Am Coll Cardiol* 1988;12:719–25.
- [9] Cantinotti M, Scalese M, Murzi B, et al. Echocardiographic nomograms for chamber diameters and areas in Caucasian children. *J Am Soc Echocardiogr* 2014;27:1279-92 e2.
- [10] Humpl T, Soderberg B, McCrindle BW, et al. Percutaneous balloon valvotomy in pulmonary atresia with intact ventricular septum: impact on patient care. *Circulation* 2003;108:826–32.
- [11] Hirata Y, Chen JM, Quaegebeur JM, Hellenbrand WE, Mosca RS. Pulmonary atresia with intact ventricular septum: limitations of catheter-based intervention. *Ann Thorac Surg* 2007;84:574–9, discussion 9–80.
- [12] Alwi M. Management algorithm in pulmonary atresia with intact ventricular septum. *Catheter Cardiovasc Interv* 2006;67:679–86.
- [13] Alwi M, Geetha K, Bilkis AA, et al. Pulmonary atresia with intact ventricular septum percutaneous radiofrequency-assisted valvotomy and balloon dilation versus surgical valvotomy and Blalock Taussig shunt. *J Am Coll Cardiol* 2000;35:468–76.
- [14] Agnoletti G, Piechaud JF, Bonhoeffer P, et al. Perforation of the atretic pulmonary valve. Long-term follow-up. *J Am Coll Cardiol* 2003;41:1399–403.
- [15] Ovaert C, Qureshi SA, Rosenthal E, Baker EJ, Tynan M. Growth of the right ventricle after successful transcatheter pulmonary valvotomy in neonates and infants with pulmonary atresia and intact ventricular septum. *J Thorac Cardiovasc Surg* 1998;115:1055–62.
- [16] Qureshi SA, Rosenthal E, Tynan M, Anjos R, Baker EJ. Transcatheter laser-assisted balloon pulmonary valve dilation in pulmonary valve atresia. *Am J Cardiol* 1991;67:428–31.
- [17] Marasini M, Gorrieri PF, Tuo G, et al. Long-term results of catheter-based treatment of pulmonary atresia and intact ventricular septum. *Heart* 2009;95:1520–4.
- [18] Kim YH. Pulmonary valvotomy with echocardiographic guidance in neonates with pulmonary atresia and intact ventricular septum. *Catheter Cardiovasc Interv* 2015;85:E123–8.
- [19] Chubb H, Pesonen E, Sivasubramanian S, et al. Long-term outcome following catheter valvotomy for pulmonary atresia with intact ventricular septum. *J Am Coll Cardiol* 2012;59:1468–76.
- [20] Shaath G, Al Mutairi M, Tamimi O, Alakhfash A, Abolfotouh M, Alhabshan F. Predictors of reintervention in neonates with critical pulmonary stenosis or pulmonary atresia with intact ventricular septum. *Catheter Cardiovasc Interv* 2012;79:659–64.
- [21] Yucel IK, Bulut MO, Kucuk M, Balli S, Celebi A. Intervention in patients with critical pulmonary stenosis in the ductal stenting era. *Pediatr Cardiol* 2016;37:1037–45.
- [22] Mallula K, Vaughn G, El-Said H, Lamberti JJ, Moore JW. Comparison of ductal stenting versus surgical shunts for palliation of

- patients with pulmonary atresia and intact ventricular septum. *Catheter Cardiovasc Interv* 2015;85:1196–202.
- [23] Udink Ten Cate FE, Sreeram N, Hamza H, Agha H, Rosenthal E, Qureshi SA. Stenting the arterial duct in neonates and infants with congenital heart disease and duct-dependent pulmonary blood flow: a multicenter experience of an evolving therapy over 18 years. *Catheter Cardiovasc Interv* 2013;82: E233–43.
- [24] Hascoet S, Baruteau A, Jalal Z, et al. Stents in paediatric and adult congenital interventional cardiac catheterization. *Arch Cardiovasc Dis* 2014;107:462–75.
- [25] Hascoet S, Jalal Z, Baruteau A, et al. Stenting in paediatric and adult congenital heart diseases: a French multicentre study in the current era. *Arch Cardiovasc Dis* 2015;108:650–60.
- [26] Bentham JR, Zava NK, Harrison WJ, et al. Duct stenting versus modified blalock-taussig shunt in neonates with duct-dependent pulmonary blood flow: associations with clinical outcomes in a Multicenter National Study. *Circulation* 2018;137:581–8.
- [27] Hascoet S, Acar P, Boudjemline Y. Transcatheter pulmonary valvulation: current indications and available devices. *Arch Cardiovasc Dis* 2014;107:625–34.