



Available online at  
**ScienceDirect**  
www.sciencedirect.com

Elsevier Masson France  
**EM|consulte**  
www.em-consulte.com/en



CLINICAL RESEARCH

## Right ventricular outflow tract prestenosing with AndraStent XXL before percutaneous pulmonary valve implantation

*Utilisation du stent AndraStent XXL pour créer une zone de largage avant revalvulation pulmonaire percutanée*

Clement Karsenty<sup>a,b,\*</sup>, Sophie Malekzadeh-Milani<sup>c</sup>,  
Alain Fraisse<sup>d</sup>, Marc Gewillig<sup>e</sup>, Damien Bonnet<sup>c</sup>,  
Philippe Aldebert<sup>f</sup>, Caroline Ovaert<sup>f</sup>,  
Helene Bouvaist<sup>g</sup>, Aleksander Kempny<sup>h</sup>,  
Ali Houeijeh<sup>i</sup>, Jerome Petit<sup>i</sup>, Sebastien Hascoet<sup>i</sup>

<sup>a</sup> CHU Toulouse, Pediatric and Congenital Cardiology, Children's Hospital, Université de Toulouse, 31300 Toulouse, France

<sup>b</sup> Institut des Maladies Métaboliques et Cardiovasculaires, Université de Toulouse, INSERM U1048, I2MC, 1, Avenue Jean-Poulhès, BP 84225, Toulouse, France

<sup>c</sup> Centre de Référence Malformations Cardiaques Congénitales, Complexes-M3C, Necker Hospital for Sick Children, George-Pompidou European Hospital, Assistance Publique des Hôpitaux de Paris (AP-HP), 75015 Paris, France

<sup>d</sup> Paediatric Cardiology and Cardiac Surgery Services, Royal Brompton and Harefield NHS Foundation Trust, London, UK

<sup>e</sup> Fetal and Pediatric Cardiology, University Hospitals Leuven, Herestraat 49, 3000 Leuven, Belgium

<sup>f</sup> Pediatric and Congenital Cardiology, M3C Regional Reference CHD Centre, University Hospital, Marseille, France

<sup>g</sup> Department of Cardiology, M3C Regional Reference CHD Centre, CHU Grenoble, France

<sup>h</sup> Adult Congenital Heart Centre, Royal Brompton Hospital, London, UK

**Abbreviations:** BIB, balloon-in-balloon; NYHA, New York Heart Association; PPVI, percutaneous pulmonary valve implantation; RVOT, right ventricular outflow tract; SD, standard deviation; TGA, transposition of the great arteries; VSD, ventricular septal defect.

\* Corresponding author at: CHU Toulouse, Pediatric and Congenital Cardiology, Children's Hospital, Université de Toulouse, 31300 Toulouse, France.

E-mail address: [clement.karsenty@hotmail.fr](mailto:clement.karsenty@hotmail.fr) (C. Karsenty).

<https://doi.org/10.1016/j.acvd.2019.12.004>

1875-2136/© 2020 Elsevier Masson SAS. All rights reserved.

Please cite this article in press as: Karsenty C, et al. Right ventricular outflow tract prestenosing with AndraStent XXL before percutaneous pulmonary valve implantation. Arch Cardiovasc Dis (2020), <https://doi.org/10.1016/j.acvd.2019.12.004>

<sup>i</sup> *Pôle des cardiopathies congénitales de l'enfant et de l'adulte, centre de référence malformations cardiaques congénitales complexes (M3C), hôpital Marie-Lannelongue, université Paris-Sud, université Paris-Saclay, 133, avenue de la Résistance, 92350 Le Plessis-Robinson, France*

## KEYWORDS

Right ventricular outflow tract; Percutaneous pulmonary valve implantation; Stent

## Summary

**Background.** – The indications for percutaneous pulmonary valve implantation (PPVI) have been extended to include large dysfunctional right ventricular outflow tracts (RVOTs). Pre-stenting of the RVOT is commonly performed before PPVI in order to ensure a stable landing zone. The AndraStent XXL (AndraMed GmbH, Reutlingen, Germany), a cobalt-chromium stent with semi-open cell design, has unique mechanical properties in this indication but is no longer available in France.

**Aims.** – To assess the efficiency of AndraStent XXL before PPVI.

**Methods.** – In this retrospective multicentre cohort study, 86 AndraStents XXL were implanted in 77 patients in 6 centres.

**Results.** – PPVI was indicated mainly for pulmonary regurgitation (75.3%) in native or patched RVOT (88.3%). The stents were manually mounted on balloon catheters and delivered through sheaths using a conventional femoral approach. PPVI was performed successfully in 97.4% of patients after successful pre-stenting, generally during the same procedure (77.9%). There were no deaths associated with stent implantation, and four patients experienced five complications, mainly stent embolization, including one requiring surgery. Neither stent fracture nor dysfunction were observed in any patient during a mean follow-up of  $19.2 \pm 8.7$  months. Stent analysis showed an excellent maximal stent expansion (97.1%) regardless of balloon size. A  $22.3\% \pm 3.4$  stent shortening with a 30 mm balloon was observed.

**Conclusions.** – Implantation of large cobalt-chromium AndraStent XXL stents is efficient for pre-stenting before PPVI.

© 2020 Elsevier Masson SAS. All rights reserved.

## MOTS CLÉS

Voie de sortie ventriculaire droite ; Implantation percutanée de valve pulmonaire ; Endoprothèse

## Résumé

**Contexte.** – Les indications de revalvulation pulmonaire percutanée ont été étendues aux larges voies de sortie du ventricule droit. La revalvulation pulmonaire percutanée est généralement précédée d'un pre-stenting de la voie de sortie du ventricule droit afin d'assurer une zone de largage stable. L'AndraStent XXL (AndraMed GmbH, Reutlingen, Allemagne), une endoprothèse en cobalt et chrome à mailles semi-ouvertes, possède des propriétés mécaniques uniques dans cette indication mais n'est plus disponible en France.

**Objectifs.** – Évaluer l'efficacité de l'AndraStent XXL avant revalvulation pulmonaire percutanée.

**Méthodes.** – Dans cette étude de cohorte rétrospective multicentrique, 86 AndraStents XXL ont été implantés chez 77 patients dans 6 centres.

**Résultats.** – La fuite pulmonaire était l'indication principale de revalvulation (75,3 %) principalement dans des voies natives ou patchées (88,3 %). Les endoprothèses ont été serties manuellement sur des ballons et implantées à travers des gaines en utilisant une approche fémorale conventionnelle. La revalvulation a été réalisée avec succès chez 97,4 % des patients lorsque l'endoprothèse avait été implantée avec succès, généralement au cours de la même procédure (77,9 %). Aucun décès n'a été associé à l'implantation d'une endoprothèse et quatre patients ont présenté cinq complications, principalement une embolisation de l'endoprothèse, dont une nécessitant une intervention chirurgicale. Aucune fracture ni dysfonction de l'endoprothèse n'ont été observés chez aucun patient au cours d'un suivi moyen de  $19,2 \pm 8,7$  mois. L'analyse des endoprothèses a montré une excellente expansion maximale de l'endoprothèse (97,1 %) quelle que soit la taille du ballon. Serti sur un ballon de 30 mm, le raccourcissement de l'endoprothèse était en moyenne de  $22,3\% \pm 3,4$ .

*Conclusions.* – L'implantation d'une endoprothèse en chrome-cobalt AndraStent XXL est efficace pour créer une zone de largage avant reevaluation pulmonaire percutanée.  
© 2020 Elsevier Masson SAS. Tous droits réservés.

## Background

Percutaneous pulmonary valve implantation (PPVI) is evolving towards being a safe and effective treatment in patients who require valve replacement secondary to residual pulmonary regurgitation and/or stenosis [1]. Pre-stenting of the right ventricular outflow tract (RVOT) is commonly performed before PPVI in order to relieve a conduit obstruction [2], prevent valved stent fracture [3] and ensure a stable landing zone [4]. Off-label indications include native large RVOTs, which require anchoring of an extra-large stent to create a stable landing zone.

Attention has been focused on the development of new types of extra-large stents that involve high radial forces, flexibility and resistance to fracture, suitable for large RVOTs [5]. A new type of peripheral vascular stent has been available since 2008, which could offer some additional advantages over the previously available and most commonly implanted stents. The AndraStent XXL (AndraMed GmbH, Reutlingen, Germany) is a balloon-expandable, non-premounted, cobalt-chromium stent that is an extra-large stent. To our knowledge, there are a limited number of publications regarding its clinical application [6,7].

The aim of this study was to present a multicentre experience with the extra-large stent to create a landing zone for PPVI.

## Methods

### Patients

This retrospective study included all procedures of RVOT stenting with at least one AndraStent XXL. A retrospective review of the medical record charts was performed. Medical consent was obtained (CNIL, #1837880 v 0, February 26, 2015).

### Interventional procedure

All procedures were carried out under general anaesthesia following local protocols. Cardiac catheterization was performed from the femoral vein. The AndraStents were delivered through a prepositioned long sheath [5]. The stents were hand-crimped on balloons. The balloon was subsequently manually inflated to anchor the stent. Caution was taken to retrieve the balloon carefully as it may cause displacement or migration of the stent (Fig. 1).

The procedure-related complications were evaluated (Fig. 2). Depending on usual practice, PPVI was either

performed during the same procedure or was planned to occur in the next few months.

### Stent characteristics

The AndraStent XXL is a balloon-expandable, non-premounted, cobalt-chromium peripheral stent with a hybrid cell (semi-open) design. The AndraStent XXL is dilatable from 10 to 32 mm. The available stent lengths are 17, 21, 26, 30, 39, 43, 48 and 57 mm. In theory, the properties of the cobalt-chromium alloy in combination with the stent design should result in higher radial force, flexibility and good visibility on angiographic imaging, and easy anchoring in the vessel wall. Details of the physical behaviour of the stents are provided by the manufacturer on every stent cover. According to the manufacturer's information, the stent always shortens: for example, the AndraStent XXL 48 mm shortens to 36 mm when dilated to 28 mm.

We assessed the characteristics of 59 implanted stents, including minimum and maximum diameters (in profile or en face views) and shortening by measuring the final length on angiographic images (Fig. 3).

### Follow-up

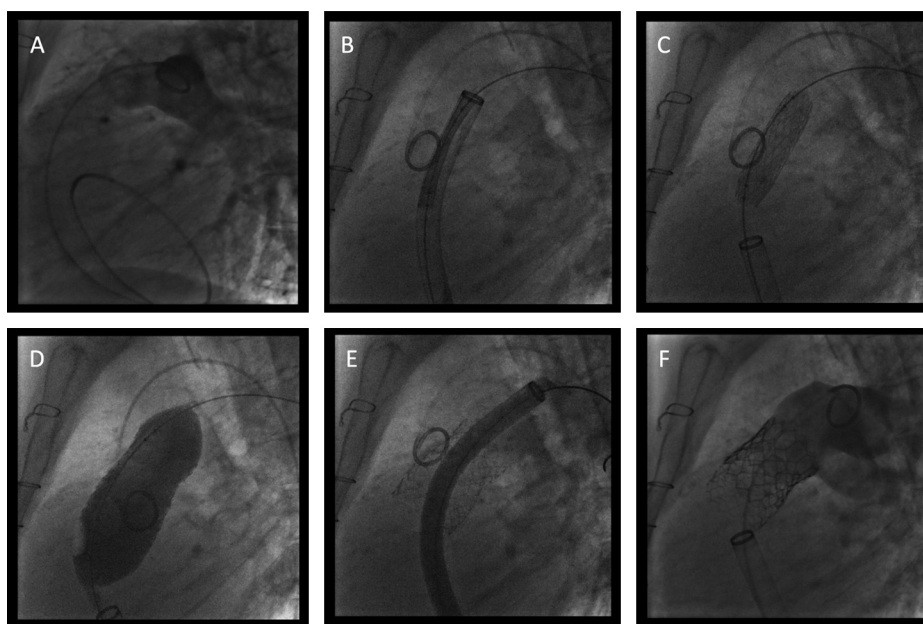
Patient follow-up was performed according to each institutional protocol (clinical examination, electrocardiography and echocardiography). All complications were recorded during follow-up.

### Statistical analysis

As this study was purely descriptive, standard descriptive statistics were used for the procedural and demographic data sets. Qualitative variables are expressed as numbers and percentages; quantitative variables are expressed as means  $\pm$  standard deviations (SDs) or medians (ranges) as appropriate.

## Results

From November 2016 to December 2018, 77 patients (39.0% female) underwent transcatheter implantation of 86 AndraStent XXL in six tertiary centres (Hôpital Marie-Lannelongue, Plessis-Robinson; Necker and Hôpital Européen Georges Pompidou, Paris; Royal Brompton, London; CHU Toulouse, Toulouse; CHU la Timone, Marseille; CHU Grenoble, Grenoble).



**Figure 1.** Details of a procedure of native RVOT stenting with AndraStent followed by PPVI in a 50-year-old woman with tetralogy of Fallot. A. Initial angiography to assess RVOT morphology. B. A 57 mm AndraStent was advanced (covered) through a long sheath. C. Inflation of the inner balloon of a 30 mm BIB balloon. D. Inflation of the outer balloon of a 30 mm BIB balloon. E. The stent was deployed and apposed in the RVOT to create the landing zone. F. A functional Sapien S3 (29 mm) was placed in the narrowest part of the stent. BIB: balloon-in-balloon; PPVI: percutaneous pulmonary valve implantation; RVOT: right ventricular outflow tract.

The patients were aged 7.6 to 59.8 years (median 30.1 years) and their weight ranged from 19 to 104 kg (median 61.5 kg) (Table 1). There were nine children/adolescents (< 18 years old) and 68 adults. Tetralogy of Fallot was the most common underlying heart disease (79.2%). PPVI was mainly indicated for pulmonary regurgitation (75.3%) in native or patched RVOT (88.3%).

## Procedure

Procedural characteristics are presented in Table 2. The sheaths used were 12–18-Fr Mullins sheaths (Cook Medical, Bloomington, IN, USA) or 26-Fr GORE® DrySeal Flex Introducer Sheaths (W.L. Gore & Associates, Inc., Flagstaff, AZ, USA) [8]. Successful stent implantation followed by PPVI was achieved in 75/77 patients (97.4%). Usually, only one stent was implanted (83.1%) and long stents were most commonly used (48 or 57 mm; 89.4%) (Table 2). The largest balloon-in-balloon (BIB) balloon (30 mm) (NuMED Canada, Inc. Cornwall, ON, Canada) was used for 58.8% of stents. Rarely, and depending on the centre, pacing was performed to implant the stent (5.8% of stents). PPVI was usually performed during the same procedure (77.9%), and mainly with an Edwards Sapien 3 (29 mm) valve (74.7%).

## Adverse events

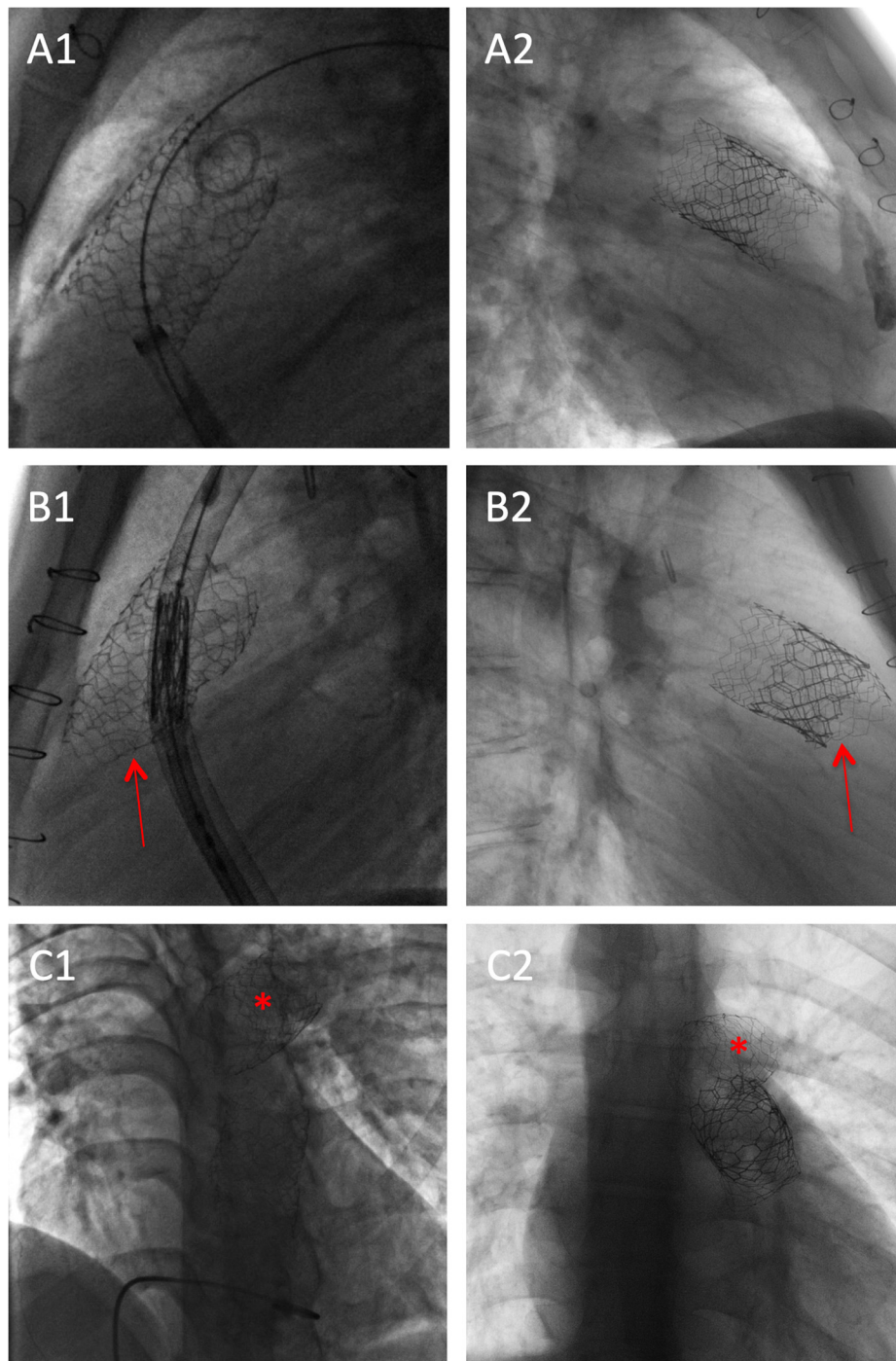
Five adverse events (6.5% of procedures) occurred in four patients (5.2% of patients) (Table 3). Surgical treatment was required for one event (1.3% of procedures). This patient had a large native RVOT and the stent migrated to the right ventricle. This required emergency surgery to retrieve the stent and implant a surgical valve, which was successful. One patient had a stent migration to the right pulmonary artery

and a right pulmonary vessel injury due to the guidewire, which required a vessel embolization with a plug. A longer AndraStent XXL (57 mm instead of 48 mm) mounted on larger BIB balloon (30 mm instead of 28 mm) was then successfully implanted. One patient had a stent migration into the left pulmonary artery without consequences. As for the previous patient, a longer and larger stent was successfully implanted in the RVOT. One patient had a stent migration to the distal main pulmonary artery, which required a double balloon technique to stabilize the stent at the pulmonary bifurcation. Nevertheless, the final diameter of the stent was too large (35 mm) to allow a PPVI and the patient was operated electively. Overall, no stent migrations occurred during the PPVI, whether carried out as a one- or two-step procedure. No local injuries were reported and no patients experienced a late complication.

## Stent analysis

All stent data are presented in Table 4. Out of 59 stents analysed, five (8.5%) were crushed at the basal part, which was noted during the procedure, but did not have any haemodynamic consequences. Three of them had balloon redilatation to expand the crushed part of the stent and no haemodynamic consequences were noted. To avoid crushing, the sheath was frequently advanced through the stent using the anchoring balloon technique, in which the balloon is inflated in the stent and used as an anchor to facilitate the sheath delivery position into the stent.

Foreshortening was consistent with published data from the company. The mean expanded length of a 57 mm AndraStent XXL using a 28 mm balloon was 45 mm, compared to a predicted length of 43 mm. Stent expansion was almost maximal (96.2–97.8%) regardless of the size of the balloon.



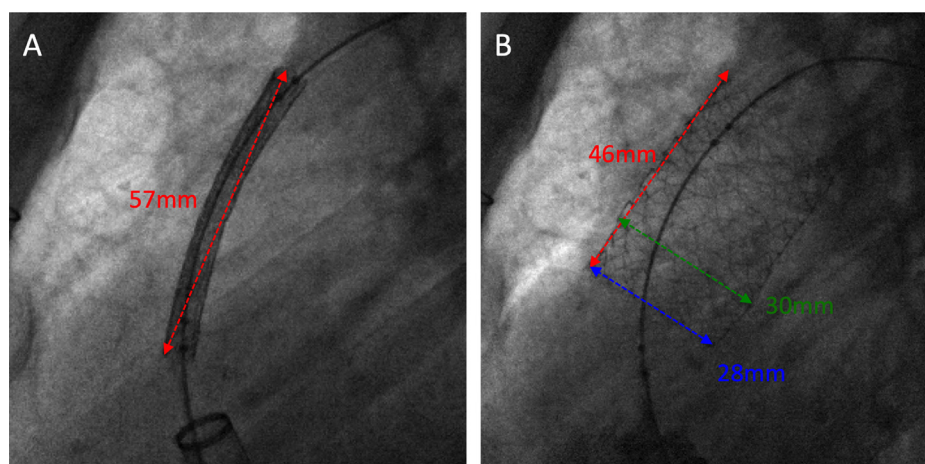
**Figure 2.** Stent analysis. A1. A 57 mm AndraStent XXL in profile view during catheterization. A2. Profile chest X-ray of the stent with a Sapien S3 (29 mm) inside. B1. Posterior crush of a 57 mm AndraStent XXL secondary to the sheath to implant the valve without haemodynamic consequences, in profile view during catheterization. B2. Profile chest X-ray of the crushed stent with a Sapien S3 (29 mm). The red arrows indicate the crushed zone. C1. Embolized 48 mm AndraStent XXL in the left pulmonary artery and a 57 mm AndraStent XXL in the pulmonary trunk in en face view during catheterization. C2. En face chest X-ray of the embolized 48 mm stent and Sapien S3 (29 mm) in the 57 mm stent. The red asterisks indicate the embolized stent.

Among 54 patients who had a systematic chest X-ray between 3 and 6 months after the procedure, no fractures were observed. Furthermore, during a mean follow-up of  $19.2 \pm 8.7$  months, no valvular dysfunction or rapid increase of valvular gradient was noted, reflecting the integrity of the stent.

## Discussion

Our data suggest that RVOT preenting with AndraStent XXL is effective to prepare the RVOT before PPVI.

Initially, PPVI was only performed and allowed in RVOT conduits. To bypass this limitation, a RVOT stent was



**Figure 3.** Characteristics of a 57 mm AndraStent XXL on a 30 mm BIB balloon. A. A 57 mm AndraStent XXL before deployment in the RVOT. B. Analysis of the deployed stent. Red arrows = shortening = final length of the stent; green arrows = maximal stent diameter; blue arrows = minimal stent diameter. BIB: balloon-in-balloon; RVOT: right ventricular outflow tract.

<b>Table 1</b> Patient characteristics.	
	All patients (n = 77)
Age (years)	30.1 (7.6–59.8)
Female sex	30 (39.0)
Weight (kg)	61.5 (19–104)
NYHA class	
I	54 (70.1)
II	21 (27.3)
III or IV	2 (2.6)
Congenital heart defect	
Tetralogy of Fallot	61 (79.2)
Pulmonary stenosis	5 (6.5)
Pulmonary atresia-VSD	4 (5.2)
Ross procedure	3 (3.9)
Pulmonary atresia with intact septum	2 (2.6)
TGA with VSD and pulmonary stenosis	1 (1.3)
Double outlet right ventricle	1 (1.3)
RVOT substitute	
Native or patched	68 (88.3)
Homograft	3 (3.9)
Surgical bioprosthesis	2 (2.6)
Surgical bioprosthetic conduit	2 (2.6)
Melody valve	2 (2.6)
Pulmonary valve replacement indication	
Regurgitation	58 (75.3)
Stenosis	3 (3.9)
Mixed	16 (20.8)

Data are expressed as median (range) or number (%). NYHA: New York Heart Association; RVOT: right ventricular outflow tract; TGA: transposition of the great arteries; VSD: ventricular septal defect.

implanted and acted as a conduit for the PPVI. Furthermore, when PPVI with a Melody valve was performed without pre-stenting, a high percentage of fractures were observed, which sometimes required a percutaneous pulmonary valve-in-valve for early device failure [9]. For the Melody valve, pre-stenting has been shown to reduce the incidence of valve/stent fracture from about 25–30% to around 5% [3]. When performing PPVI with the Sapien valve, pre-stenting is necessary to ensure a good landing zone for the valve, due to the short height of the Sapien valve. For all of these reasons, RVOT pre-stenting is currently recommended and widely used.

There are several stents on the market belonging to the group of large and extra-large stents, and each type has certain advantages and disadvantages. The previously popular Palmaz stent (Cordis, Johnson & Johnson, New Brunswick, NJ, USA) had many disadvantages. They were stiff and difficult to implant into tortuous RVOT. They also had sharp edges, which caused frequent balloon ruptures and significant stent foreshortening [10]. Cheatham platinum stents (CP™ Stent™; NuMED, Cornwall, Ontario, Canada) also belong to the group of large and extra-large stents and are most frequently used [11]. However, they have less radial strength than Palmaz stents. Their advantages include their rounded edges, which make them less prone to balloon rupture during stent implantation (similar to the AndraStents XXL). CP stent 8 Zig stents are dilatable up to 25 mm whereas AndraStent XXL are dilatable to 32 mm. This is a main disadvantage for the CP stent as native RVOTs are often larger than 23 mm. The same conclusion may be drawn for the Intrastent Max LD, ev3, 36 mm stent (Endovascular Inc., Plymouth, MN, USA). Indeed, in a recent study, nearly half the patients being pre-stented for Melody valve implantation did not undergo PPVI, mainly because of prohibitively large native RVOT sizes [12]. In our study, the AndraStent XXL performed well even when dilated to 30 mm. Foreshortening is less with the AndraStent XXL compared to the AndraStent XL because a 57 mm AndraStent XL shortened to 36 mm with a

**Table 2** Procedural characteristics.

	Procedures (n = 77)
Number of stents implanted (n = 86)	
1	69 (89.6)
2	7 (9.1)
3	1 (1.3)
Size of sheath (Fr)	
12	2 (2.6)
16	4 (5.2)
18	20 (26.0)
26	51 (66.2)
Valve implantation during same procedure	60 (77.9)
Success of valve implantation	75 (97.4)
Stent length (mm) (n = 86 stents)	
39	2 (2.3)
43	7 (8.1)
48	35 (40.7)
57	42 (48.8)
Type of balloon (n = 86 stents)	
BIB (Numed)	75 (87.2)
Crystal (Bard)	6 (7.0)
AltoSa XL PTA (AndraTec)	4 (4.7)
Andraballoon XL (AndraTec)	1 (1.2)
Diameter of balloon (mm) (n = 86 stents)	
22	2 (2.3)
24	5 (5.8)
26	8 (9.3)
28	21 (24.4)
30	50 (58.1)
Pacing for stent implantation	5 (5.8)
Type of valve (n = 75 valves)	
Sapien S3 29	56 (74.7)
Sapien S3 26	8 (10.7)
Sapien XT 29	7 (9.3)
Sapien S3 23	2 (2.7)
Melody	2 (2.7)

Data are expressed as number (%).

**Table 3** Procedural complications.

	Procedures (n = 77)
Total complications	5 (6.5)
Pulmonary artery stent embolization	3 (3.9)
Right ventricle embolization	1 (1.3)
Haemoptysis related to the guidewire	1 (1.3)

Data are expressed as number (%).

25 mm balloon whereas a 57 mm AndraStent XXL shortened to 44 mm with a 25 mm balloon, which is more appropriate for RVOT stenting.

Interestingly, a recent in vitro study has assessed the interaction between coronary and outflow tract stents

**Table 4** Stent deployment characteristics.

	Stent deployments (n = 59)
Stent shortening (%) <sup>a</sup>	
30 mm balloon	22.3 ± 3.4
28 mm balloon	19.9 ± 3.0
26 mm balloon	14.9 ± 2.8
Minimum stent diameter (%) <sup>b</sup>	
30 mm balloon	85.6 ± 15.4
28 mm balloon	89.9 ± 8.7
26 mm balloon	88.5 ± 5.4
Maximum stent diameter (%) <sup>c</sup>	
30 mm balloon	97.8 ± 4.4
28 mm balloon	97.4 ± 5.3
26 mm balloon	96.2 ± 4.2
Minor crush	5 (8.5)

Data are expressed as mean ± standard deviation or number (%).

<sup>a</sup> Stent shortening: ratio of basal stent length to deployed stent length.

<sup>b</sup> Minimum stent diameter: ratio of balloon diameter to minimum diameter of deployed stent.

<sup>c</sup> Maximum stent diameter: ratio of balloon diameter to maximal diameter of deployed stent.

(AndraStents, CP stents, Edwards SAPIEN XT valve stents). The Edwards SAPIEN XT valve stent had the greater relative radial force, as demonstrated by the greater relative decrease in diameter of the coronary stent at final compressive amplitude, whereas the AndraStent had the smallest radial force [13].

Four patients in our study had stent migration, including one that required surgical retrieval. Stent migration and early embolization are the most frequent complications, occurring in 7.7% of all stent implantations in congenital heart disease in various positions [14]. We also noted five minor crushes, which are typical of open-cell stents. None of these had haemodynamic consequences, but three were redilated. Cools et al. [15] reported similar results in conduit-free surgery of the RVOT in a small population of 23 patients. They reported one stent migration requiring surgery, two mild stent dislocations and four stent crumplings during PPVI. However, these patients had smaller RVOTs (the largest BIB balloon was 25 mm) [15].

Recently, some alternatives to pre-stenting have been proposed, to avoid dislodgment of the freshly implanted stent or a two-part procedure. Firstly, Boudjemline published a one-step procedure using the Melody valve [16]. In this procedure, the Melody valve is covered by a stent (EV3 LD max 36 mm stent, Covidien) on the table, thus allowing simultaneous implantation of the Melody valve and the stent [16]. Secondly, in a recent multicentre study, the SAPIEN valve has been used for PPVI without the use of a pre-stent [17]. At medium-term follow-up, no frame fracture, paravalvular leak, or migration was seen [17]. Indeed, unlike the Melody valve, stent fractures with the SAPIEN valve have not been reported, but a 'landing zone' is useful. In the future, new devices – such as RVOT reducers – may be alternatives [18].

Surgery remains off limits as an alternative in the absence of an available adequately sized extra-large stent.

## Limitations

This was a retrospective analysis of a relatively small number of patients and only a short to midterm follow-up. To confirm the good results presented here, a larger group of patients with longer follow-up is needed. Complications such as balloon rupture, haematoma and arrhythmia without severe consequences are likely not to have been properly documented. Another important point is that AndraStents are not registered in the USA and are therefore only available in Europe.

## Conclusions

Implantation of the AndraStent XXL provides a valid anchoring support for a subsequent PPVI. They are dilatable up to extra-large sizes (up to 32 mm for XXL stents) and so are adequate for large native RVOTs.

## Disclosure of interest

The authors declare that they have no competing interest.

## References

- [1] Hascoet S, Acar P, Boudjemline Y. Transcatheter pulmonary valvulation: current indications and available devices. *Arch Cardiovasc Dis* 2014;107:625–34.
- [2] Aggarwal S, Garekar S, Forbes TJ, Turner DR. Is stent placement effective for palliation of right ventricle to pulmonary artery conduit stenosis? *J Am Coll Cardiol* 2007;49:480–4.
- [3] McElhinney DB, Cheatham JP, Jones TK, Lock JE, Vincent JA, Zahn EM, et al. Stent fracture, valve dysfunction, and right ventricular outflow tract reintervention after transcatheter pulmonary valve implantation: patient-related and procedural risk factors in the US Melody Valve Trial. *Circ Cardiovasc Interv* 2011;4:602–14.
- [4] Malekzadeh-Milani S, Ladouceur M, Cohen S, Iserin L, Boudjemline Y. Results of transcatheter pulmonary valvulation in native or patched right ventricular outflow tracts. *Arch Cardiovasc Dis* 2014;107:592–8.
- [5] Hascoet S, Baruteau A, Jalal Z, Mauri L, Acar P, Elbaz M, et al. Stents in paediatric and adult congenital interventional cardiac catheterization. *Arch Cardiovasc Dis* 2014;107:462–75.
- [6] Venczelova Z, Tittel P, Masura J. First experience with AndraStent XL implantation in children and adolescents with congenital heart diseases. *Catheter Cardiovasc Interv* 2013;81:103–10.
- [7] Fiszser R, Bialkowski J, Chodor B, Pawlak S, Szkutnik M. Use of the AndraStent XL and XXL for the treatment of coarctation of the aorta in children and adults: immediate and midterm results. *EuroIntervention* 2016;12:394–9.
- [8] Hascoet S, Karsenty C, Tortigue M, Watkins AC, Riou JY, Boet A, et al. A modified procedure for percutaneous pulmonary valve implantation of the Edwards SAPIEN 3 valve. *EuroIntervention* 2019;14:1386–8.
- [9] Nordmeyer J, Coats L, Lurz P, Lee TY, Derrick G, Rees P, et al. Percutaneous pulmonary valve-in-valve implantation: a successful treatment concept for early device failure. *Eur Heart J* 2008;29:810–5.
- [10] Kreutzer J, Rome JJ. Open-cell design stents in congenital heart disease: a comparison of IntraStent vs. Palmaz stents. *Catheter Cardiovasc Interv* 2002;56:400–9.
- [11] Hascoet S, Jalal Z, Baruteau A, Mauri L, Chalard A, Bouzguenda I, et al. Stenting in paediatric and adult congenital heart diseases: a French multicentre study in the current era. *Arch Cardiovasc Dis* 2015;108:650–60.
- [12] Martin MH, Meadows J, McElhinney DB, Goldstein BH, Bergersen L, Qureshi AM, et al. Safety and feasibility of melody transcatheter pulmonary valve replacement in the native right ventricular outflow tract: a Multicenter Pediatric Heart Network Scholar Study. *JACC Cardiovasc Interv* 2018;11:1642–50.
- [13] Zablah JE, Fry R, Ross M, Wilson N, Morgan G. Using in vitro model to assess stent-stent interaction in patients with coronary artery compression. *J Interv Cardiol* 2018;31:870–7.
- [14] van Gameren M, Witsenburg M, Takkenberg JJ, Boshoff D, Mertens L, van Oort AM, et al. Early complications of stenting in patients with congenital heart disease: a multicentre study. *Eur Heart J* 2006;27:2709–15.
- [15] Cools B, Brown SC, Heying R, Jansen K, Boshoff DE, Budts W, et al. Percutaneous pulmonary valve implantation for free pulmonary regurgitation following conduit-free surgery of the right ventricular outflow tract. *Int J Cardiol* 2015;186:129–35.
- [16] Boudjemline Y. A new one-step procedure for pulmonary valve implantation of the melody valve: simultaneous pre-stenting and valve implantation. *Catheter Cardiovasc Interv* 2018;91:64–70.
- [17] Morgan GJ, Sadeghi S, Salem MM, Wilson N, Kay J, Rothman A, et al. SAPIEN valve for percutaneous transcatheter pulmonary valve replacement without ‘‘pre-stenting’’: a multi-institutional experience. *Catheter Cardiovasc Interv* 2019;93:324–9.
- [18] Jalal Z, Thambo JB, Boudjemline Y. The future of transcatheter pulmonary valvulation. *Arch Cardiovasc Dis* 2014;107:635–42.