


RESEARCH

Open Access



Acute myocarditis and multisystem inflammatory emerging disease following SARS-CoV-2 infection in critically ill children

Marion Grimaud¹, Julie Starck², Michael Levy³, Clémence Marais⁴, Judith Chareyre¹, Diala Khraiche⁵, Marianne Leruez-Ville⁶, Pierre Quartier⁷, Pierre Louis Léger⁸, Guillaume Geslain³, Nada Semaan⁴, Florence Moulin¹, Matthieu Bendavid¹, Sandrine Jean², Géraldine Poncelet³, Sylvain Renolleau⁹ and Mehdi Oualha^{9*} 

Abstract

Background: A recent increase in children admitted with hypotensive shock and fever in the context of the COVID-19 outbreak requires an urgent characterization and assessment of the involvement of SARS-CoV-2 infection. This is a case series performed at 4 academic tertiary care centers in Paris of all the children admitted to the pediatric intensive care unit (PICU) with shock, fever and suspected SARS-CoV-2 infection between April 15th and April 27th, 2020.

Results: 20 critically ill children admitted for shock had an acute myocarditis (left ventricular ejection fraction, 35% (25–55); troponin, 269 ng/mL (31–4607)), and arterial hypotension with mainly vasoplegic clinical presentation. The first symptoms before PICU admission were intense abdominal pain and fever for 6 days (1–10). All children had highly elevated C-reactive protein (> 94 mg/L) and procalcitonin (> 1.6 ng/mL) without microbial cause. At least one feature of Kawasaki disease was found in all children (fever, $n = 20$, skin rash, $n = 10$; conjunctivitis, $n = 6$; cheilitis, $n = 5$; adenitis, $n = 2$), but none had the typical form. SARS-CoV-2 PCR and serology were positive for 10 and 15 children, respectively. One child had both negative SARS-CoV-2 PCR and serology, but had a typical SARS-CoV-2 chest tomography scan. All children but one needed an inotropic/vasoactive drug support (epinephrine, $n = 12$; milrinone, $n = 10$; dobutamine, $n = 6$, norepinephrine, $n = 4$) and 8 were intubated. All children received intravenous immunoglobulin (2 g per kilogram) with adjuvant corticosteroids ($n = 2$), IL 1 receptor antagonist ($n = 1$) or a monoclonal antibody against IL-6 receptor ($n = 1$). All children survived and were afebrile with a full left ventricular function recovery at PICU discharge.

Conclusions: Acute myocarditis with intense systemic inflammation and atypical Kawasaki disease is an emerging severe pediatric disease following SARS-CoV-2 infection. Early recognition of this disease is needed and referral to an expert center is recommended. A delayed and inappropriate host immunological response is suspected. While underlying mechanisms remain unclear, further investigations are required to target an optimal treatment.

Keywords: Shock, Children, Acute myocarditis, Multisystem inflammatory syndrome, SARS-CoV-2

*Correspondence: mehdi.oualha@aphp.fr

⁹ Pediatric Intensive Care Unit, Necker-Enfants-Malades University Hospital, Assistance Publique-Hôpitaux de Paris, Paris University, EA7323, 75006 Paris, France

Full list of author information is available at the end of the article

Introduction

In contrast to adults, severe pediatric cases of the 2019 novel coronavirus (SARS-CoV-2) infections are known to be rare [1, 2]. From the beginning of the European

epidemic and until mid-April, most of the critically ill children with SARS-CoV-2 infection presented with respiratory failure and high proportion of co-morbidities [3]. Unexpectedly, within the last 2 weeks, we observed an outbreak of shock cases with high systemic inflammation and myocarditis, suspected to be associated with SARS-CoV-2 infection in four pediatric intensive care units (PICU) in the Paris region. Simultaneously, both UK and French health authorities have alerted pediatricians about an unusual number of children admitted to a PICU with mixed shock and Kawasaki disease. Acute heart failure and myocarditis associated with SARS-CoV-2 has not been reported in children yet, although previously described in adults [4–7]. Here, we aim to describe the characteristics, management and time course of 20 critically ill children admitted to the PICU with cardiogenic shock secondary to acute myocarditis and suspected SARS-CoV-2 infection.

Methods

This study is a retrospective, observational study performed at 4 academic tertiary care centers in Paris. It was conducted according to the local ethics committee and oral informed consent was obtained from the parents of the children studied. All patients aged less than 18 and admitted to the PICU with shock, fever and a suspected SARS-CoV-2 infection between April 15th and April 27th, 2020 were included in the study population.

Acute myocarditis was defined with the following criteria: elevated troponin, ST segment elevation or depression on electrocardiogram, regional wall motion abnormalities with decreased left ventricular function on echocardiography [8]. Shock was defined as tachycardia and one of the following signs: arterial systemic hypotension, cold extremity, decrease peripheral pulse, capillary refill time > 3 s, oliguria or arterial blood lactate > 2 mmol/L [9]. In addition to usual laboratory investigations, chest X-rays, transthoracic echocardiography, electrocardiogram, troponin, brain natriuretic peptide and lactate measurements were performed. Standard microbiological screening was performed. Usual etiologies of acute myocarditis were systematically screened including the testing of a large panel of non-SARS-CoV-2 viruses in blood, feces and nasopharyngeal swabs. SARS-CoV-2 was diagnosed using polymerase chain reaction (PCR) on nasopharyngeal swabs and/or feces (Emag, BioMérieux™, Marcy-l'Étoile, France; SARS-CoV-2 R-Gene, BioMérieux™). SARS-CoV-2 antibodies (IgG and IgA) were measured using a commercial ELISA assay (anti-SARS-CoV-2 IgA and IgG, EuroImmun™, Bussy-Saint-Martin, France).

Data were extracted from the electronic medical records and de-identified. Descriptive statistics were

obtained for all study variables. Continuous data were expressed as median and range values. Categorical data were expressed as proportions (%) Additional file 1: Table S1.

Results

All the children were hypotensive and presented with a major systemic inflammation and an acute myocarditis. The demographic data, clinical, biological and echocardiographic features of the 20 children are summarized in Table 1. Details of each case are provided in Table S1. No co-morbidity was identified, and no history of previous SARS-CoV-2 symptomatic infection was reported. First, all presented severe abdominal pain, vomiting and fever. The length of the PICU stay for the 15 children already discharged was 4 days (1–8). In addition to acute myocardial systolic dysfunction, all children were hypotensive and 15 showed clinical signs of vasoplegia (warm extremity and immediate capillary refill time). The criteria mentioned before for the myocarditis definition were observed in all patients. Pericardial effusion was observed in 4 children. Coronary arteries were not dilated at this early stage. All children but one received an inotropic support for a median duration of 3 days (1–7). No patient required veno-arterial extracorporeal membrane oxygenation. None of the children had a primary respiratory failure. Invasive mechanical ventilation ($n=8$) lasted 5 days (1–7). 14 children had transient acute renal failure with no need for renal replacement therapy. None of the patients had sufficient criteria for typical Kawasaki disease, but all had a prolonged fever and half of them a skin rash. Neither bacterial nor non-SARS-CoV-2 viral infections were identified. All children received intravenous immunoglobulin (2 g per kilogram) within the first 2 days of their PICU stay and 18 were thereafter afebrile. Two patients received corticosteroids and two others IL1 receptor antagonist ($n=1$) or a monoclonal antibody against IL-6 receptor ($n=1$). All children survived at this stage of the disease and were discharged from the PICU with full left ventricular systolic function recovery and a substantial decrease of inflammatory biomarkers (Fig. 1). SARS-CoV-2 was positive on nasopharyngeal swabs and feces in 10 and 2 children, respectively. SARS-CoV-2 antibodies were positive for all the patients screened at this stage ($n=15$). Nineteen of the 20 included patients had identified SARS-CoV-2 infection on PCR and/or by serology. The remaining patient had negative SARS-CoV-2 PCR and serology, but his chest computed tomography scan was typical of SARS-CoV-2 infection.

Table 1 Clinical, biological and hemodynamic characteristics

	Value
Age, years median (range)	10 (2.9–15)
Sex, no. (%)	
Male	10 (50)
Female	10 (50)
Admission delay from first symptoms, days, median (range)	6 (1–10)
PELOD-2 score at admission, median (range)	10 (10–22)
Clinical description	
Fever, no. (%)	20 (100)
Abdominal pain, no. (%)	20 (100)
Skin rash, no. (%)	10 (50)
Conjunctivitis, no. (%)	6 (30)
Cheilitis, no. (%)	5 (25)
Adenitis (diameter > 1.5 cm), no. (%)	2 (10)
Glasgow Coma Scale, median (range)	15 (4–15)
Hemodynamic features	
Tachycardia, no. (%)	20 (100)
Systemic arterial hypotension, no. (%)	20 (100)
Left ventricular ejection fraction, median (range), %	35 (25–55)
Laboratory values, median (range) ^a	
Troponin, ng/mL	269 (31–4607)
Brain natriuretic peptide, pmol/L ^a	3405 (179–19013)
Lactate, mmol/L	3.6 (1–8,1)
Creatinine clearance, mL/min/1,73 m ²	97 (16–170)
Albumin, g/L	21 (17–26)
Sodium, mmol/L	131 (122–139)
Alanine aminotransferase, IU/L	27 (6–163)
Platelets count, per mm ³	210,000 (93,000–403,000)
Neutrophil count, per mm ³	10955 (1500–34200)
Lymphocyte count, per mm ³	1150 (380–7200)
C-reactive protein, mg/L	251 (94–458)
Procalcitonin, ng/mL ^b	46 (1,6–448)
Fibrinogen, g/L ^c	7,2 (3,9–9)
Inotropes and vasoactive drugs, no. (%)	
Epinephrine, no. (%)	12 (60)
Median (range), µg/kg/min	0.13 (0,1–0.5)
Milrinone, no. (%)	10 (50)
Median (range), µg/kg/min	0.45 (0.3–0.6)
Dobutamine, no. (%)	6 (30)
Median (range), µg/kg/min	7.5 (5–15)
Norepinephrine, no. (%)	4 (20)
Median (range), µg/kg/min	0.55 (0,2–1.2)
Mechanical ventilation	
Non-invasive ventilation, no. (%)	11 (55)
Invasive ventilation, no. (%)	8 (40)
High-flow nasal oxygen, no. (%)	1 (5)

^a Available for 15 patients^b Available for 16 patients^c Available for 19 patients^d Highest dosing during the PICU stay^e Worst values within the first 24 h of PICU stay

PELOD-2 Pediatric Logistic Organ Dysfunction 2 score

Discussion

We describe here the first case series of acute myocarditis and major systemic inflammation following SARS-CoV-2 infection in 20 critically ill children. Very similar clinical and biological presentations, echocardiographic features and time course were observed.

Given the results of SARS-CoV-2 screening antibodies, the association of such a presentation and a SARS-CoV-2 infection is highly likely. The phenotype of our patients differs from those infected by SARS-CoV-2 and previously reported in literature: they are older, have no co-morbidity nor any respiratory failure [1, 2]. The time of occurrence of this emerging disease (delayed by 4 weeks after the beginning of the French lockdown) and the remarkably high rate of IgG and IgA identification strongly suggest a post-viral immunological reaction impacting the myocardium [10]. Besides, the dramatic cardiac function improvement as well as the significant decrease of inflammatory biomarkers following intravenous immunoglobulin reinforces the hypothesis of a SARS-CoV-2 post-infective disease.

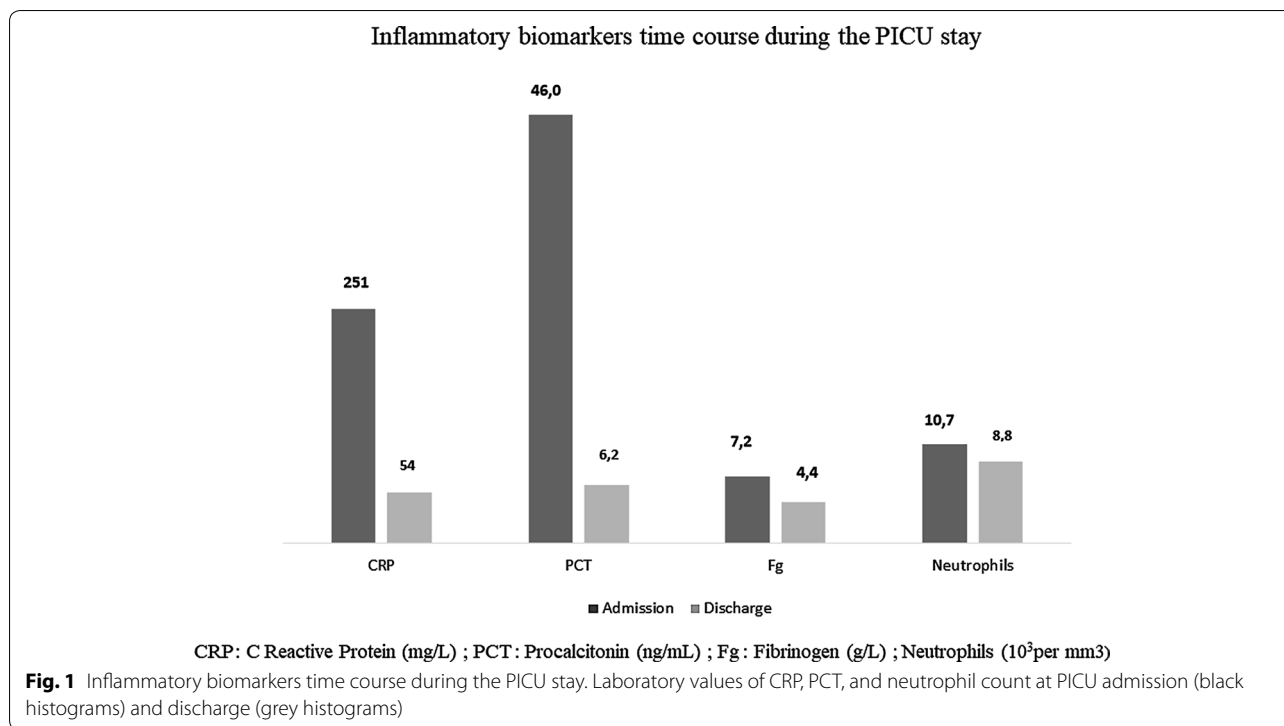
In this series, COVID-19 acute myocarditis are less severe than those usually seen in children and are characterized by some unusual and noteworthy findings: intense systemic inflammation, some features usually seen in Kawasaki disease and vasoplegia [8]. The underlying mechanism of heart damage remains unclear as none of the patients had an endomyocardial biopsy.

The prolonged fever, along with high systemic inflammation, vasoplegia, myocardial involvement and some features of Kawasaki disease (atypical form) underlie a possible new spectrum of vasculitis and inflammatory diseases following SARS-CoV-2 infection rather than direct viral organ damage as previously reported in adults [11, 12]. Children with atypical Kawasaki disease, even with acute myocarditis, are known to be younger [13]. Also, in the Kawasaki disease shock syndrome acute myocarditis occurs in only 30% of the cases; platelets count, C-reactive protein and neutrophil count are lower [14, 15] than what we observe in our population.

Regarding the clinical aspects of Kawasaki disease, even atypical and the current early stage of the description of this new disease, we suggest a close follow-up of cardiac recovery and repeated ultrasound scan to detect the potential occurrence of coronary artery dilation.

Conclusions

In children, the severe multisystem inflammatory emerging disease following SARS-CoV-2 infection highlights the variability and the large spectrum in host response to this novel virus and suggests that it may be one of the



upcoming and unknown clinical post-infective complications of SARS-CoV-2 infection.

Supplementary information

Supplementary information accompanies this paper at <https://doi.org/10.1186/s13613-020-00690-8>.

Additional file 1. Cases description, Table S1.

Abbreviations

COVID-19: Coronavirus disease 2019; CRP: C-reactive protein; PCR: Polymerase chain reaction; PCT: Procalcitonin; PICU: Pediatric intensive care unit; SARS-CoV-2: Severe acute respiratory syndrome-coronavirus-2.

Acknowledgements

We acknowledge (i) all the PICU teams including nurses for their devotion to take care of these vulnerable patients; (ii) Elie Caroline and Philippe Tourenne for their help in obtaining ethics approval; and (iii) François Angoulvant and Julie Toubiana.

Authors' contributions

MD and MO had full access to all the data in the study and take responsibility for the integrity of the data and the accuracy of the data analysis. Concept and design: MG, SR, FM, PLL and MO. Acquisition, analysis, or interpretation of data: MG, JS, ML, PQ and MO. Drafting of the manuscript: MO. Critical revision of the manuscript for important intellectual content: All authors. Administrative, technical, or material support: MB, JC, ML. Supervision: MO, SR and PLL. All authors read and approved the final manuscript.

Funding

No.

Availability of data and materials

Individual details of cases were provided in supplementary material.

Ethics approval and consent to participate

The local committee of Necker hospital approved the study.

Competing interests

No.

Consent for publication

Not applicable.

Author details

¹ Pediatric Intensive Care Unit, Necker-Enfants-Malades University Hospital, Assistance Publique-Hôpitaux de Paris, Paris, France. ² Pediatric and Neonatal Intensive Care Unit, Armand-Trousseau University Hospital, Assistance Publique-Hôpitaux de Paris, Paris, France. ³ Pediatric Intensive Care Unit, Robert Debré University Hospital, Assistance Publique-Hôpitaux de Paris, Université de Paris, Paris, France. ⁴ Pediatric and Neonatal Intensive Care Unit, Kremlin-Bicêtre University Hospital, Assistance Publique-Hôpitaux de Paris, Paris, France. ⁵ M3C-Necker, Congenital and Pediatric Cardiology, Necker-Enfants-Malades University Hospital, Assistance Publique-Hôpitaux de Paris, Paris, France. ⁶ Laboratoire de Virologie, Paris University, EA 7328, Paris, France. ⁷ Paediatric Hematology-Immunology and Rheumatology Unit, Reference center for Rheumatic, Autoimmune and Systemic diseases in children (RAISE), Necker-Enfants Malades University Hospital, Assistance Publique-Hôpitaux de Paris, IMAGINE Institute, Université de Paris, Paris, France. ⁸ Pediatric and Neonatal Intensive Care unit, Armand-Trousseau University Hospital, Assistance Publique-Hôpitaux de Paris, Sorbonne University, Paris, France. ⁹ Pediatric Intensive Care Unit, Necker-Enfants-Malades University Hospital, Assistance Publique-Hôpitaux de Paris, Paris University, EA7323, 75006 Paris, France.

Received: 7 May 2020 Accepted: 25 May 2020

Published online: 01 June 2020

References

- Lu X, Zhang L, Du H, Zhang J, Li YY, Qu J, et al. SARS-CoV-2 infection in children. *N Engl J Med*. 2020;382:1663–5.

2. Tagarro A, Epalza C, Santos M, Sanz-Santaefemia FJ, Otheo E, Moraleda C, et al. Screening and severity of coronavirus disease 2019 (COVID-19) in Children in Madrid, Spain. *JAMA Pediatr.* 2020. <https://jamanetwork.com/journals/jamapediatrics/fullarticle/2764394> Accessed 12 Apr 2020.
3. Castagnoli R, Votto M, Licari A, Brambilla I, Bruno R, Perlini S, et al. Severe Acute Respiratory Syndrome Coronavirus 2 (SARS-CoV-2) Infection in Children and Adolescents: A Systematic Review. *JAMA Pediatr.* 2020;.
4. Inciardi RM, Lupi L, Zaccone G, Italia L, Raffo M, Tomasoni D, et al. Cardiac Involvement in a Patient With Coronavirus Disease 2019 (COVID-19). *JAMA Cardiol.* 2020. <https://jamanetwork.com/journals/jamacardiology/fullarticle/2763843> Accessed 7 May 2020.
5. Madjid M, Safavi-Naeini P, Solomon SD, Vardeny O. Potential Effects of Coronaviruses on the Cardiovascular System: A Review. *JAMA Cardiol.* 2020. <https://jamanetwork.com/journals/jamacardiology/fullarticle/2763846> Accessed 7 May 2020.
6. Shi S, Qin M, Shen B, Cai Y, Liu T, Yang F, et al. Association of Cardiac Injury With Mortality in Hospitalized Patients With COVID-19 in Wuhan, China. *JAMA Cardiol.* 2020. <https://jamanetwork.com/journals/jamacardiology/fullarticle/2763524> Accessed 7 May 2020.
7. Liu PP, Blet A, Smyth D, Li H. The science underlying COVID-19: implications for the cardiovascular system. *Circulation.* 2020. <https://doi.org/10.1161/CIRCULATIONAHA.120.047549>.
8. Myocarditis in the pediatric population: A review - Dasgupta - 2019 - Congenital Heart Disease - Wiley Online Library. <https://onlinelibrary.wiley.com/doi/full/10.1111/chd.12835> Accessed 7 May 2020.
9. Weiss SL, Peters MJ, Alhazzani W, Agus MSD, Flori HR, Inwald DP, et al. Surviving sepsis campaign international guidelines for the management of septic shock and sepsis-associated organ dysfunction in children. *Intensive Care Med.* 2020;46:10–67.
10. Zhu H, Rhee J-W, Cheng P, Waliyany S, Chang A, Witteles RM, et al. Cardiovascular complications in patients with COVID-19: consequences of viral toxicities and host immune response. *Curr Cardiol Rep.* 2020;22:32.
11. Leisman DE, Deutschman CS, Legrand M. Facing COVID-19 in the ICU: vascular dysfunction, thrombosis, and dysregulated inflammation. *Intensive Care Med.* 2020;1:1–4.
12. Tomelleri A, Sartorelli S, Campochiaro C, Baldissera EM, Dagna L. Impact of COVID-19 pandemic on patients with large-vessel vasculitis in Italy: a monocentric survey. *Ann Rheum Dis.* 2020.
13. McCrindle BW, Rowley AH, Newburger JW, Burns JC, Bolger AF, Gewitz M, et al. Diagnosis, treatment, and long-term management of Kawasaki disease: a scientific statement for health professionals from the American heart association. *Circulation.* 2017;135:e927–99.
14. Kanegaye JT, Wilder MS, Molkara D, Frazer JR, Pancheri J, Tremoulet AH, et al. Recognition of a Kawasaki disease shock syndrome. *Pediatrics.* 2009;123:e783–9.
15. Gatterre P, Oualha M, Dupic L, Iserin F, Bodemer C, Lesage F, et al. Kawasaki disease: an unexpected etiology of shock and multiple organ dysfunction syndrome. *Intensive Care Med.* 2012;38:872–8.

Publisher's Note

Springer Nature remains neutral with regard to jurisdictional claims in published maps and institutional affiliations.

Submit your manuscript to a SpringerOpen[®] journal and benefit from:

- Convenient online submission
- Rigorous peer review
- Open access: articles freely available online
- High visibility within the field
- Retaining the copyright to your article

Submit your next manuscript at ► [springeropen.com](https://www.springeropen.com)
