

## 4D flow cardiac magnetic resonance in children and adults with congenital heart disease: Clinical experience in a high volume center

Marc-Antoine Isorni<sup>a,\*</sup>, Louis Moisson<sup>a</sup>, Nidal Ben Moussa<sup>b</sup>, Sébastien Monnot<sup>a</sup>, Francesca Raimondi<sup>c</sup>, Régine Roussin<sup>b</sup>, Angèle Boet<sup>b</sup>, Isabelle van Aerschot<sup>b</sup>, Emmanuelle Fournier<sup>b</sup>, Sarah Cohen<sup>b</sup>, Meriem Kara<sup>b</sup>, Sébastien Hascoet<sup>b</sup>

<sup>a</sup> Diagnostic and Therapeutic Radiology Service, Hôpital Marie Lannelongue, 133, avenue de la résistance, 92350 Le Plessis Robinson, France

<sup>b</sup> Pôle des cardiopathies congénitales de l'enfant et de l'adulte, Centre de référence malformations cardiaques congénitales complexes (M3C), hôpital Marie-Lannelongue, université Paris-Sud, université Paris-Saclay, 133, avenue de la Résistance, 92350 Le Plessis-Robinson, France

<sup>c</sup> Pediatric Radiology Unit, Hôpital universitaire Necker Enfants-Malades, 149, rue de Sevres, 75743 Paris, Cedex 15, France

### ARTICLE INFO

#### Article history:

Received 6 April 2020

Received in revised form 29 May 2020

Accepted 13 July 2020

Available online 24 July 2020

### ABSTRACT

**Background:** Cardiac magnetic resonance (CMR) imaging with velocity encoding along all three directions of flow, known as 4DFlow CMR, provides both anatomical and functional information. Few data are available on the usefulness of 4DFlow CMR in everyday practice. Here, our objective was to investigate the usefulness of 4DFlow CMR for assessing congenital heart disease (CHD) in everyday practice.

**Methods:** From 2017 to 2019, consecutive patients who underwent 4DFlow CMR were included prospectively at a single high-volume centre. The parameters recommended by an expert's consensus statement for each diagnosis (congenital valvulopathy, septal defect, complex CHD, tetralogy of Fallot, aortic abnormalities) were assessed by two blinded experienced readers. 4DFlow CMRs that provided all recommended parameters were considered successful. Inter-observer and intra-observer agreement were investigated.

**Results:** We included 187 adults and 60 children covering broad ranges of weight (4.5–142 kg) and age (0.1–67 years). 4DFlow CMR was always the second-line imaging modality, after inconclusive echocardiography, and was successful in 231/247 (91%) patients, with no significant difference between children and adults (54/60, 90%; and 177/187, 95%; respectively;  $p = .13$ ). Longer time using 4DFlow CMR at our centre was associated with success; in children, older age was also associated with exam success. There was an about 12-month learning curve in children. The success rate was lowest in neonates. Inter-observer and intra-observer agreement were substantial.

**Conclusion:** Our results suggest that 4DFlow CMR usually provides a comprehensive assessment of CHD in adults and children. A learning curve exists for children and the investigation remains challenging in neonates.

© 2020 Elsevier B.V. All rights reserved.

### 1. Background

Four-dimensional flow cardiac magnetic resonance (4DFlow CMR) is a recently introduced imaging technique that investigates cardiovascular flow in a whole heart acquisition. It provides both quantitative and qualitative data on flow patterns in the heart and great vessels [1–4]. Research studies in a broad spectrum of abnormalities suggest a role as a second-line imaging technique, notably in congenital heart disease (CHD), in which conventional imaging techniques may not be sufficient [5–10]. In patient with CHDs, 4DFlow CMR has been investigated to

assess valvulopathy [7,8,11,12], complex CHDs [13–16], aortic coarctation [17–19], tetralogy of Fallot [20], and septal defects [9,21,22]). However, complexity of post processing is seen as a limit to its feasibility and its widespread use in routine clinical practice. Little is known about the diagnostic contribution of 4DFlow CMR outside the research setting.

The objective of this prospective observational cohort study was to assess the information provided by 4DFlow CMR in children and adults with CHD, as part of the everyday practice in a tertiary congenital cardiology centre. We sought to assess whether the benefits of 4DFlow CMR suggested by research studies were confirmed in clinical practice.

### 2. Methods

#### 2.1. Study population

From January 2017 to September 2019, all consecutive patients with CHD who underwent cardiac magnetic resonance including a 4D flow

\* Corresponding author.

E-mail addresses: [marco.isorni@gmail.com](mailto:marco.isorni@gmail.com) (M.-A. Isorni), [lmoisson@hml.fr](mailto:lmoisson@hml.fr) (L. Moisson), [nbenmoussa@hml.fr](mailto:nbenmoussa@hml.fr) (N.B. Moussa), [smonnot@hml.fr](mailto:smonnot@hml.fr) (S. Monnot), [a.boet@hml.fr](mailto:a.boet@hml.fr) (A. Boet), [i.vanaerschot@hml.fr](mailto:i.vanaerschot@hml.fr) (I. van Aerschot), [e.fournier@hml.fr](mailto:e.fournier@hml.fr) (E. Fournier), [s.cohen@hml.fr](mailto:s.cohen@hml.fr) (S. Cohen), [m.kara@hml.fr](mailto:m.kara@hml.fr) (M. Kara), [s.hascoet@hml.fr](mailto:s.hascoet@hml.fr) (S. Hascoet).

acquisition at Marie Lannelongue hospital, expert centre for the management of complex congenital heart diseases (M3C network) were enrolled prospectively. The study was approved by local ethic committee, which waived the need for informed consent in compliance with French law on retrospective studies of anonymized data and was conducted in compliance with the Declaration of Helsinki. All procedures were part of standard care. Written informed consent was obtained from each participant, and from the parents of minors, before inclusion into the study.

CMR exams were indicated by cardiologists and surgeons for the regular management of patients' CHD. No exam was performed for the sole purpose of the study. All CMR exams were performed as a second-line imaging modality in complement of at least an echocardiography.

4DFlow CMR acquisition and post-processing CMR were performed in spontaneously breathing patient. In smaller children a light sedation was administered before the acquisitions, using hydroxyzine (2.5–3.5 mg/kg). If needed during the acquisitions, additional sedation was provided using etomidate (0.1–0.2 mg/kg) Fratz et al. [23].

The 4DFlow CMR data were acquired after an injection of a gadolinium-based contrast agent (Gadovist, Bayer, Mijdrecht, The Netherlands), using a 1.5-T machine (Discovery MR450, GE Healthcare, Milwaukee, WI). Retrospective electrocardiographic gating was used. In-plane spatial resolution was 2.1·2.4 mm, with 2.1-mm slice thickness, interpolated to 1.4-mm using zero filling interpolation (ZIP) of 2. Velocity encoding (VENC) was set between 250 cm/s and 400 cm/s depending on the diagnosis. The 4DFlow CMR data were uploaded to a cloud-based software application (Arterys Inc., San Francisco, CA, USA) and transformed into DICOM data.

## 2.2. Data collection

Diagnosis were classified as follows: valvulopathy, septal defect, complex CHD, tetralogy of Fallot, or aortic coarctation (Table 1)

**Table 1**  
Baseline characteristics in children (a) and adults (b).

a.		
n = 60	Moy	Min - Max
Weight (kg)	40.3 ± 25.6	4.5–121
Height (cm)	134.7 ± 38.6	57–186
Age (year)	11.5 ± 5.8	0.1–180
Duration (s)	443 ± 73.8	319–610
Experience with 4D Flow CMR (month)	18.0 ± 8.1	10.0–25.0
Disease:		
Valvulopathy (n,%)	7 (12)	
Septal defect (n,%)	4 (6)	
Complex CHD (n,%)	14 (23)	
ToF (n,%)	28 (47)	
Aorta disease (n,%)	7 (12)	
First-line imaging modality	0 (0)	
Second-line imaging modality	60 (100)	
b.		
n = 60	Moy	Min - Max
Weight (kg)	66.7 ± 18.2	35–142
Height (cm)	166.1 ± 9.9	138–195
Age (year)	41.1 ± 16.6	18.4–67.2
Duration (s)	463.5 ± 87.8	334–601
Experience with 4D Flow CMR (month)	20.0 ± 8.4	3.0–32.
Disease:		
Valvulopathy (n,%)	27 (15)	
Septal defect (n,%)	28 (15)	
Complex CHD (n,%)	34 (18)	
ToF (n,%)	92 (49)	
Aorta disease (n,%)	6 (3)	
First-line imaging modality	0 (0)	
Second-line imaging modality	187 (100)	

Dyverfeldt et al. [10]. For each diagnosis, Some dedicated 4DFlow CMR parameters are recommended. Dyverfeldt et al. [10]. These parameters were assessed by two experienced readers who were blinded to all patient data (Table 1); MAI and LM (6- and 3-years' experience with congenital heart disease imaging, respectively). Disagreements were resolved requesting an independent reading by an expert from a second institution; FR).

Baseline characteristics were collected. Duration of experience with 4DFlow CMR was recorded as the time from the introduction of 4DFlow CMR at our centre (date ...) to the date of 4DFlow CMR exam in a given patient.

4DFlow CMR was considered successful if all the recommended parameters were reliably assessed. When the values failed to agree with the law of conservation of mass, were non-reproducible (difference in values >10% over 3 consecutive measurements), or could not be reliably assessed due to the presence of artefacts, the investigation was considered to be unsuccessful [10].

## 2.3. Statistical analysis

Distribution normality was checked using the Shapiro-Wilk test. Continuous data were described as mean ± SD and categorical data as n (%). The chi-square test was applied to binary response variables to estimate the probability of 4DFlow CMR being successful. A logistic regression model was built to identify variables independently associated with successful 4DFlow CMR. According to our results, univariate analyses were done first. Second, significant variables were included into the multivariate model. Values of *p* lower than .05 were considered significant.

To assess graphically the impact of duration of operator experience on rate of successful exam, cumulative frequency graphs were plotted.

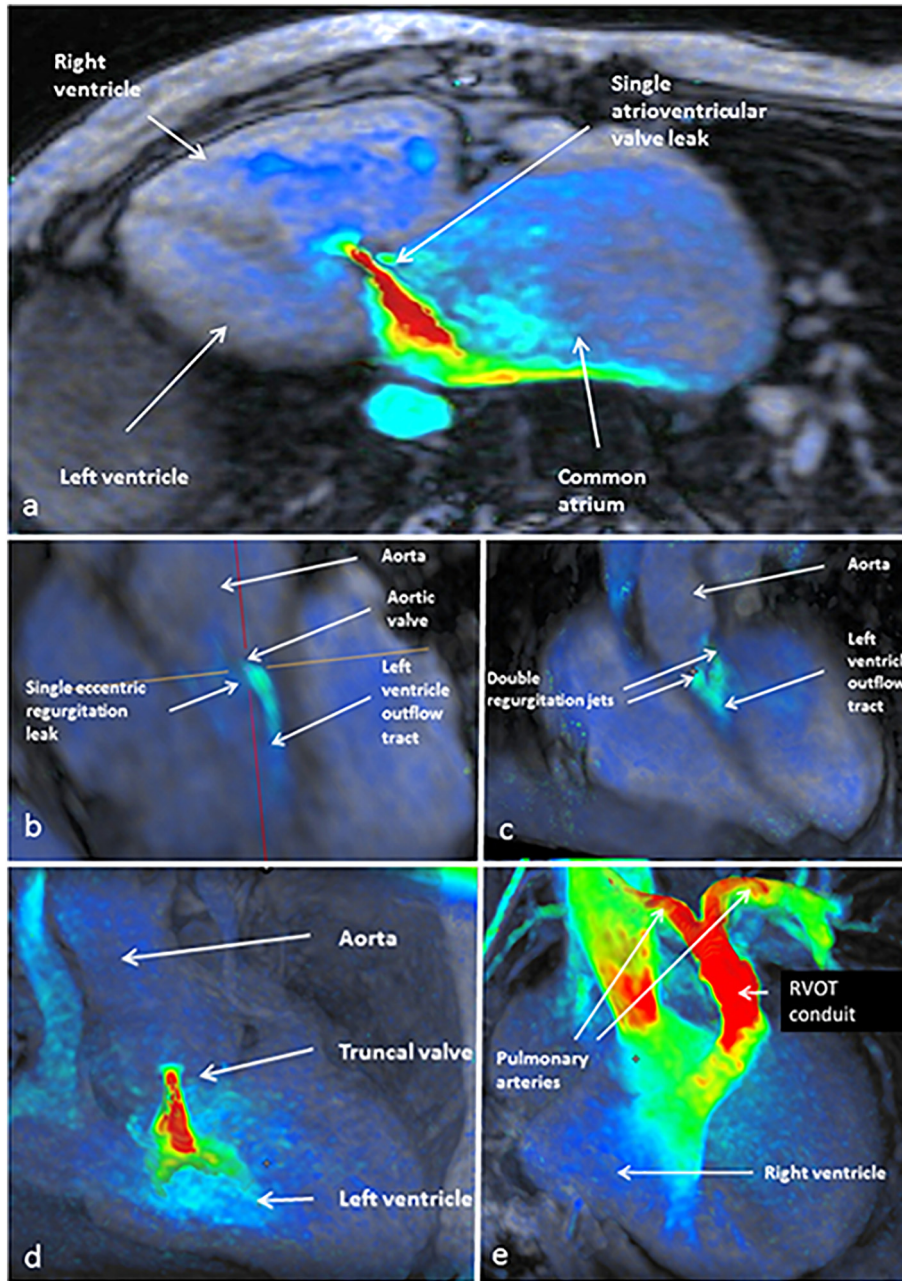
Intra-observer and inter-observer agreement was assessed by applying Bowker's test and by computing Cohen's kappa [24]. Based on the multivariate analysis, cumulative frequency graphs of independent variables were created to assess their distribution [25]. All statistical analyses were performed using JMP 9.1 software (SAS Institute Inc., Cary, NC, USA).

## 3. Results

Of the 501 patients who underwent 4DFlow CMR at our centre during the study period, 247 had CHD, including 60 children and 187 adults (Table 1). Seven exams (11.7% of children exams) were performed in infants under 12 months-old. All children under 6 years of age benefited from light sedation, in accordance with our protocol (n = 12). Beyond 6 years, this sedation was occasional (n = 7). All 4DFlow CMR acquisitions were technically successful. All exams offered sufficient image quality for post-processing analysis.

In the valvulopathy group (Fig. 1), 7 children and 27 adults underwent 4DFlow CMR a. All exams were carried out in order to complete echocardiography failure due to eccentric or multiple jets, as for atrioventricular valve, bicuspid aortic valve or truncus valve. It provided a detailed qualitative description of the flow and quantified its hemodynamic. In the septal defect group (Fig. 2), 4 children and 28 adults underwent 4DFlow CMR. It confirmed the echocardiography findings, whereas it estimated right heart dilatation, Qp/Qs ratio and made it possible to assess any associated structural anomalies, such for sinus venosus atrial septal defect. In the complex heart disease group, 14 children and 34 adults underwent 4DFlow CMR (Fig. 3). All exams completed first-line echocardiography assessment, providing anatomical details, as stenosis or pulmonary sequestration in Scimitar syndrome, or functional evaluation on cardiac structures not accessible to ultrasound such as the superior cavo-pulmonary anastomosis in patients Fontan palliation or as the fenestration in cor triatriatum sinister.

In the tetralogy of Fallot group (Fig. 4), 28 children and 92 adults underwent 4DFlow CMR. It provided anatomical details on the



**Fig. 1.** Valvulopathy. a. 34-year-old patient with an unbalanced complete atrioventricular septal defect palliated by total cavo-pulmonary connection. Echocardiography failed to provide a reliable assessment of atrioventricular valve regurgitation given its eccentricity. 4DFlow CMR showed a single eccentric leak which was quantified as massive (regurgitation fraction =, 41%). b, c. 21-year-old patient with residual aortic valve regurgitation after surgical valvuloplasty. The aortic valve is bicuspid aortic valve with an eccentric commissural leak and double regurgitation jets. Its severity was difficult to quantify by echo. 4DFlow CMR provided a detailed description of the regurgitation and quantified its severity (regurgitation fraction, 25%). d, e. 21-year-old patient with corrected tricusus arteriosus. The severity of the truncus valve regurgitation was not satisfactorily assessed by echocardiography. The anatomical analysis of 4DFlow CMR data indicated aortic root dilatation, and the functional images showed moderate flow acceleration (2.2 m/s) in the right ventricle-to-pulmonary artery conduit with a moderate leak through the truncus valve (regurgitation fraction, <20%).

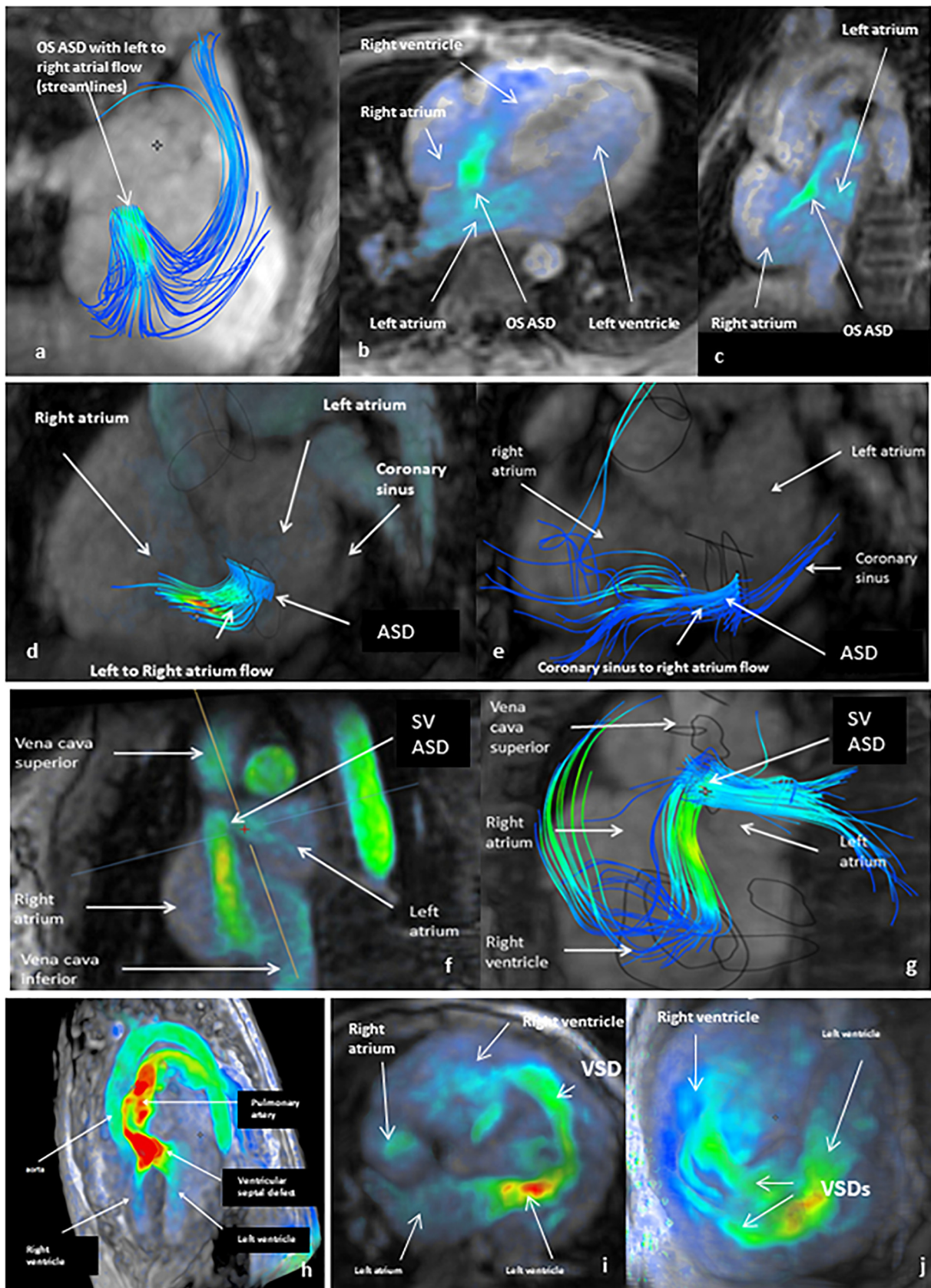
pulmonary artery (lengths, diameters and areas) and functional information such as right ventricle volumes and function or main pulmonary artery hemodynamic. In the aortic abnormalities group (Fig. 5), 7 children and 6 adults underwent 4D Flow CMR. The first indication was the confirmation of the existence of an anomaly or not, particularly in adults ( $n = 4$ ), to confirm the diagnosis (aorta kinking or coarctation), then to establish anatomical characteristics as well as their hemodynamic repercussions.

4DFlow CMR were rated successful in 231 (94%) patients. Successful exam rate was not significantly different among children and adults ( $n = 54$ ; 90%; and  $n = 177$ ; 95%; respectively;  $p = .13$ ). Of the 7 exams performed in infants, 4 were successful (57%). Motion or breathing

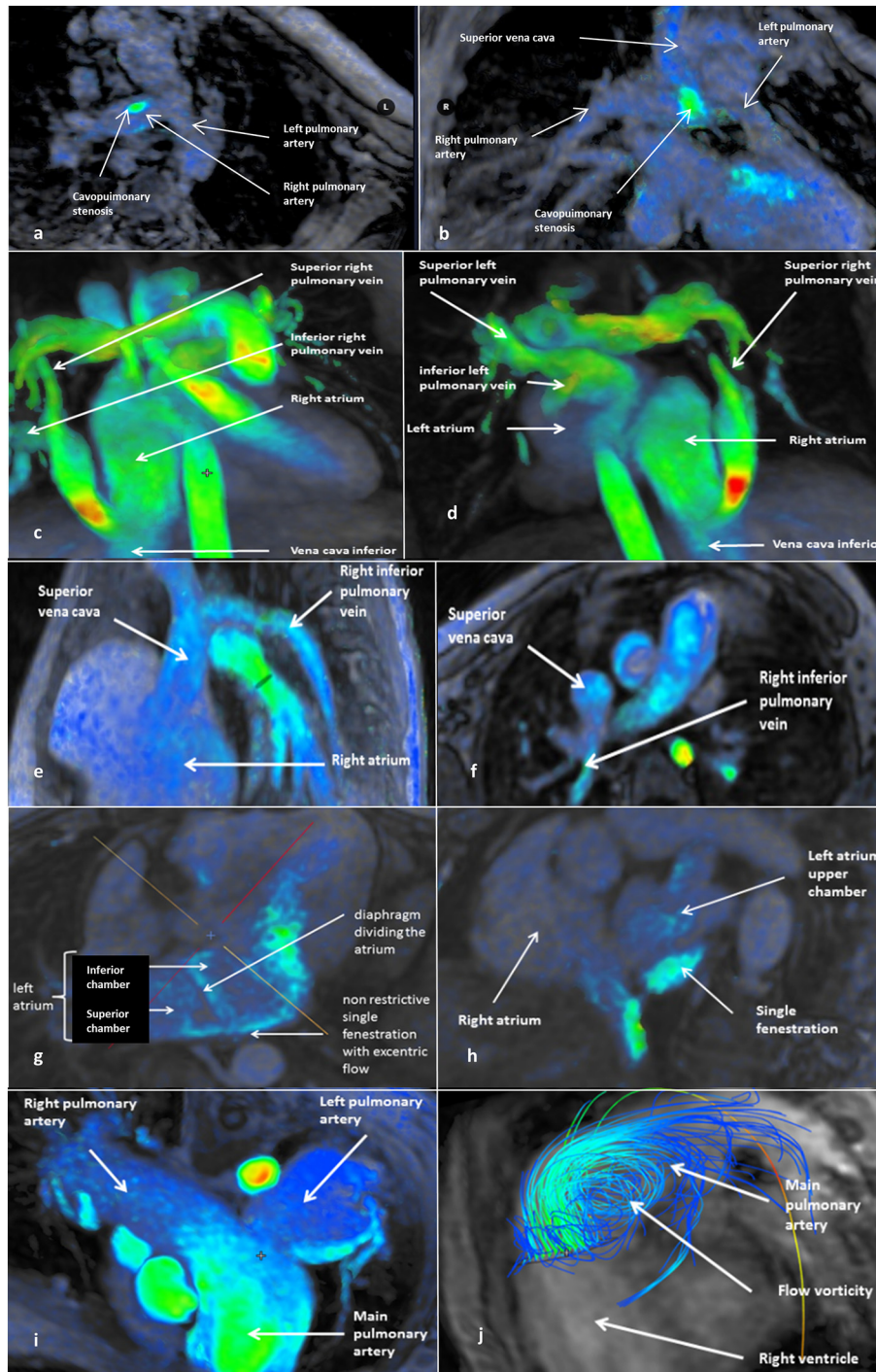
artefacts were responsible for ghosting and blurring in the 16 unsuccessful 4DFlow CMRs, despite the use of respiratory motion compensation and respiratory navigators. None of the 247 4DFlow CMRs exhibited aliasing artefacts.

Duration of exam was similar in children and adults and was not associated with the success rate in either age group ( $443.0 \text{ s} \pm 73.8$ ,  $p = .9$  and  $463.5 \text{ s} \pm 87.8$ ,  $p = .9$ , respectively).

In adults (Table 2), operator's experience in 4DFlow CMR was the only variable associated with a successful 4DFlow CMR. In children, logistic regression multivariate regression identified both duration of operator's experience and age as independent variable associated with having a successful 4DFlow CMR.



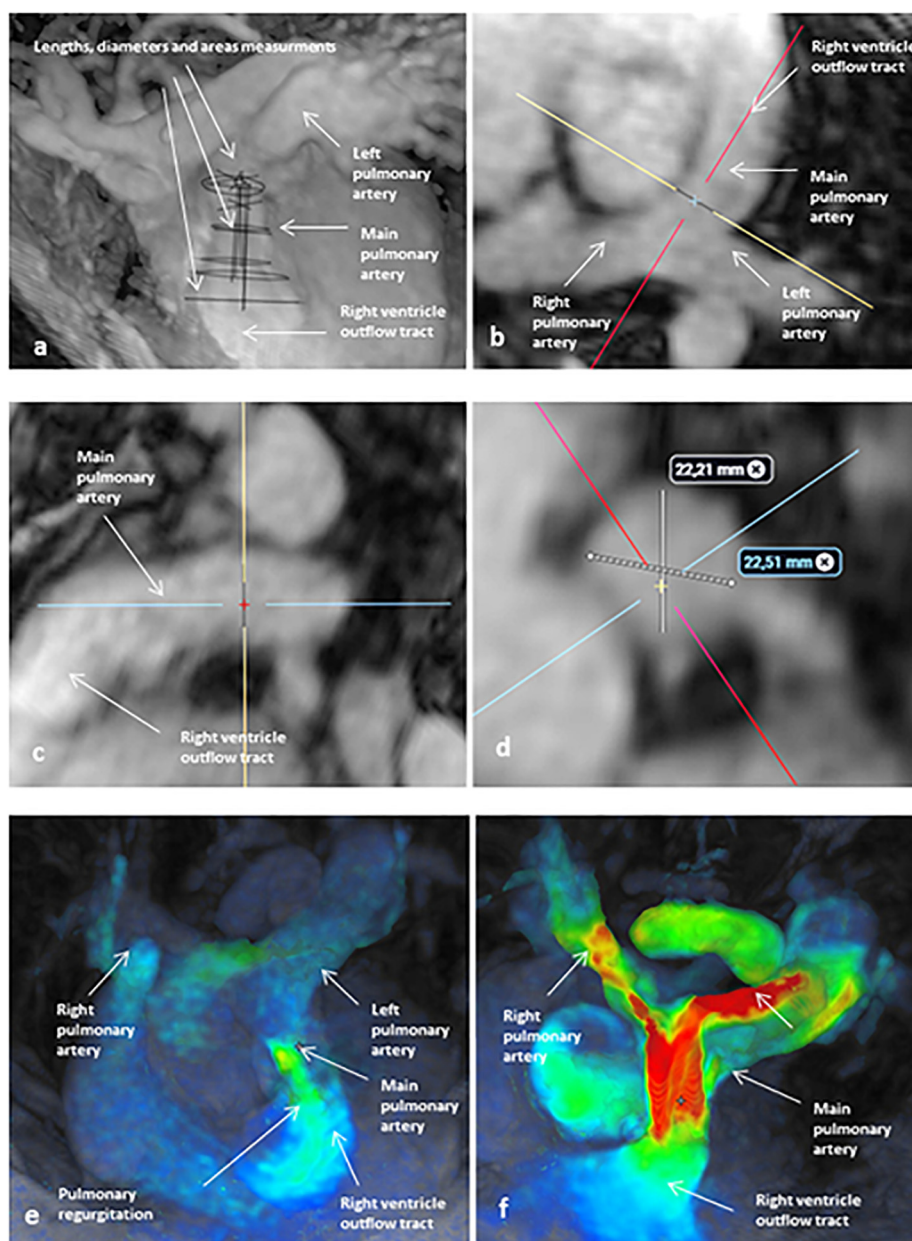
**Fig. 2.** Septal defect. a, b, c. 11-year-old child with a small ostium secundum atrial septal defect. 4DFlow CMR confirmed the echocardiography findings, showing a limited impact of the shunt with no meaningful increase in the  $Q_p/Q_s$  ratio ( $Q_p/Q_s = 1.2$ ) or right heart dilatation ( $RVESV = 48 \text{ mL/m}^2$ ). These findings supported therapeutic abstention. d, e. Unroofed coronary sinus atrial septal defect in a 42-year-old patient. 4DFlow CMR shown both interatrial flow and flow from the coronary sinus to the right atrium. The estimated  $Q_p/Q_s$  ratio was 1.7, RVEF was 48%, and  $RVESV$  was  $96 \text{ mL/m}^2$ . f, g. Sinus venosus atrial septal defect in an 8-year-old. 4DFlow CMR provided both anatomical and functional information, showing a defect size of 6 by 8 mm and an estimated  $Q_p/Q_s$  of 1.6. h. 2.6-year-old child with a double outlet right ventricle ((S,D,D)), balanced ventricles, and an anterior aorta. 4DFlow CMR showed a sub-pulmonary stenosis and qualitative flow analysis through the VSD allow to plan surgical intra-ventricular repair. With accelerated flow. i, j. 0.4-year-old with multiple trabecular ventricular septal defects. 4DFlow CMR visualized a large VSD and two additional small muscular VSDs without any other intracardiac shunts. Right and left ventricular systolic functions were assessed. Flow measurements showed a large shunt with a  $Q_p/Q_s$  ratio of 2.5.



**Fig. 3.** Complex congenital heart disease. a, b. Univentricular heart in a 12-year-old child palliated with the Fontan procedure. 4DFlow CMR showed a stenosis of the superior cavopulmonary anastomosis with a mean gradient of 4 mmHg, which was confirmed by cardiac catheterization. c, d. Scimitar syndrome in a 37-year-old woman. 4DFlow CMR provided anatomical details on the anomalous pulmonary venous return with connection of the right lung to the inferior vena cava. There was no stenosis or pulmonary sequestration. The functional evaluation showed moderate flow acceleration at the connection ( $V_{max} = 0.9$  m/s). e, f. Partial pulmonary venous return in a 14-year-old child. The right inferior pulmonary veins drain into the right atrium, leading to right heart dilatation ( $RVEDV = 101$  mL/m<sup>2</sup>) without systolic right ventricular dysfunction. 4DFlow CMR ruled out other abnormalities and estimated the  $Q_p/Q_s$  ratio at 1.3. g, h. Cor triatriatum sinister in a 52-year-old patient. 4DFlow imaging showed a single transverse diaphragm with a single non-restrictive fenestration and no flow acceleration ( $V_{max} = 0.7$  m/s). No other congenital heart defects were found. i, j. Atrial septal defect complicated with pulmonary hypertension in a 23-year-old woman. 4DFlow CMR showed dilation of the pulmonary arteries with main pulmonary artery ectasia (largest diameter, 55 mm) and flow vorticity. The functional assessment confirmed the moderate right ventricular dilatation ( $RVEDV = 98$  mL/m<sup>2</sup>) with good systolic function.

Cumulative frequency graph for adults showed a uniform distribution of unsuccessful 4DFlow CMRs along duration of operator's experience. It can approximately be considered to be a straight line except for a very slight increase between 17 and 24 months (Fig. 6). This

graphical analysis suggest that rate of unsuccessful exams remains quite stable along duration of operator's experience. Thus, it confirms the limited impact of duration of operator experience on exams success rate in adults. In contrast, in children, the distribution of unsuccessful



**Fig. 4.** Tetralogy of Fallot. a, b, c, d. 24-year-old with repaired tetralogy of Fallot. 4DFlow CMR provided anatomical details on the pulmonary artery (lengths, diameters and areas) and functional information. The pulmonary regurgitation was massive (RF = 43%), causing dilation of the right ventricle (RVEDV = 120 mL/m<sup>2</sup>; RVESV = 70 mL/m<sup>2</sup>) with preserved systolic right ventricular function (RVEF = 42%). These findings supported treatment by percutaneous pulmonary valve implantation. e, f. 13-year-old with repaired tetralogy of Fallot. 4DFlow CMR showed moderate pulmonary regurgitation (RF = 31%) with no stenosis on the main pulmonary artery or side branches (Vmax = 1.8 m/s) and no meaningful dilation of the right ventricle (RVEDV = 88 mL/m<sup>2</sup>).

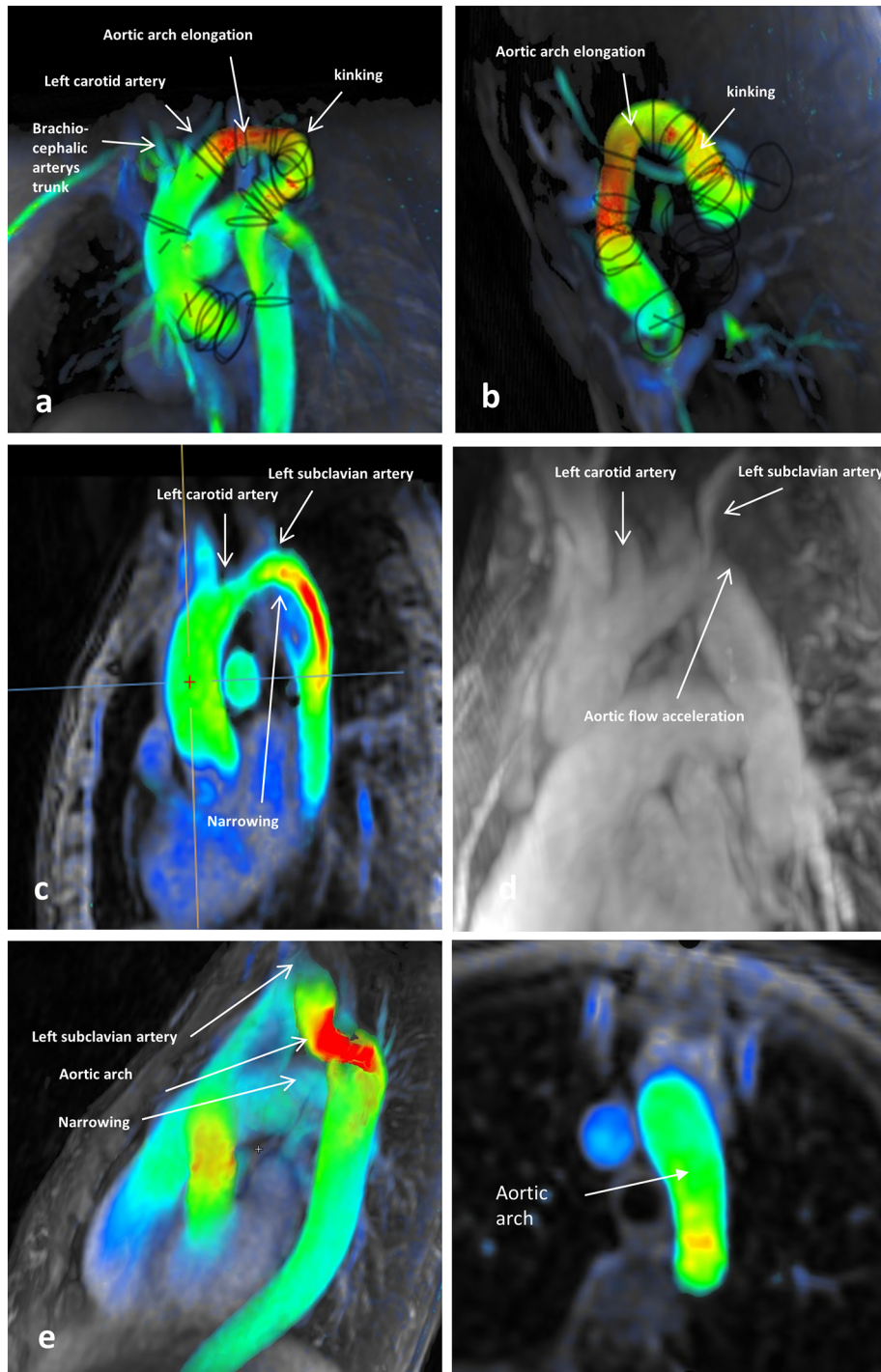
4DFlow CMRs varied with duration of operator's experience and children age. Considering operator's experience, graph shows a clear inflection with a shift at the median value, around 12 months, while the 100% plateau is reached at 14 months, meaning that all unsuccessful 4DFlow CMRs were performed before the 14 months of operator experience (Fig. 6) and suggesting that this variable is no longer a predictive value after. Considering age, 25% of non-contributory examinations occur before 0.7 months, 50% take place before 3 years and 75% of them before 6 years. A plateau is reached at 85% from the age of 7 years (see point) suggesting that its influence fades beyond 10 years (Table 3).

Post-processing's duration was measured at the beginning of the study and estimated at 42.1 ± 7.6 min in children (n = 14) and 31.8 ± 5.5 min in adults (n = 30).

Interobserver and intraobserver agreement for the assessment of whether the 4DFlow CMRs were substantial according to Cohen's kappa values; in adults interobserver's Kappa = 0.72, intraobserver's Kappa = 0.76; in children, interobserver's Kappa = 0.68, intraobserver's Kappa = 0.71. Bowker's test showed no asymmetry; in adults interobserver's *p* value = .654, intraobserver's *p* value = .317; in children, interobserver's *p* value = 1.000, intraobserver's *p* value = .317.

#### 4. Discussion

4DFlow CMR performed as the second-line imaging study after inconclusive echocardiography to assess CHD in children and adults was effective in providing data on all the recommended parameters in the



**Fig. 5.** Aortic abnormalities. a, b. 8-year-old with kinking of the aorta. 4DFlow CMR visualized elongation of the aortic arch with kinking at the level of the ductal ligament. The anatomical evaluation ruled out significant stenosis (<30%). The functional data indicated a diffuse, moderate, and uniform increase in velocity through the entire aortic arch ( $V_{max} = 2.2$  m/s). c, d. 11-year-old with suspected aortic coarctation. The anatomical 4DFlow CMR assessment indicated ductal coarctation with narrowing of a long aortic segment in the region of insertion of the ductus arteriosus. Flow velocity was high (3.7 m/s). There was no evidence of kinking of the left subclavian artery or of aortic arch hypoplasia. Qp/Qs, ratio of total pulmonary blood flow to total systemic blood flow; RVEDV, right ventricular end-diastolic volume; RVESV, right ventricular end-systolic volume; RVEF, right ventricular ejection fraction; VSD, ventricular septal defect;  $V_{max}$ , maximum velocity.

vast majority of patients. In both the children and the adults, successful 4DFlow CMR was significantly associated with the time since the introduction of this modality at our centre. In the children, age was also associated with success. Motion and breathing artefacts were the main reasons for unsuccessful 4DFlow CMRs. No aliasing artefacts occurred. Agreement was substantial within and between observers.

Our study provides information on the clinical usefulness of 4DFlow CMR for the assessment of CHD in children and adults seen in everyday practice. The study population reflected the activity at our high-volume CHD centre, with a broad age range including many children, considerable variation in body size, and a substantial proportion of patients with complex CHD. In all our patients, echocardiography was the first-line

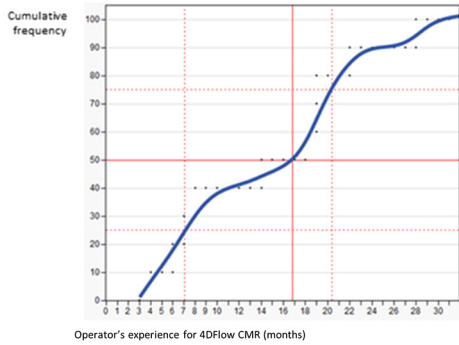
**Table 2**

Variables associated with successful 4DFlow CMR, in adults (a) and in children (b).

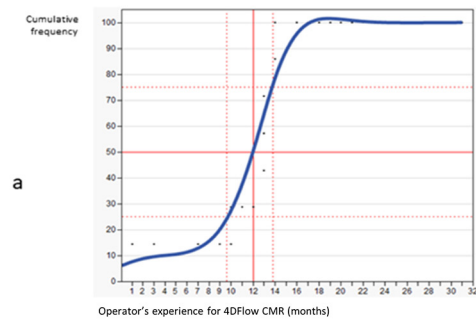
a.			
Univariate analysis	Contributory exam	Non contributory exam	p Value
Height (cm)	165.9 ± 11.6	169.6 ± 15.5	.287
Weight (kg)	65.9 ± 18.2	69.4 ± 18.8	.576
Age (year)	41.1 ± 16.5	42.0 ± 17.6	.866
Diagnosis (n)	177	10	.129
Duration of exam (s)	463.2 ± 87.3	468.4 ± 100.5	.854
Experience with 4DFlow CMR (month)	20.1 ± 8.1	14.6 ± 8.0	.047
b.			
Univariate analysis	Contributory exam	Non contributory exam	p Value
Height (cm)	141.1 ± 34.5	92.1 ± 40.1	.002
Weight (kg)	43.3 ± 24.3	20.3 ± 27.1	.011
Age (year)	12.4 ± 5.2	4.6 ± 5.7	.001
Diagnosis (n)	54	6	.176
Duration of exam (s)	444.2 ± 78.0	442.0 ± 98.8	.941
Experience with 4DFlow CMR (month)	18.9 ± 8.1	11.1 ± 4.7	.015
Multivariate analysis		X <sup>2</sup>	p Value
Age		6.41	.003
Experience with 4DFlow CMR		3.58	.034

CMR: cardiac magnetic resonance.

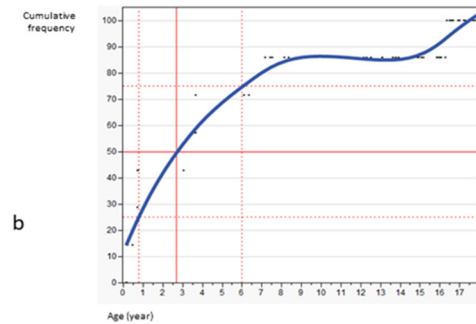
**Figure 2.a - Cumulative frequency graph for non contributory exam in adults among operator's experience for 4DFlow CMR (months)**



**Figure 2.b - Cumulative frequency graph for non contributory exam in children among operator's experience for 4DFlow CMR (months)**



**Figure 2.b - Cumulative frequency graph for non contributory exam in children among age (years).**



**Fig. 6.** a. Cumulative frequency graph for of non-contributory exam in adults among operator's experience for 4DFlow CMR. The curve represents the occurrence of non-contributory review over operator's experience for 4DFlow CMR. It can approximately be considered to be a straight line except for a very slight increase between 17 and 24 months, whereas the lower quartile and the median value are distributed relatively homogeneously as a function of time. The absence of a 100% plateau suggests that time is still an influential variable on all of its values, and therefore here over operator's experience. b. Cumulative frequency graph for non-contributory exam in children among operator's experience for 4DFlow CMR. The curve represents the occurrence of non-contributory review over operator's experience for 4DFlow CMR. It shows a clear inflection with a shift at the median value, while a 100% plateau of non-contributory exam is reached. It suggests that this variable is influent during a limited period and is no longer a predictive value from the 14th months. c. Cumulative frequency graph for non-contributory exam in children among age. The curve represents the occurrence of non-contributory review over age. It shows an inhomogeneous distribution with a clear inflection. Thus 25% of non-contributory examinations occur before 0.7 months, 50% take place before 3 years and 75% of them before 6 years, while a plateau is reached at 85% from the age of 7 years. It suggests that age is an influential variable for the lowest age values, while it fades beyond 10 years.



**Table 3**  
Interobserver and intraobserver agreement for the assessment of whether the 4DFlow CMRs were successful.

a. In adults			
	Bowker's test		Cohen's Kappa
	X <sup>2</sup>	p value	κ
Inter-observer	0.2	.6547	0.72
Intra-observer	1	.3173	0.76
b. In children			
	Bowker's test		Cohen's Kappa
	X <sup>2</sup>	p value	κ
Inter-observer	0	1.000	0.68
Intra-observer	1	.3173	0.71

imaging modality but failed to produce sufficient information. Conventional imaging studies have previously been found inadequate in some patients with CHD [10,26–28].

The likelihood of an unsuccessful 4DFlow CMR decreased as experience using this modality accumulated at our centre. In adults, the fairly uniform distribution of unsuccessful 4DFlow CMRs on the cumulative frequency graph suggested no learning curve. In children, in contrast the learning curve was about 12 months. In addition to less experience, younger age was associated with the likelihood of having an unsuccessful 4DFlow CMR in the children. Small children were particularly challenging to examine. These results suggest that specific training and experience are needed to perform 4DFlow CMR successfully in children with CHD, notably in small children.

Considering the clinical perspective that we defend here of a practical analysis of this technique; reproducibility seems worse than for conventional CMR. First of all, the sequence used is different from that used to estimate the ventricular volumes, SSFPb type, and suffers from a less favorable spatial resolution. Second, most of the princeps studies focused on specific population, whereas our cohort embraces a wide variety of distinct pathologies particularly complex to study. It may contribute to the quite limited reproducibility. Third, measurements are to date almost completely manual. Development of a semi-automated measurement software could be an answer to improve also reproducibility. Finally, the results we obtained here are consistent with those we presented in another multicenter study by our group and the Necker group [20].

The limitations of this study include the observational design and single-centre patient recruitment. However, we included consecutive patients, and our population therefore reflects the conditions of our clinical practice. The prospective design ensured that all the predefined study data were recorded [29–31]. Observational studies are valuable to identify risk factors, predict the usefulness of investigations, and determine how best to adjust imaging modalities to specific patient subgroups [30,32,33]. The restricted availability of 4DFlow CMR at present and the variations in imaging protocols across centres are major barriers to the conduct of a multicentre study. Finally, we did not compare 4DFlow CMR to other second-line imaging modalities. Therefore, our results cannot be construed as supporting 4DFlow CMR as the best second-line imaging study for patients with CHD, particularly given the controversy surrounding the use of gadolinium [12,14–20]. 4DFlow CMR should be used judiciously based on an expectation that the clinical benefits outweigh the theoretical risks, especially in children, given their long-life expectancy.

Otherwise, this study, confirms the main limitation of 4DFlow imaging; time consumption. However, it suggests that certain nuances are to be brought. The progress in the development of MRI technologies in recent years has made it possible to reduce scan times so that the technique has become clinically applicable even for children. In our study, the average acquisition times for 4D-flow are around 7 min with a

maximum of 10 min for children and adults with free breathing processing. As a result, it is relatively comfortable compared to conventional CMR and permitted to simplify the care of patients by requiring only relaxation techniques for adults and light sedations for children. Post-processing remains the critical point of this technique. Even if it is not necessary to reference all of the hemodynamic parameters for each clinical situation, it remains a very limiting step. In the absence of a standardized methodology, we applied the methods used in echocardiography with in particular the need for the concordance of three successive measurements to validate an evaluation. Finally, this data was to appear in this manuscript but remained incomplete. We obtained a duration of 42.1 +/- 7.6 min for post-processing in children (14 evaluations) and 31.8 +/- 5.5 min in adults (30 evaluations). Development of a semi-automated measurement software could be an answer to gain time in post-processing and easiness to use.

## 5. Conclusion

Our results suggest that 4DFlow CMR usually provides a comprehensive assessment of CHD in children and adults in whom first-line echocardiography was inadequately informative. Performing 4DFlow CMR remains challenging in small children.

Supplementary data to this article can be found online at <https://doi.org/10.1016/j.ijcard.2020.07.021>.

## Declaration of competing of interest

None of the authors has any conflicts of interest to declare.

## Funding

This research did not receive any specific grant from funding agencies in the public, commercial, or not-for-profit sectors.

## Credit author statement

Twelve authors participated to this study since the large cohort studied. Each author has significantly contributed to the submitted work and gave final approval of the final version to be submitted.

**Marc-Antoine Isorni**, cardiologist, corresponding author, made substantial contributions to conception and design, acquisition of data, analysis and interpretation of data.

**Louis Moisson**, cardiologist, made substantial contributions to conception and design, acquisition of data, analysis and interpretation of data.

**Nidal Ben Moussa**, pediatric cardiologist, made substantial contributions to conception and design, acquisition of data, analysis and interpretation of data.

**Sébastien Monnot**, engineer, made substantial contributions to conception and design, acquisition of data, analysis and interpretation of data.

**Francesca Raimondi**, cardiologist, made substantial contributions to conception and design, acquisition of data, analysis and interpretation of data.

**Isabelle van Aerschot**, pediatric cardiologist, made substantial contributions to conception and design, acquisition of data, analysis and interpretation of data.

**Regine Roussin**, pediatric surgeon, made substantial contributions to conception and design, acquisition of data, analysis and interpretation of data.

**Emmanuelle Fournier**, pediatric cardiologist, made substantial contributions to conception and design, acquisition of data, analysis and interpretation of data.

**Angèle Boet**, pediatric cardiologist, made substantial contributions to conception and design, acquisition of data, analysis and interpretation of data.

**Sarah Cohen**, cardiologist, made substantial contributions to conception and design, acquisition of data, analysis and interpretation of data.

**Meriem Kara**, pediatric cardiologist, made substantial contributions to conception and design, acquisition of data, analysis and interpretation of data.

**Sébastien Hascoet**, pediatric cardiologist and interventionalist, made substantial contributions to conception and design, acquisition of data, analysis and interpretation of data.

## References

- [1] D.N. Firmin, P.D. Gatehouse, J.P. Konrad, G.Z. Yang, P.J. Kilner, D.B. Longmore, Rapid 7-dimensional imaging of pulsatile flow, *Proceedings of Computers in Cardiology Conference 1993*, pp. 353–356, <https://doi.org/10.1109/CIC.1993.378431>.
- [2] L. Wigström, L. Sjöqvist, B. Wranne, Temporally resolved 3D phase-contrast imaging, *Magn. Reson. Med.* 36 (1996) 800–803.
- [3] M. Markl, F.P. Chan, M.T. Alley, K.L. Wedding, M.T. Draney, C.J. Elkins, D.W. Parker, R. Wicker, C.A. Taylor, R.J. Herfkens, N.J. Pelc, Time-resolved three-dimensional phase-contrast MRI, *J. Magn. Reson. Imaging* 17 (2003) 499–506, <https://doi.org/10.1002/jmri.10272>.
- [4] S. Uribe, P. Beerbaum, T.S. Sørensen, A. Rasmussen, R. Razavi, T. Schaeffter, Four-dimensional (4D) flow of the whole heart and great vessels using real-time respiratory self-gating, *Magn. Reson. Med.* 62 (2009) 984–992, <https://doi.org/10.1002/mrm.22090>.
- [5] J.J.M. Westenberg, S.D. Roes, N. Ajmone Marsan, N.M.J. Binnendijk, J. Doornbos, J.J. Bax, J.H.C. Reiber, A. de Roos, R.J. van der Geest, Mitral valve and tricuspid valve blood flow: accurate quantification with 3D velocity-encoded MR imaging with retrospective valve tracking, *Radiology* 249 (2008) 792–800, <https://doi.org/10.1148/radiol.2492080146>.
- [6] P. Bächler, N. Pinochet, J. Sotelo, G. Crelier, P. Irrazaval, C. Tejos, S. Uribe, Assessment of normal flow patterns in the pulmonary circulation by using 4D magnetic resonance velocity mapping, *Magn. Reson. Imaging* 31 (2013) 178–188, <https://doi.org/10.1016/j.mri.2012.06.036>.
- [7] R.G. Chelu, K.W. Wanambiro, A. Hsiao, L.E. Swart, T. Voogd, A.T. van den Hoven, M. van Kranenburg, A. Coenen, S. Boccalini, P.A. Wielopolski, M.W. Vogel, G.P. Krestin, S.S. Vasanawala, R.P.J. Budde, J.W. Roos-Hesselink, K. Nieman, Cloud-processed 4D CMR flow imaging for pulmonary flow quantification, *Eur. J. Radiol.* 85 (2016) 1849–1856, <https://doi.org/10.1016/j.ejrad.2016.07.018>.
- [8] M.M.P. Driessen, M.A. Schings, G.T. Sieswerda, P.A. Doevendans, E.H. Hulzebos, M.C. Post, R.J. Snijder, J.J.M. Westenberg, A.P.J. van Dijk, F.J. Meijboom, T. Leiner, Tricuspid flow and regurgitation in congenital heart disease and pulmonary hypertension: comparison of 4D flow cardiovascular magnetic resonance and echocardiography, *J. Cardiovasc. Magn. Reson.* 20 (2018) <https://doi.org/10.1186/s12968-017-0426-7>.
- [9] R.G. Chelu, M. Horowitz, D. Sucha, I. Kardys, D. Ingremeau, S. Vasanawala, K. Nieman, J.-F. Paul, A. Hsiao, Evaluation of atrial septal defects with 4D flow MRI—multilevel and inter-reader reproducibility for quantification of shunt severity, *MAGMA* (2018) <https://doi.org/10.1007/s10334-018-0702-z>.
- [10] P. Dyverfeldt, M. Bissell, A.J. Barker, A.F. Bolger, C.-J. Carlhäll, T. Ebbers, C.J. Francios, A. Frydrychowicz, J. Geiger, D. Giese, M.D. Hope, P.J. Kilner, S. Kozerke, S. Myerson, S. Neubauer, O. Wieben, M. Markl, 4D flow cardiovascular magnetic resonance consensus statement, *J. Cardiovasc. Magn. Reson.* 17 (2015) 72, <https://doi.org/10.1186/s12968-015-0174-5>.
- [11] J.F. Feneis, E. Kyubwa, K. Atianzar, J.Y. Cheng, M.T. Alley, S.S. Vasanawala, A.N. Demaria, A. Hsiao, 4D flow MRI quantification of mitral and tricuspid regurgitation: reproducibility and consistency relative to conventional MRI: 4D Flow Quantifies Inlet Valve Regurgitation, *J. Magn. Reson. Imaging* (2018) <https://doi.org/10.1002/jmri.26040>.
- [12] E. Bollache, P. van Ooij, A. Powell, J. Carr, M. Markl, A.J. Barker, Comparison of 4D flow and 2D velocity-encoded phase contrast MRI sequences for the evaluation of aortic hemodynamics, *Int. J. Card. Imaging* 32 (2016) 1529–1541, <https://doi.org/10.1007/s10554-016-0938-5>.
- [13] I. Valverde, S. Nordmeyer, S. Uribe, G. Greil, F. Berger, T. Kuehne, P. Beerbaum, Systemic-to-pulmonary collateral flow in patients with palliated univentricular heart physiology: measurement using cardiovascular magnetic resonance 4D velocity acquisition, *J. Cardiovasc. Magn. Reson.* 14 (2012) 25, <https://doi.org/10.1186/1532-429X-14-25>.
- [14] P. Sjöberg, S. Bidhult, J. Bock, E. Heiberg, H. Arheden, R. Gustafsson, S. Nozohoor, M. Carlsson, Disturbed left and right ventricular kinetic energy in patients with repaired tetralogy of Fallot: pathophysiological insights using 4D-flow MRI, *Eur. Radiol.* 28 (2018) 4066–4076, <https://doi.org/10.1007/s00330-018-5385-3>.
- [15] M. Rose, O. Rahman, S. Schnell, J. Robinson, C. Rigsby, 4D flow MRI demonstrates changes in cardiovascular haemodynamics in complex congenital heart disease, *Eur. Heart J. Cardiovasc. Imaging* 18 (2017) 114, <https://doi.org/10.1093/ehjci/jew204>.
- [16] S. Romeih, H. Aguib, M. Yacoub, Utility of 4D flow mapping in Eisenmenger syndrome with pulmonary atresia, *Cardiol. Young* 26 (2016) 1581–1589, <https://doi.org/10.1017/S1047951116001682>.
- [17] S. Saitta, S. Pirola, F. Piatti, E. Votta, F. Lucherini, F. Pluchinotta, M. Carminati, M. Lombardi, C. Geppert, F. Cuomo, C.A. Figueroa, X.Y. Xu, A. Redaelli, Evaluation of 4D flow MRI-based non-invasive pressure assessment in aortic coarctations, *J. Biomech.* 94 (2019) 13–21, <https://doi.org/10.1016/j.jbiomech.2019.07.004>.
- [18] F. Rengier, M. Delles, J. Eichhorn, Y.-J. Azad, H. von Tengg-Kobligh, J. Ley-Zapozhnan, R. Dillmann, H.-U. Kauczor, R. Unterhinninghofen, S. Ley, Noninvasive 4D pressure difference mapping derived from 4D flow MRI in patients with repaired aortic coarctation: comparison with young healthy volunteers, *Int. J. Card. Imaging* 31 (2015) 823–830, <https://doi.org/10.1007/s10554-015-0604-3>.
- [19] A.N. Thakkar, P. Chinnadurai, C.H. Lin, Imaging adult patients with coarctation of the aorta, *Curr. Opin. Cardiol.* 32 (2017) 503–512, <https://doi.org/10.1097/HCO.0000000000000430>.
- [20] M.A. Isorni, D. Martins, N. Ben Moussa, S. Monnot, N. Boddaert, D. Bonnet, S. Hascoet, F. Raimondi, 4D flow MRI versus conventional 2D for measuring pulmonary flow after Tetralogy of Fallot repair, *Int. J. Cardiol.* (2019) <https://doi.org/10.1016/j.ijcard.2019.10.030>.
- [21] Z.J. Wang, G.P. Reddy, M.B. Gotway, B.M. Yeh, C.B. Higgins, Cardiovascular shunts: MR imaging evaluation, *Radiographics* 23 Spec No (2003) S181–S194, <https://doi.org/10.1148/rg.23si035503>.
- [22] K. Stam, R.G. Chelu, N. van der Velde, R. van Duin, P. Wielopolski, K. Nieman, D. Merkus, A. Hirsch, Validation of 4D flow CMR against simultaneous invasive hemodynamic measurements: a swine study, *Int. J. Card. Imaging* 35 (2019) 1111–1118, <https://doi.org/10.1007/s10554-019-01593-x>.
- [23] S. Fratz, T. Chung, G.F. Greil, M.M. Samyn, A.M. Taylor, E.R. Valsangiacomo Buechel, S.-J. Yoo, A.J. Powell, Guidelines and protocols for cardiovascular magnetic resonance in children and adults with congenital heart disease: SCMR expert consensus group on congenital heart disease, *J. Cardiovasc. Magn. Reson.* 15 (2013) 51, <https://doi.org/10.1186/1532-429X-15-51>.
- [24] M.L. McHugh, Interrater reliability: the kappa statistic, *Biochem. Med. (Zagreb)* 22 (2012) 276–282.
- [25] Principles of Epidemiology: Lesson 4, Section 3|Self-Study Course SS1978|CDC, <https://www.cdc.gov/csels/dsepd/ss1978/lesson4/section3.html> 2019 accessed October 23, 2019.
- [26] P.J. Kilner, Imaging congenital heart disease in adults, *Br. J. Radiol.* 84 (2011) S258–S268, <https://doi.org/10.1259/bjr/74240815>.
- [27] S.S. Vasanawala, K. Hanneman, M.T. Alley, A. Hsiao, Congenital heart disease assessment with 4D flow MRI: CHD assessment for 4D flow, *J. Magn. Reson. Imaging* 42 (2015) 870–886, <https://doi.org/10.1002/jmri.24856>.
- [28] Imaging of congenital heart disease in adults: choice of modalities, *Eur. Heart J. Cardiovasc. Imaging* (2014), *Oxford Academic* <https://academic.oup.com/ehjcmimaging/article/15/1/6/2403388> accessed October 24, 2019.
- [29] E.J. Boyko, Observational research — opportunities and limitations, *J. Diabetes Complicat.* 27 (2013) 642–648, <https://doi.org/10.1016/j.jdiacomp.2013.07.007>.
- [30] J.W. Song, K.C. Chung, Observational studies: cohort and case-control studies, *Plast. Reconstr. Surg.* 126 (2010) 2234–2242, <https://doi.org/10.1097/PRS.0b013e3181f44abc>.
- [31] C.J. Pannucci, E.G. Wilkins, Identifying and avoiding bias in research, *Plast. Reconstr. Surg.* 126 (2010) 619–625, <https://doi.org/10.1097/PRS.0b013e3181de24bc>.
- [32] F. Gueyffier, M. Cucherat, The limitations of observation studies for decision making regarding drugs efficacy and safety, *Therapies* 74 (2019) 181–185, <https://doi.org/10.1016/j.therap.2018.11.001>.
- [33] C.J. Mann, Observational research methods. Research design II: cohort, cross sectional, and case-control studies, *Emerg. Med. J.* 20 (2003) 54–60, <https://doi.org/10.1136/emj.20.1.54>.