

Potts anastomosis in children with severe pulmonary arterial hypertension and atrial septal defect

Alice Capel^{1,2*}, Marilyne Lévy^{1,2}, Isabelle Szezepanski^{1,2}, Sophie Malekzadeh-Milani^{1,2}, Pascal Vouhé^{1,2} and Damien Bonnet^{1,2}

¹M3C-Necker, Hôpital Universitaire Necker-Enfants Malades, APHP, 149, Rue de Sèvres, Paris, 75015, France; ²Université de Paris, Paris, France

Abstract

Aims Potts shunt has been proposed as a bridge or alternative to lung transplantation for children with severe and drug-refractory suprasystemic pulmonary arterial hypertension (PAH). We describe the management of the atrial shunt when a Potts shunt is planned in refractory PAH.

Methods and results We report a case series of children in whom a Potts shunt was done for severe PAH associated with an atrial septal defect to illustrate the different clinical and haemodynamic scenarios. Five children (2 to 13 years) underwent a Potts shunt: three surgical, one percutaneous Potts shunt, and one percutaneous stenting of a restrictive arterial duct. All had associated atrial septal defect. Those who had generalized cyanosis before the procedure had a complicated postoperative course and required longer ventilatory and inotropic support, except the one who had atrial septal defect closure before the Potts shunt. One of the three cyanotic patients died. Two patients with left-to-right shunt before the Potts shunt had an uncomplicated postoperative course.

Conclusions Shunt physiology is only partially predictable after the Potts shunt in children with PAH and atrial septal defect. Abrupt drop in left ventricle preload while the right ventricle is decompressed can potentially be prevented by atrial septal defect closure prior to the Potts shunt.

Keywords Pulmonary arterial hypertension; Paediatrics; Atrial septal defect; Potts shunt

Received: 4 June 2020; Revised: 1 October 2020; Accepted: 5 October 2020

*Correspondence to: Alice Capel, MD, M3C-Necker, Cardiologie congénitale et pédiatrique, Hôpital Necker-Enfants Malades, 149, Rue de Sèvres, 75015 Paris, France.
Email: alice.capel5@gmail.com

Potts shunt is now recognized as an option after failure of aggressive drug treatment in paediatric pulmonary arterial hypertension (PAH).^{1,2} Still, eligibility criteria are not yet fully defined. This is particularly the case for children who have an atrial septal defect associated with PAH. While PAH may complicate the course of chronic left-to-right atrial shunt in adult patients, the co-existence of high pulmonary vascular resistances and atrial septal defect in children is commonly considered coincidental.³ Further, creating an interatrial shunt has been proposed as a palliative treatment for patients with idiopathic PAH and right heart failure.^{4,5} The objective of the atrioseptotomy is to reduce the right atrial filling pressure and to increase the left ventricle preload and, therefore, systemic cardiac output at the price of global cyanosis due to the right-to-left shunt. Originally, the Potts shunt was reintroduced to allow decompression of the suprasystemic right ventricle by right-to-left shunting, with

preservation of coronary arteries and brain oxygenation.² The place of the Potts shunt in patients with atrial septal defect is questionable as they have a physiology of Eisenmenger syndrome, and their outcome should theoretically be satisfactory.⁶ Hitherto, however, children with atrial septal defects and PAH may be severely symptomatic when their desaturation is profound at rest or at exercise limiting drastically their performances.⁷ Lung transplantation in these patients is an alternative with concomitant closure of the atrial septal defect, but 5 year survival remains around 70%, and long-term complications are major concerns.⁸ In the early phase of our experience with the Potts shunt in PAH, we indicated this procedure in a 11-year-old girl who had severe PAH with an atrial septal defect because she had a relative contraindication for lung transplantation.⁹ Since this initial experience, we indicated a Potts shunt or equivalent in five children. We report here these five cases that describe

the difficulties of this procedure and that could help to refine the indications of this complex setting.

Case reports

This retrospective study has been approved by local institutional review board (MR 004-N°2020 0514111303). Informed consent has been obtained from all patients and/or their parents for the reported procedure. According to the French ethics, non-opposition for analysis and report of their medical data to be used in a study has been collected.

Patient 1

She was diagnosed with PAH and associated atrial septal defect at the age of 11 years. Initially, she was in World Health Organization Functional Class (WHO-FC) III with oxygen saturation at rest of 78%. The diagnostic right heart cath is shown in *Table 1*. Initial treatment was a combination of endothelin receptor antagonist (ERA) and PDE-5 inhibitor. No mutation was found in *BMPR2*, *AIK1*, and *endoglin*. After 2 years, she deteriorated, and a control right heart cath showed persistent suprasystemic pulmonary pressures with improved cardiac output. Subcutaneous treprostinil was then introduced. Despite this therapy, she worsened clinically and was admitted in WHO-FC IV with altered right ventricular function on echocardiography and high N-terminal pro-brain natriuretic peptide (NT-proBNP) values. Right heart catheterization (RHC) showed suprasystemic pulmonary pressure (mean pulmonary artery pressure of 101 mmHg for a mean aortic pressure of 66 mmHg). Oxygen saturation was 81%. Her thorax was very narrow at that time, and she was considered having a relative contraindication for lung transplantation. She underwent a surgical Potts shunt anastomosis at the age of 13 years (weight of 23 kg). Immediately after the procedure, she was profoundly desaturated including the right arm. Inotropic support was needed with noradrenaline. On echocardiography, the left ventricle was completely compressed by the dilated right ventricle, the Potts shunt was large with non-restrictive pulmonary artery to aorta shunt, but the flow extended from the site of anastomosis to the horizontal aorta. Cardiac output from the left ventricle was minimal, and the interatrial shunt was left to right. We finally decided to close the atrial septal defect percutaneously 4 days after the Potts shunt considering that the left ventricle could not be preloaded adequately. After percutaneous closure with an Amplatzer device, she could be weaned of mechanical ventilation after 2 days and discharge after 3 weeks. At discharge, echocardiography showed a non-restrictive Potts shunt with a retrograde flow in the aortic arch reaching the innominate artery. Triple combination therapy was continued after surgery. Beta-blockers were

added to attempt to augment left ventricular diastolic filling time. She had to be operated of a discrete tracheal stenosis on by-pass 1 year after the Potts shunt. At last follow-up (age 20 years), she is in WHO-FC II, oxygen saturation is 93% in the upper extremities and 63% in the lower extremities, and 6 min walking distance and NT-proBNP are normal. PAH treatment includes ERA and PDE-5 inhibitor. Right ventricular systolic function is normal with a TAPSE of 17 mm, a largely patent anastomosis with no blood reflux in the aortic isthmus and normal left ventricular volumes and systolic function (see Supporting Information, *Video S1*).

Patient 2

She was diagnosed with PAH associated with a 10 mm large atrial septal defect at 6 months of age. Diagnostic RHC is shown in *Table 1*. She was treated with ERA and PDE-5 inhibitor. At age 6 years, she experienced clinical worsening, and treatment with subcutaneous treprostinil was started.

When she was 10 years old, her condition worsened, and she was admitted in our institution in overt right heart failure. Echocardiography showed a dilated right ventricle with poor systolic function, left ventricle was compressed by the right ventricle, and pericardial effusion was present (see Supporting Information, *Video S2*). RHC showed suprasystemic pulmonary pressures (mean pulmonary artery pressure of 96 mmHg for a mean aortic pressure of 62 mmHg). We decided to perform a transcatheter Potts shunt and to close the atrial septal defect during the same procedure. Immediately after opening the covered stent placed between the descending aorta and the pulmonary artery, aortic pressure dropped abruptly, and she had cardiac arrest. She was put on ECMO, and the atrial septal defect was closed with an Amplatzer device. Cardiac function recovered with an adequate and non-restrictive shunting through the Potts shunt. Unfortunately, brain death was confirmed, and she died 4 days later.

Patient 3

The third patient was 3 years old when she was diagnosed with heritable PAH associated with an atrial septal defect of 16 mm. She had a heterozygous loss of function mutation in the *KCNK3* gene. Diagnostic RHC is shown in *Table 1*. She received up-front triple combination therapy with ERA, PDE-5 inhibitor, and subcutaneous treprostinil. Three years later, after having improved clinically, she was again in WHO-FC III with recurrent syncope. Haemodynamic data show persisting suprasystemic pulmonary pressures with a mild reduction of pulmonary vascular resistances compared with baseline values (*Table 1*). The right ventricular function remained satisfactory, but NT-proBNP values were increased.

Table 1 patients data at diagnosis, at Potts shunt and at last follow-up

	Patient 1		Patient 2		Patient 3		Patient 4		Patient 5		Patient 6		
	At diagnosis	At Potts shunt	Last follow-up	At diagnosis	At Potts shunt	At diagnosis	At Potts shunt	Last follow-up	At diagnosis	At Potts shunt	Last follow-up	At diagnosis	Last follow-up
Age	11 years	13 years	20 years	6 months	10 years	3 years	6 years	7 years	1 year	2 years	8 years	7 years	8 years
Weight (kg)	20	23	41	7.3	20.6	12	17	20	8	12	23	18.5	21.5
WHO-Functional Class	IV	IV	II	IV	IV	III	IV	II	II-IV	IV	I	III	II
Oxygen saturation right hand/pedal (%)	81/-	82/-	87/80	85/-	87/-	80/-	85/-	97/87	91/-	94/-	96/85	95/70	83/-
Haemodynamic	23.5	19.3	—	36	39.3	25.7	21	—	10	8.8	8.5	22.2	—
Pulmonary vascular resistance index (WU/m ²)	—	—	—	—	—	—	—	—	—	—	—	—	—
Right atrial pressure (mmHg)	3	5	—	2	14	6	9	—	6	6	7	4	—
Pulmonary pressure s/d/m (mmHg)	122/71/90	148/75/101	—	122/62/89	132/106/96	94/45/66	93/39/65	—	101/50/69	83/41/60	90/58/73	85/49/66	89/42/64
Aortic pressure s/d/m (mmHg)	80/65/70	83/55/66	—	81/46/60	83/49/62	76/42/56	65/35/48	—	88/42/60	88/42/60	90/60/50	81/47/64	85/41/64
Cardiac index (L/min/m ²)	4.3	7.3	—	2.3	2.3	3.2	3.8	—	6.3	8.2	2.4	3.4	—
LVEF (%)	Normal	Normal	Normal	Normal	Normal	Normal	Normal	Normal	Normal	Normal	Normal	Normal	Normal
Right ventricular function	Poor	Poor	Normal	Normal	Poor	Normal	Normal	Normal	Normal	Poor	Normal	Normal	Normal
TAPSE (mm)	11.7	12.6	16.8	—	16.5	21	20	19	16	14	15	12	15.2
Pericardial effusion	No	No	No	No	Yes	No	No	No	No	Yes	No	No	No
6MWT (m)	251	353	443	NA	259	320	Not done	425	NA	NA	440	NA	332
Hgb (g/dL)	16.5	19.4	19	12.6	9.6	15.2	14	15	12	12.3	13.5	13	16.8
BNP or NT-proBNP (pg/mL)	Normal (BNP 99)	High (1560)	Normal (35)	Normal (BNP 90)	High (501)	High (BNP 556)	High (1358)	Normal (32)	High (10 300)	High (4200)	Normal (27)	Normal (75)	Normal (127)

6MWT, 6 min walk test; Hgb, haemoglobin; LVEF, left ventricular ejection fraction; NA, not applicable; NT-proBNP, N-terminal pro-brain natriuretic peptide; WHO, World Health Organization.

Transoesophageal echocardiography performed during the RHC showed that the atrial septal defect was amenable to percutaneous closure. We therefore closed the shunt percutaneously and did a surgical Potts shunt the following day. The postoperative course was uneventful, and she was discharged with an unchanged PAH treatment with triple therapy. At 1 year follow-up, she is in WHO-FC I. Oxygen saturation is 97% in the upper extremities and 87% in the lower extremities. The echocardiography shows good right and left ventricular function. NT-proBNP values are normal.

Patient 4

He was diagnosed with heritable PAH at 1 year of age in the setting of a familial Rendu-Osler disease. Concomitantly, an 8 mm large atrial septal defect shunting left to right was confirmed. Diagnostic right heart cath is shown in *Table 1*. First-line treatment was an oral combination therapy with ERA and PDE-5 inhibitor. After 4 months, subcutaneous treprostinil was added because of non-improvement. After 9 months and unsatisfactory improvement, he was admitted in WHO-FC IV in overt right heart failure. Right ventricular function was poor on echocardiography with a reduced TAPSE, and NT-proBNP values were high. Oxygen saturation was 94% with no significant shunt through the atrial septal defect. We decided to do a Potts shunt at 2 years of age without closing the atrial septal defect. The postoperative course was uneventful. Nine months after the Potts shunt, subcutaneous treprostinil was stopped, and he remained on oral combination therapy with bosentan and sildenafil. When he was 8 years old, he was in WHO-FC I-II with a right-hand oxygen saturation of 96% for a pedal saturation of 85%. Six minutes walking distance was 440 m. The right ventricular function was normal with a TAPSE of 20 mm, and NT-proBNP values were normal. During exercise, right-hand saturation dropped to 60%. We decided to close the atrial septal defect percutaneously. Six months later, his situation remains good with no upper-limbs desaturation at exercise.

Patient 5

She was referred for cyanosis at 1 year of age, and we diagnosed severe PAH associated with ostium secundum atrial septal defect with variable shunt direction and a small patent arterial duct shunting right to left in systole with a small protodiastolic left-to-right shunting. Diagnostic RHC is shown in *Table 1*. In the diagnostic work-up, she was diagnosed with partial occlusion of the hepatic veins (Budd-Chiari syndrome), but repeated liver ultrasound and computed tomography did not evidence portal hypertension. She was initially treated with a monotherapy with a PDE-5 inhibitor. After 1 year of treatment, she experienced recurrent syncopes. As the

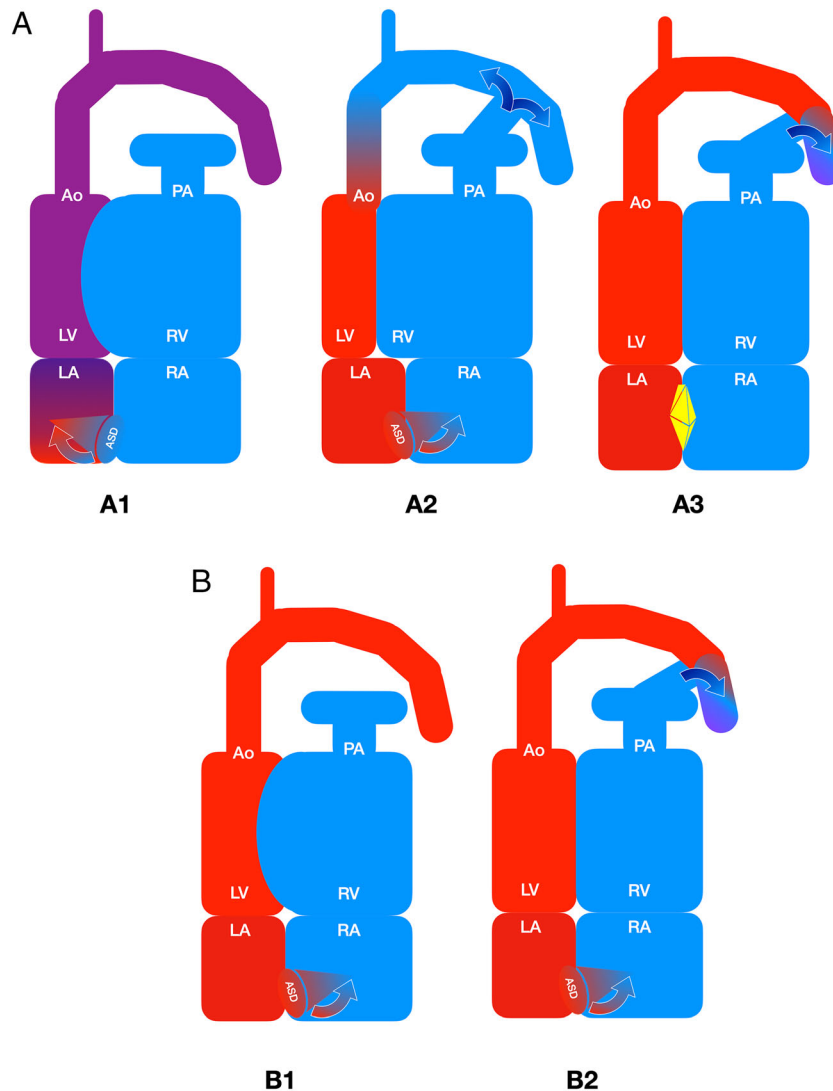
haemodynamic situation was unchanged since diagnosis, we enlarged the restrictive arterial duct with a 6 mm stent without closing the atrial septal defect that was large with insufficient rims. The postoperative course was marked by transient low systemic cardiac output requiring inotropic support and prolonged sedation. Immediately after the procedure, the left ventricle appeared compressed by the right ventricle, but her condition progressively improved, and she could be discharged of intensive care after 4 days. At the last follow-up (age 4 years), she is in WHO-FC I and has no syncope. Right-hand oxygen saturation is 96%, and pedal saturation is 90%. Echocardiography shows good right and left ventricular functions, with a TAPSE of 20 mm. The ductal stent is not restrictive, and the atrial septal defect is shunting left to right at rest. NT-proBNP values are normal. PAH treatment includes bosentan and sildenafil (see Supporting Information, *Video S3*).

Discussion

Potts shunt has already been shown as being a durable palliative approach for the management of patients who aggravate despite maximal medical treatment.^{9–12} In addition, it may also be indicated in patients who have recurrent syncopes particularly at exercise while having infrasytemic resting pulmonary artery pressure.^{13,14} A variety of technical modifications have been proposed including percutaneous and unidirectional-valved shunt approaches.^{13–16} In the present report, we aimed to highlight the difficulties to indicate a Potts shunt in children with atrial septal defect and severe suprasystemic PAH.

The first question would be why performing an arterial shunt as the patient already has a physiology of Eisenmenger? The immediate advantage of the Potts shunt is to preserve normal oxygenation of the coronary arteries and of the brain in these patients if the atrial septal defect is no more shunting right to left or if it has been closed. The normal oxygenation of the chemoreceptors may participate in the clinical improvement of these patients who usually have profound desaturation at exercise. The second advantage of the Potts shunt is to equalize the systolic pressure between pulmonary artery and aorta and to decompress the suprasystemic right ventricle while the atrioseptotomy (or the atrial septal defect) will shunt right to left because of altered right ventricular diastolic function and elevated right atrial pressure or at least reduced right ventricular compliance compared with that of left ventricle. We present here our series of patients because we believe that they illustrate the variability of physiologies of PAH associated with atrial septal defects in children. We learned from the first two patients that creating a Potts shunt may lead to abrupt unloading of the left ventricle (*Figure 1*). Indeed, equalizing

Figure 1 Hypothesis for acute reduction of systemic blood flow after the Potts shunt. (A) Schematic representation of the haemodynamic and shunting situation in Patients 1–3 and 6. (A1) PAH and atrial septal defect with right-to-left shunting and interventricular septum bulging from right to left. Cardiac output is maintained at the price of cyanosis, and pulmonary blood flow is lower than systemic blood flow (Eisenmenger physiology). (A2) Immediately after the Potts shunt, decompression of the right ventricle leads to abrupt reduction of right-to-left shunting through the atrial septal defect (and eventually to left-to-right shunting) with a decrease of left ventricular stroke volume. The right ventricle can provide the flow through the Potts shunt retrogradely to the brain and coronary arteries. (A3) Closing the atrial septal defect restores the systemic blood flow and normal oxygenation of coronary arteries and brain. The Potts shunt perfuses the descending aorta. (B) Schematic representation of the haemodynamic and shunting situation in Patients 4 and 5. (B1 and B2) If the atrial shunt is left to right before the procedure, creating the Potts shunt should not modify the left ventricular stroke volume. Closing the atrial septal defect is not mandatory before the Potts shunt.



the systolic pressures between pulmonary artery and aorta without any change in right/left ventricular compliances can lead to inversion of the interatrial shunt. Consequently, preload of the left ventricle will be dramatically reduced, and left ventricular stroke volume will drop. This led to cardiac arrest and finally brain death in Patient 2 because there was no efficient coronary and cerebral blood flow after the Potts shunt. This could have been anticipated as the right atrial pressure was high (14 mmHg) prior to Potts shunt in this

patient reflecting right ventricular failure. Other factors might have interfered with these changes in preloads and afterloads of both ventricles: ventricular systolic and diastolic functions, balance between pulmonary resistance and systemic resistances, cardiac ischaemia, excessive intraoperative vasodilation, volume depletion, and other factors. Patient 1 probably survived because she had a good right ventricular function before the procedure and the right ventricle could assume at least partially the cardiac output through the Potts

shunt and retrogradely to the ascending aorta (*Figure 1*). Finally, in Patient 3, the sequence of closing the atrial septal defect followed by the Potts shunt appeared to be appropriate.

For Patient 4, the atrial shunt was left to right at rest. Therefore, creating an arterial shunt would not have theoretically changed the direction of the atrial shunting, and preload of the left ventricle was indeed maintained. We indicated later closure of the atrial shunt to improve his cyanosis at exercise without significant increase in right atrial pressure. Patient 5 had a large atrial septal defect but already associated with a patent arterial duct. The physiology here was a mix of the previous examples as she had bidirectional atrial shunting and restrictive arterial shunting with mildly suprasystemic pulmonary pressures. The large opening of the arterial duct with a stent also led to haemodynamic compromise, but it was transient and resolved with inotropic support. This case illustrates the fact that one of the options could be to create a 'progressive' Potts shunt to allow adaptation of the right and left ventricle to new loading conditions. This could potentially be applied to tiny arterial duct stenting in suprasystemic PAH or for percutaneous Potts shunt but not for the other surgical methods. Adjustable banding of a conduit could be an option if it could be externally manipulated.^{17,18} These latter two patients were younger than the first three patients, and both had PAH diagnosed very early in life. This might play a role in the adaptability of the right ventricle to abruptly changing loading conditions.

If the atrial septal defect does not seem amenable to percutaneous closure, a by-pass will be needed to perform a Potts shunt and atrial septal defect closure through a median sternotomy. The duration of by-pass and aortic cross-clamping should be short, and we already had to go on by-pass in one patient during a Potts procedure through left thoracotomy without subsequent complications. The unsolved question is the technical difficulties for creating a direct anastomosis between left pulmonary artery and descending aorta from the front. Indeed, we believe that the best option for a long-lasting Potts shunt is to create a direct anastomosis, that is, a 'classical' Potts shunt. We and others reported our experience of stenting the arterial duct in suprasystemic PAH,^{14,19,20} but during follow-up, we had to dilate or re-stent all of our patients because of recurrence of restriction due to different causes (growth, stent deformation, and one fracture). This was also the case for the majority of our patients who had a percutaneous procedure.¹⁰ In addition, one of our patients who had a valved Potts for recurrent syncope required a stenting of the shunt for restriction of the anastomosis and clinical worsening. The technical alternative would be to implant a valved or non-valved conduit as recently described by Rosenzweig *et al.*¹⁶

In summary, this short series gives some clues to manage drug-refractory PAH with atrial septal defects in young

patients. In the presence of left-to-right atrial shunting at rest, and particularly in the younger patients below 3 years of age, a Potts shunt can be done without closing the atrial septal defect. In older patients with right-to-left atrial shunting, we think that closure of the atrial septal defect should be done shortly before the Potts shunt to avoid brutal unloading of the left ventricle. In patients in whom the atrial septal defect cannot be closed percutaneously, the experience is lacking, but alternative solution to the direct anastomosis can be considered. Further data are needed to better understand the interplay between preoperative ASD closure with Potts anastomosis.

Conflict of interest

D.B. declares no conflict of interest in relation with the present manuscript. He has served as advisor and steering committee member for Actelion Pharmaceuticals, Bayer Health Care, Eli Lilly, and Novartis. The other authors declare no conflict of interest.

Funding

This work was supported by ARCEFA (Association pour la Recherche en Cardiologie du Foetus à l'Adulte).

Author contributions

A.C. acquired all the data, analysed the data, and had an active role in the interpretation of data and in the writing of the manuscript. M.L., I.S., and S.M.-M. contributed substantially to the study design, data analysis and interpretation, and the writing of the manuscript. P.V. revised the manuscript and approved the final version. D.B. designed the study, had full access to all of the data in the study, takes responsibility for the integrity of the data and the accuracy of the data analysis, including and especially any adverse effects, and finally revised the manuscript.

Supporting information

Additional supporting information may be found online in the Supporting Information section at the end of the article.

Video S1. Patient 1. Top: short axis views of the two ventricles before, immediately after the Potts shunt and at last follow-up. Bottom: Four chamber views at the same moment. Note the changing geometry with increased size of the left ventricle and modification of eccentricity index.

Video S2. Patient 2. Short axis view and four chamber view before the Potts shunt. Note pericardial effusion, poor right ventricular systolic function and altered geometry of the left ventricle.

Video S3. Patient 5. Top: Short axis views before and after tiny arterial duct stenting. Bottom left: note the left-to-right atrial shunting. Bottom right: Stenting of the arterial duct with systolic right-to-left shunting.

References

- Rosenzweig EB, Abman SH, Adatia I, Beghetti M, Bonnet D, Haworth S, Ivy DD, Berger RMF. Paediatric pulmonary arterial hypertension: updates on definition, classification, diagnostics and management. *Eur Respir J* 2019; **53**: 1801916.
- Blanc J, Vouhé P, Bonnet D. Potts shunt in patients with pulmonary hypertension. *N Engl J Med* 2004; **350**: 623–623.
- Zijlstra WMH, Douwes JM, Ploegstra MJ, Krishnan U, Roofthoof MT, Hillege HL, Ivy DD, Rosenzweig EB, Berger RM. Clinical classification in pediatric pulmonary arterial hypertension associated with congenital heart disease. *Pulm Circ* 2016; **6**: 302–312.
- Sandoval J, Gaspar J, Pulido T, Bautista E, Martínez-Guerra ML, Zeballos M, Palomar A, Gómez A. Graded balloon dilation atrial septostomy in severe primary pulmonary hypertension. A therapeutic alternative for patients non-responsive to vasodilator treatment. *J Am Coll Cardiol* 1998; **32**: 297–304.
- Chiu JS, Zuckerman WA, Turner ME, Richmond ME, Kerstein D, Krishnan U, Torres A, Vincent JA, Rosenzweig EB. Balloon atrial septostomy in pulmonary arterial hypertension: effect on survival and associated outcomes. *J Heart Lung Transplant* 2015; **34**: 376–380.
- Daliento L, Somerville J, Presbitero P, Menti L, Brach-Prever S, Rizzoli G, Stone S. Eisenmenger syndrome. Factors relating to deterioration and death. *Eur Heart J* 1998; **19**: 1845–1855.
- Moceri P, Kempny A, Liodakis E, Alonso Gonzales R, Germanakis I, Diller GP, Swan L, Marino PS, Wort SJ, Babu-Narayan SV, Ferrari E, Gatzoulis MA, Li W, Dimopoulos K. Physiological differences between various types of Eisenmenger syndrome and relation to outcome. *Int J Cardiol* 2015; **179**: 455–460.
- Hansmann G, Koestenberger M, Alastalo TP, Apitz C, Austin ED, Bonnet D, Budts W, D'Alto M, Gatzoulis MA, Hasan BS, Kozlik-Feldmann R, Kumar RK, Lammers AE, Latus H, Michel-Behnke I, Miera O, Morrell NW, Pieleas G, Quandt D, Sallmon H, Schranz D, Tran-Lundmark K, Tulloh RMR, Warnecke G, Wählender H, Weber SC, Zartner P. 2019 updated consensus statement on the diagnosis and treatment of pediatric pulmonary hypertension: the European Pediatric Pulmonary Vascular Disease Network (EPPVDN), endorsed by AEPC, ESPR and ISHLT. *J Heart Lung Transplant* 2019; **38**: 879–901.
- Baruteau A-E, Belli E, Boudjemline Y, Laux D, Lévy M, Simonneau G, Carotti A, Humbert M, Bonnet D. Palliative Potts shunt for the treatment of children with drug-refractory pulmonary arterial hypertension: updated data from the first 24 patients. *Eur J Cardiothorac Surg* 2015; **47**: e105–e110.
- Boudjemline Y, Sizarov A, Malekzadeh-Milani S, Mirabile C, Lenoir M, Khraiche D, Lévy M, Bonnet D. Safety and feasibility of the transcatheter approach to create a reverse Potts shunt in children with idiopathic pulmonary arterial hypertension. *Can J Cardiol* 2017; **33**: 1188–1196.
- Aggarwal M, Grady RM, Choudhry S, Anwar S, Eghtesady P, Singh GK. Potts shunt improves right ventricular function and coupling with pulmonary circulation in children with suprasystemic pulmonary arterial hypertension. *Circ Cardiovasc Imaging* 2018; **11**: e007964.
- Gorbachevsky SV, Shmalts AA, Barishnikova IY, Zaets SB. Potts shunt in children with pulmonary arterial hypertension: institutional experience. *Interact Cardiovasc Thorac Surg* 2017; **25**: 595–599.
- Bui MT, Grollmus O, Ly M, Mandache A, Fadel E, Decante B, Serraf A. Surgical palliation of primary pulmonary arterial hypertension by a unidirectional valved Potts anastomosis in an animal model. *J Thorac Cardiovasc Surg* 2011; **142**: 1223–1228.
- Boudjemline Y, Patel M, Malekzadeh-Milani S, Szezepanski I, Lévy M, Bonnet D. Patent ductus arteriosus stenting (transcatheter Potts shunt) for palliation of suprasystemic pulmonary arterial hypertension: a case series. *Circ Cardiovasc Interv* 2013; **6**: e18–e20.
- Esch JJ, Shah PB, Cockrill BA, Farber HW, Landzberg MJ, Mehra MR, Mullen MP, Opatowsky AR, Waxman AB, Lock JE, Marshall AC. Transcatheter Potts shunt creation in patients with severe pulmonary arterial hypertension: initial clinical experience. *J Heart Lung Transplant* 2013; **32**: 381–387.
- Rosenzweig EB, Ankola A, Krishnan U, Middlesworth W, Bacha E, Bacchetta M. A novel unidirectional-valved shunt approach for end-stage pulmonary arterial hypertension: early experience in adolescents and adults. *J Thorac Cardiovasc Surg* 2019 S0022-5223(19) 32771-0. **33**:542–546.
- Grady RM, Eghtesady P. Potts shunt and pediatric pulmonary hypertension: what we have learned. *Ann Thorac Surg* 2016; **101**: 1539–1543.
- Corno AF, Bonnet D, Sekarski N, Sidi D, Vouhé P, von Segesser L. Remote control of pulmonary blood flow: initial clinical experience. *J Thorac Cardiovasc Surg* 2003; **126**: 1775–1780.
- Latus H, Apitz C, Moysich A, Kerst G, Jux C, Bauer J, Schranz D. Creation of a functional Potts shunt by stenting the persistent arterial duct in newborns and infants with suprasystemic pulmonary hypertension of various etiologies. *J Heart Lung Transplant* 2014; **33**: 542–546.
- D'Alto M, Santoro G, Palladino MT, Parisi F, Russo MG. Patent ductus arteriosus stenting for palliation of severe pulmonary arterial hypertension in childhood. *Cardiol Young* 2015; **25**: 350–354.