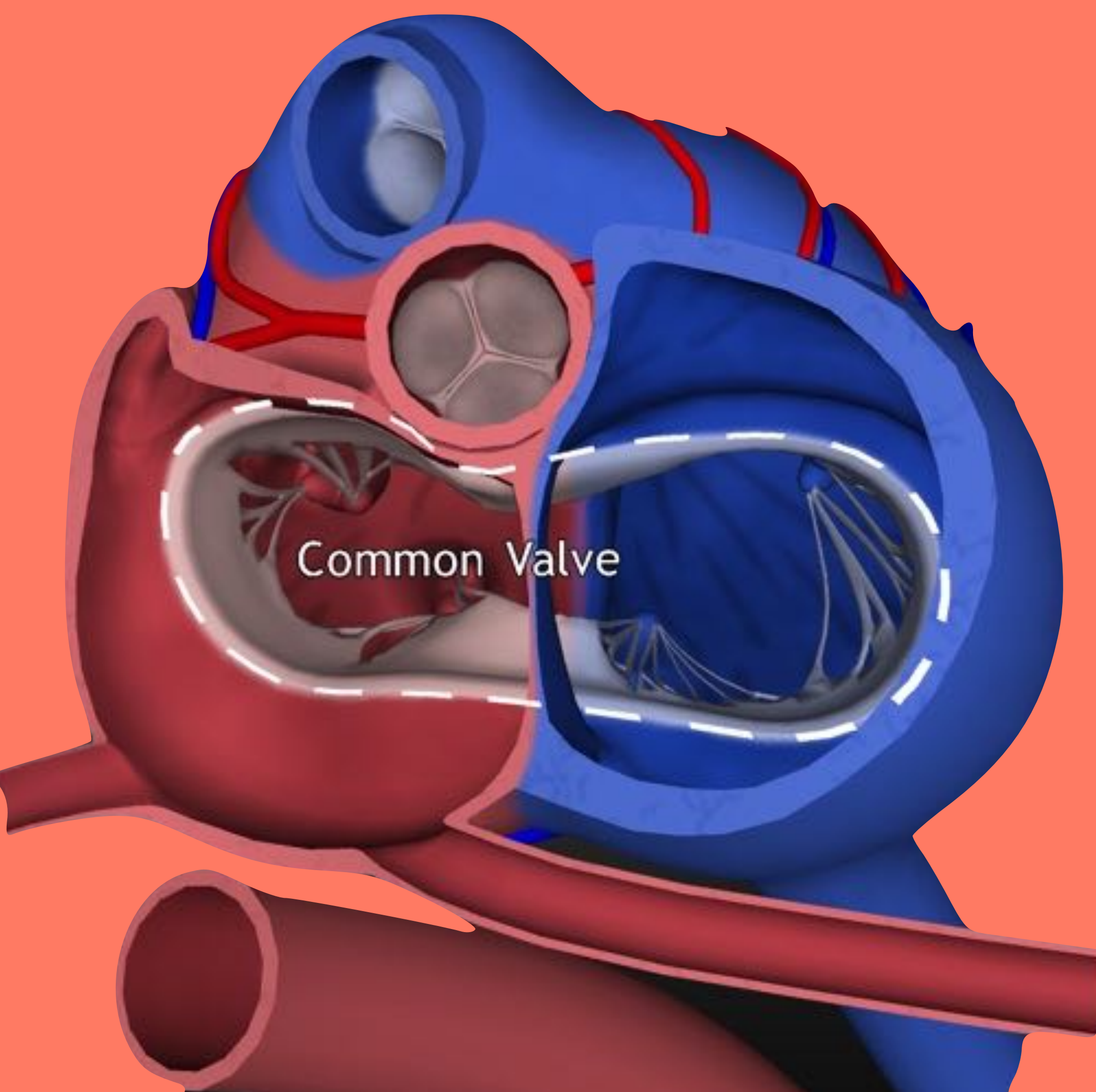

# Atrioventricular septal defects

**Damien Bonnet**

Service de Cardiologie Congénitale et Pédiatrique  
Hôpital Universitaire Necker Enfants malades – APHP

Université de Paris

INSERM-U781 - Institut Hospitalo-Universitaire IMAGINE

*Centre de Référence Maladies Rares*

**Malformations Cardiaques Congénitales Complexes-M3C**

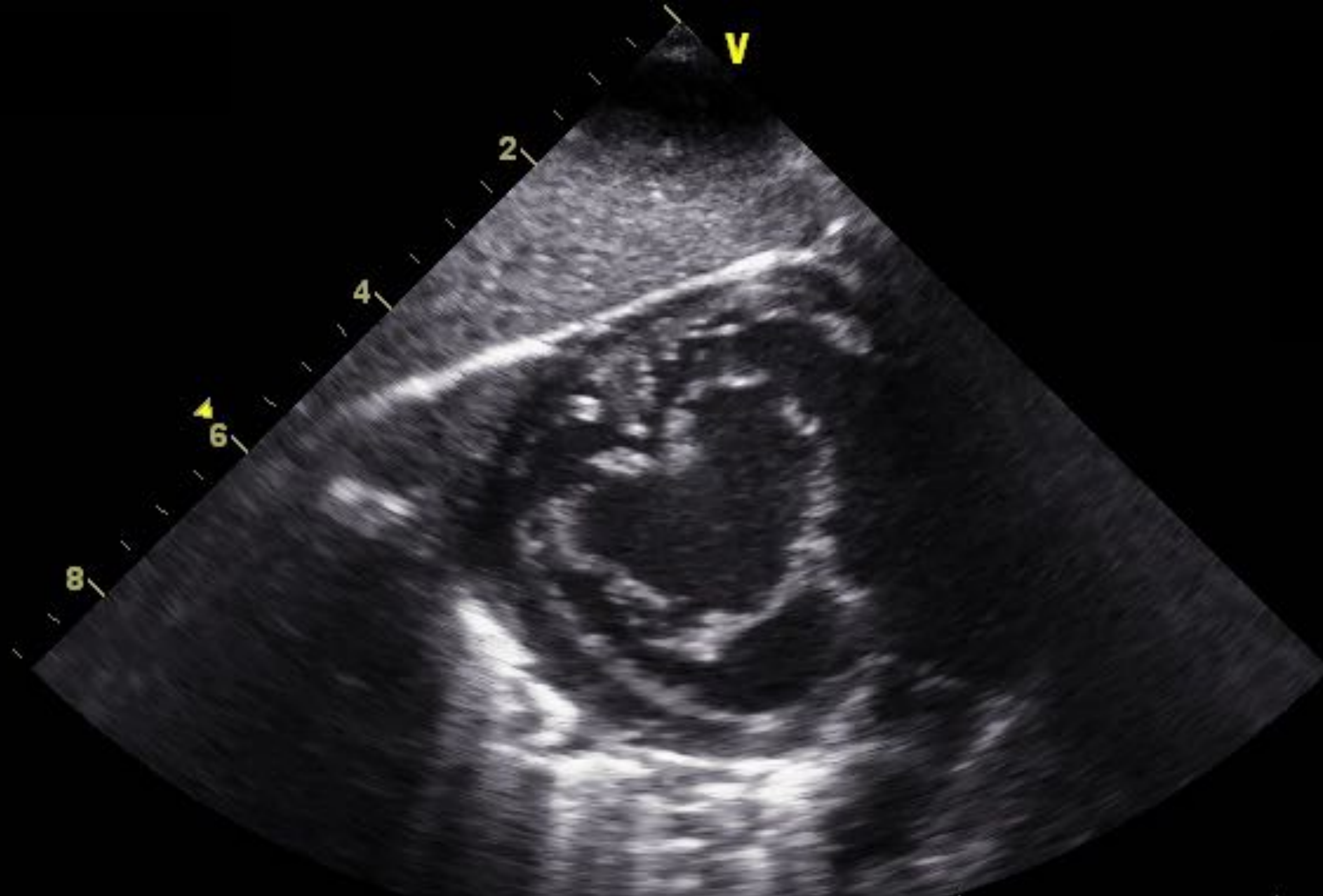
*Centre de Référence Maladies Rares*

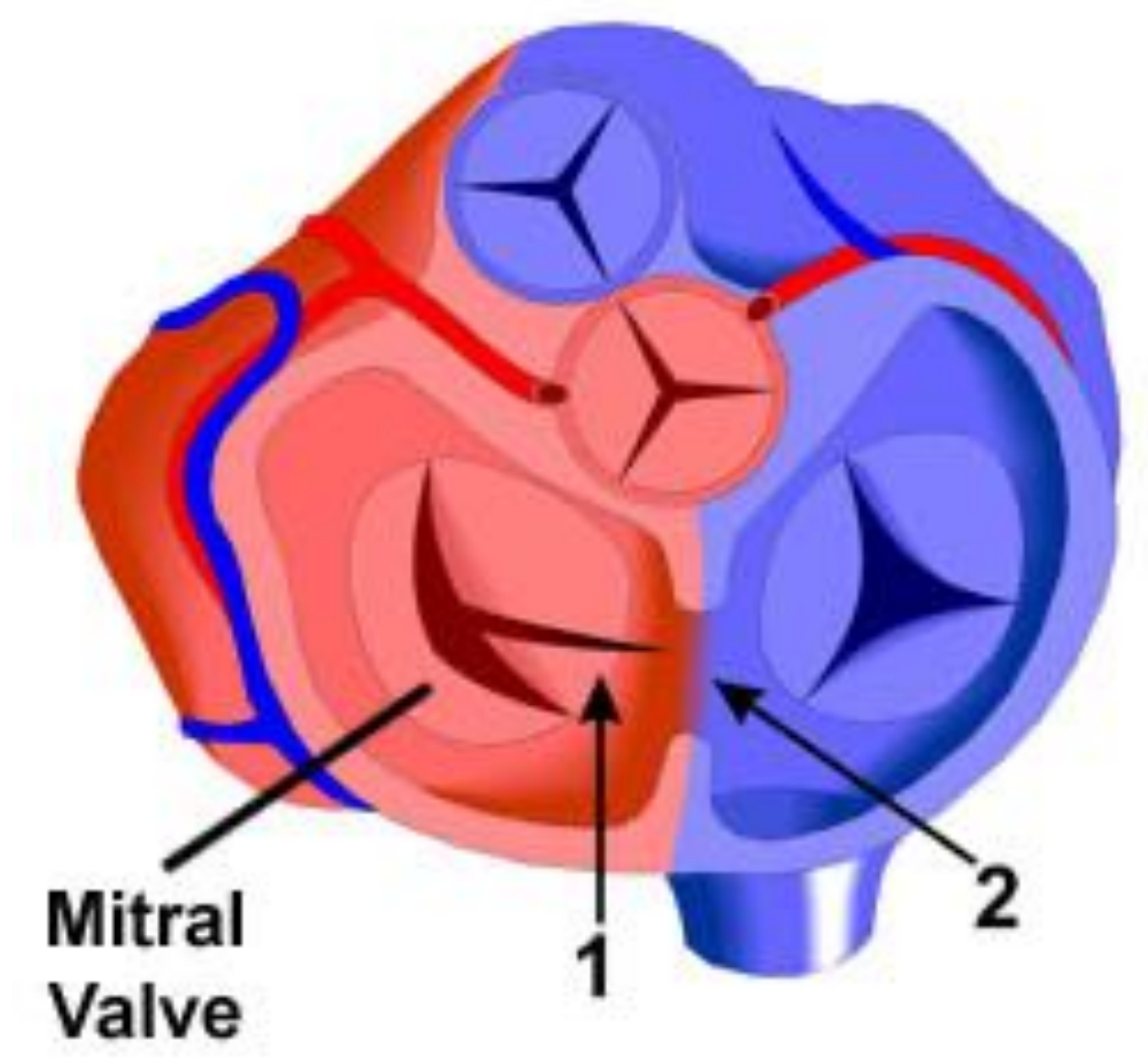
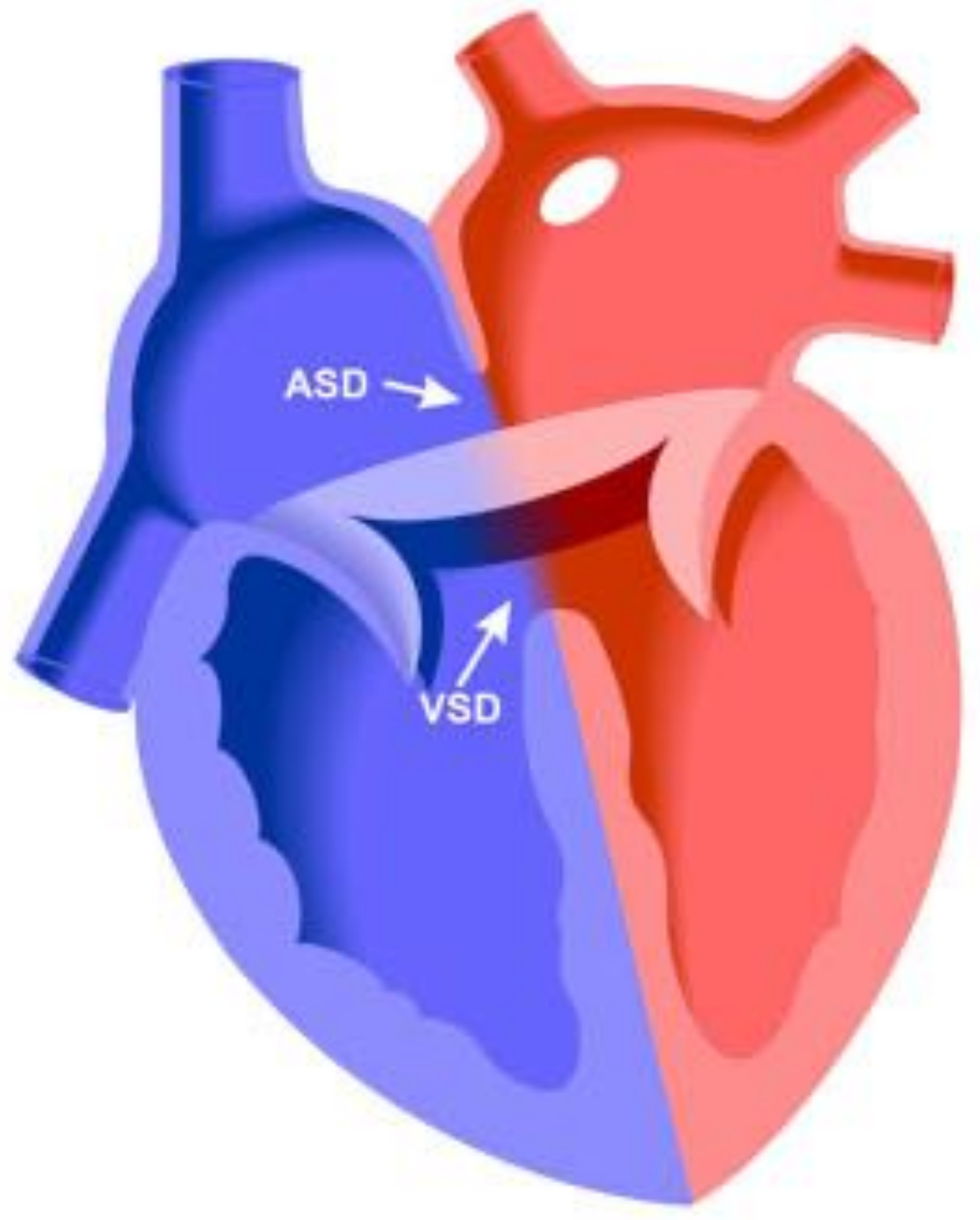
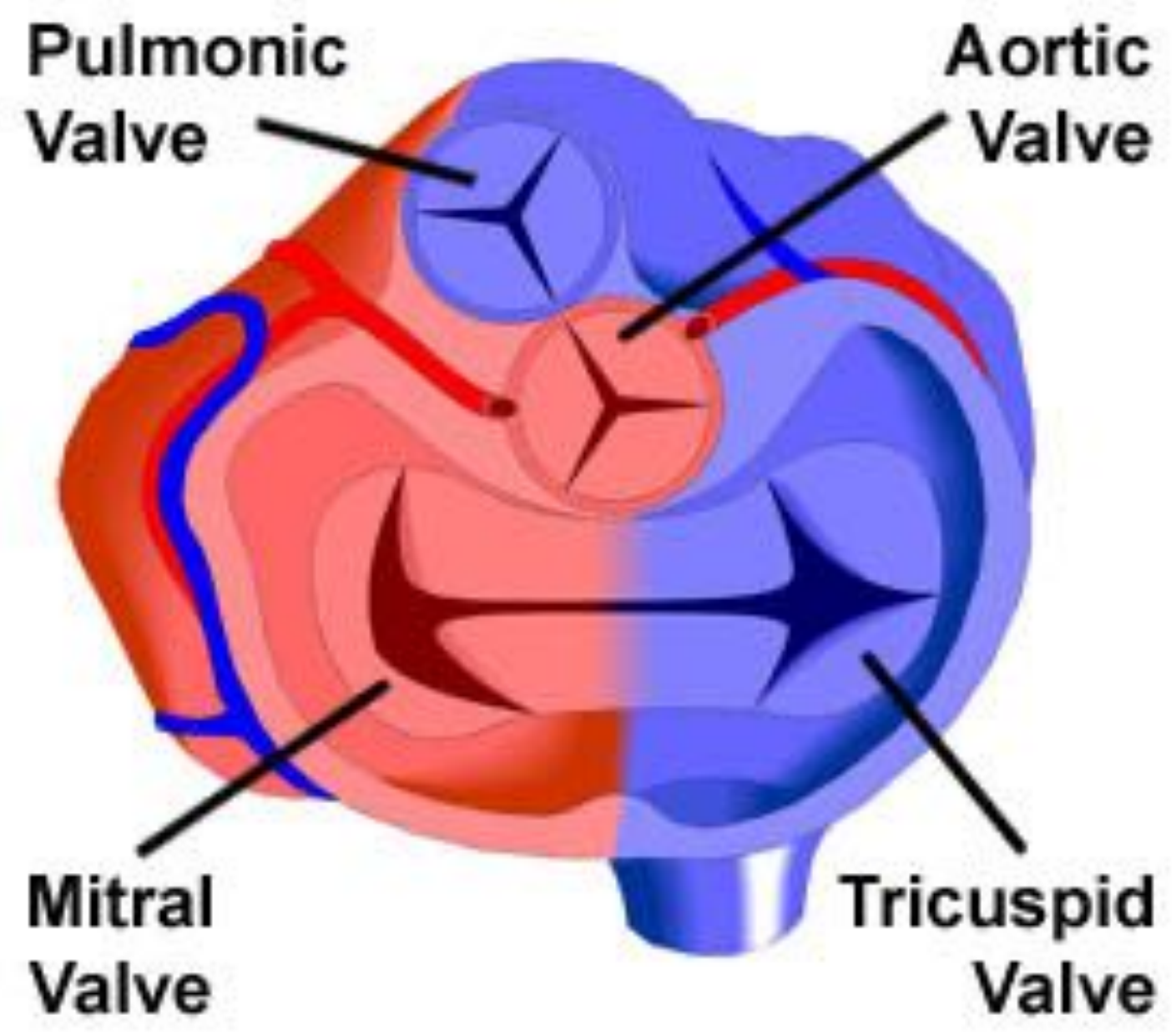
**Maladies Cardiaques Héritaires- CARDIOGEN**



# Canal atrioventriculaire : définition

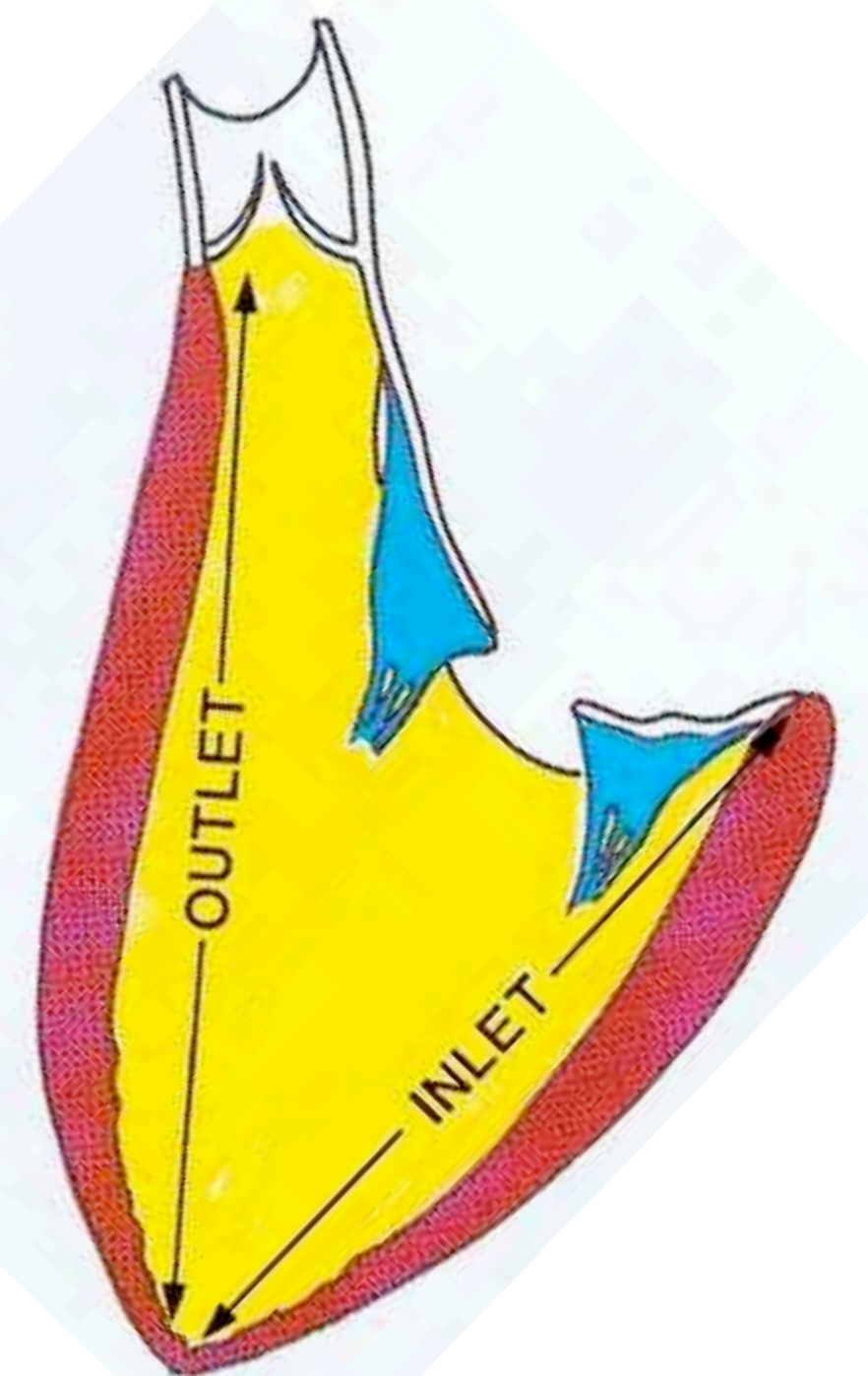
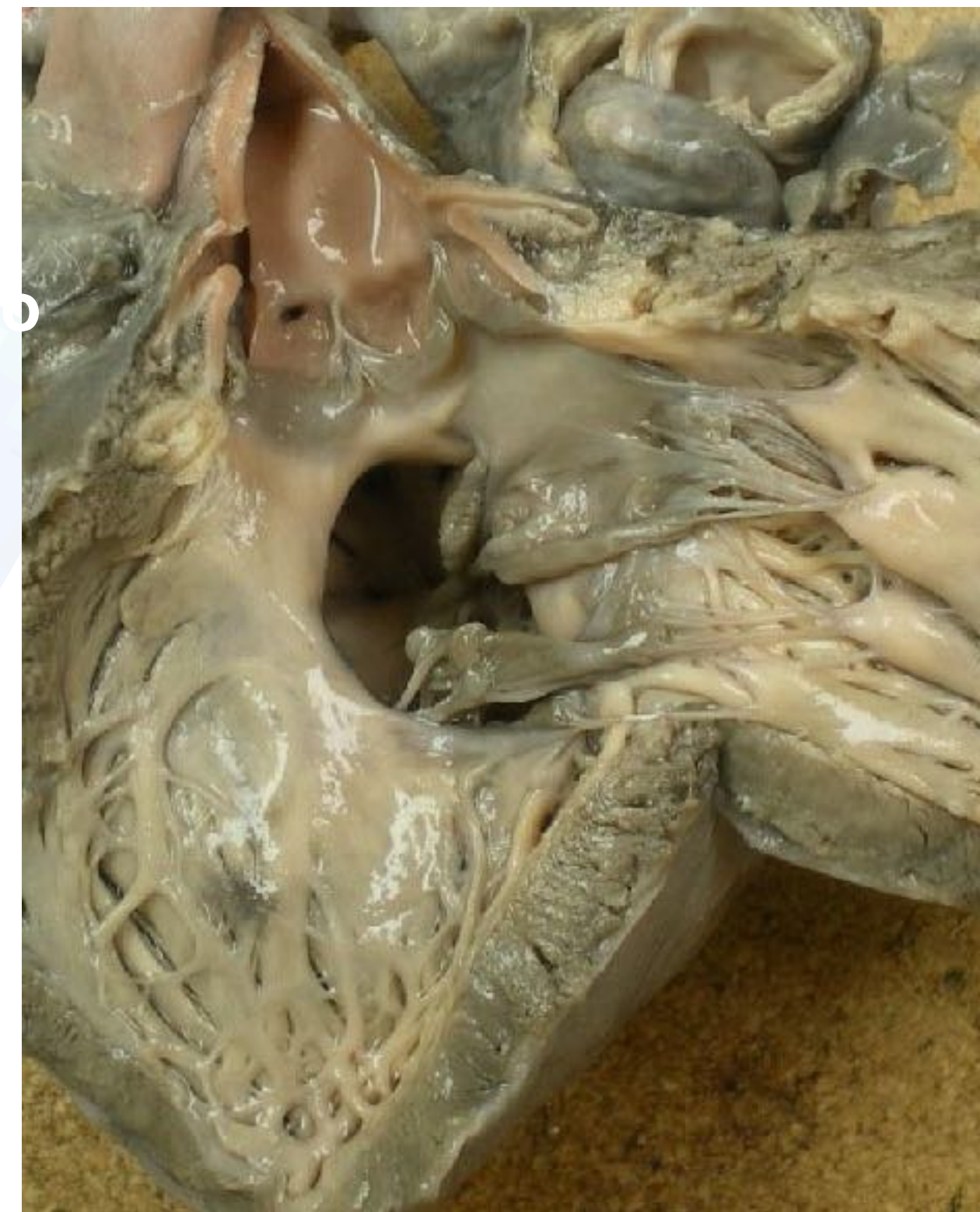

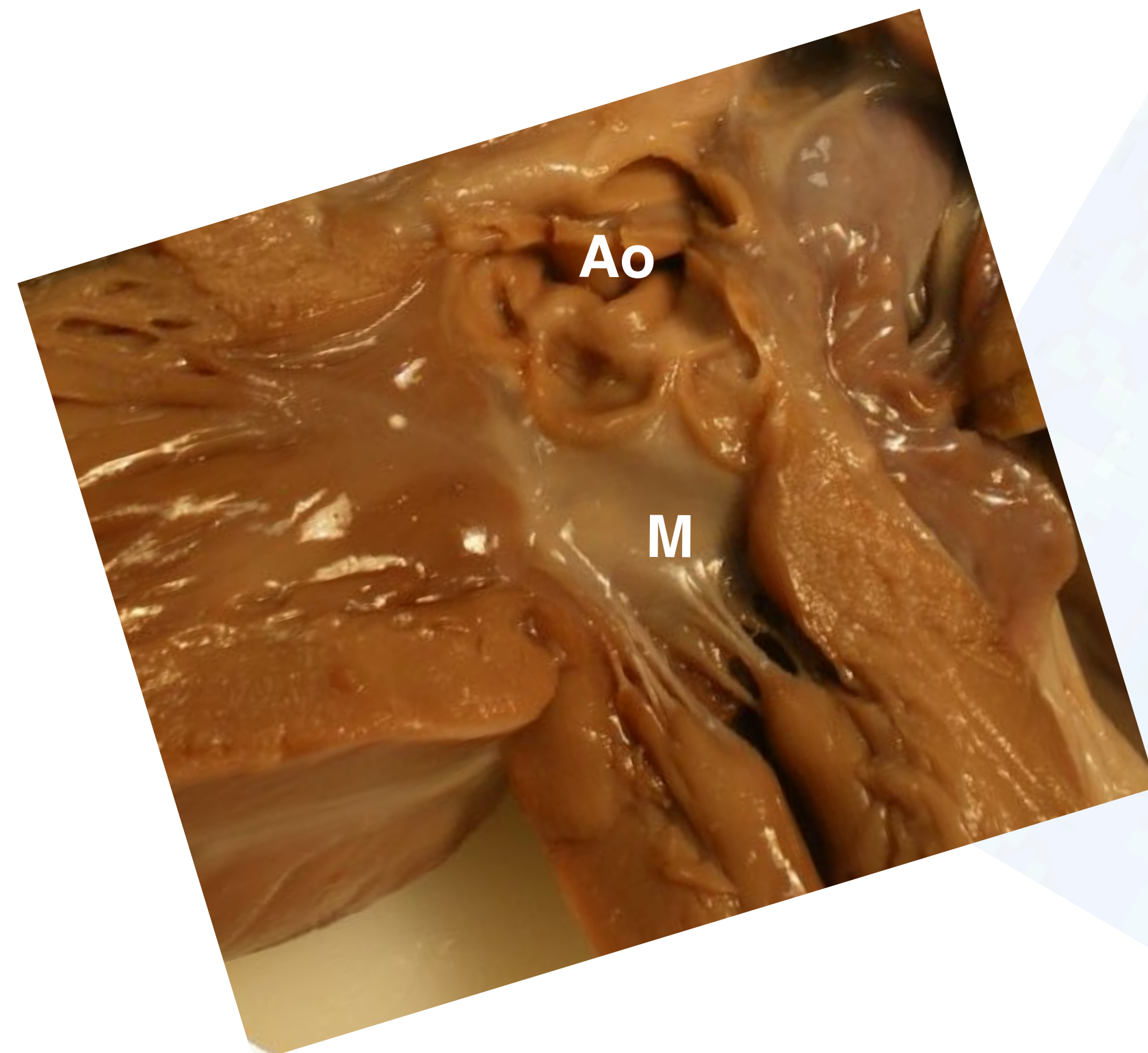
- **Anatomique** : zone de jonction entre oreillettes et ventricules, composée de :
  - Valves atrioventriculaires
  - Partie basse du septum interauriculaire
  - Partie postéro-inférieure du septum interventriculaire : Septum d'admission
- **Pathologique** : cardiopathie congénitale
  - Jonction auriculoventriculaire commune (un seul anneau)
  - CIA type ostium primum
  - CIV d'admission
- **Embryologique** : l'ensemble de cette jonction s'organise autour du mésenchyme des bourgeons endocardiques du canal



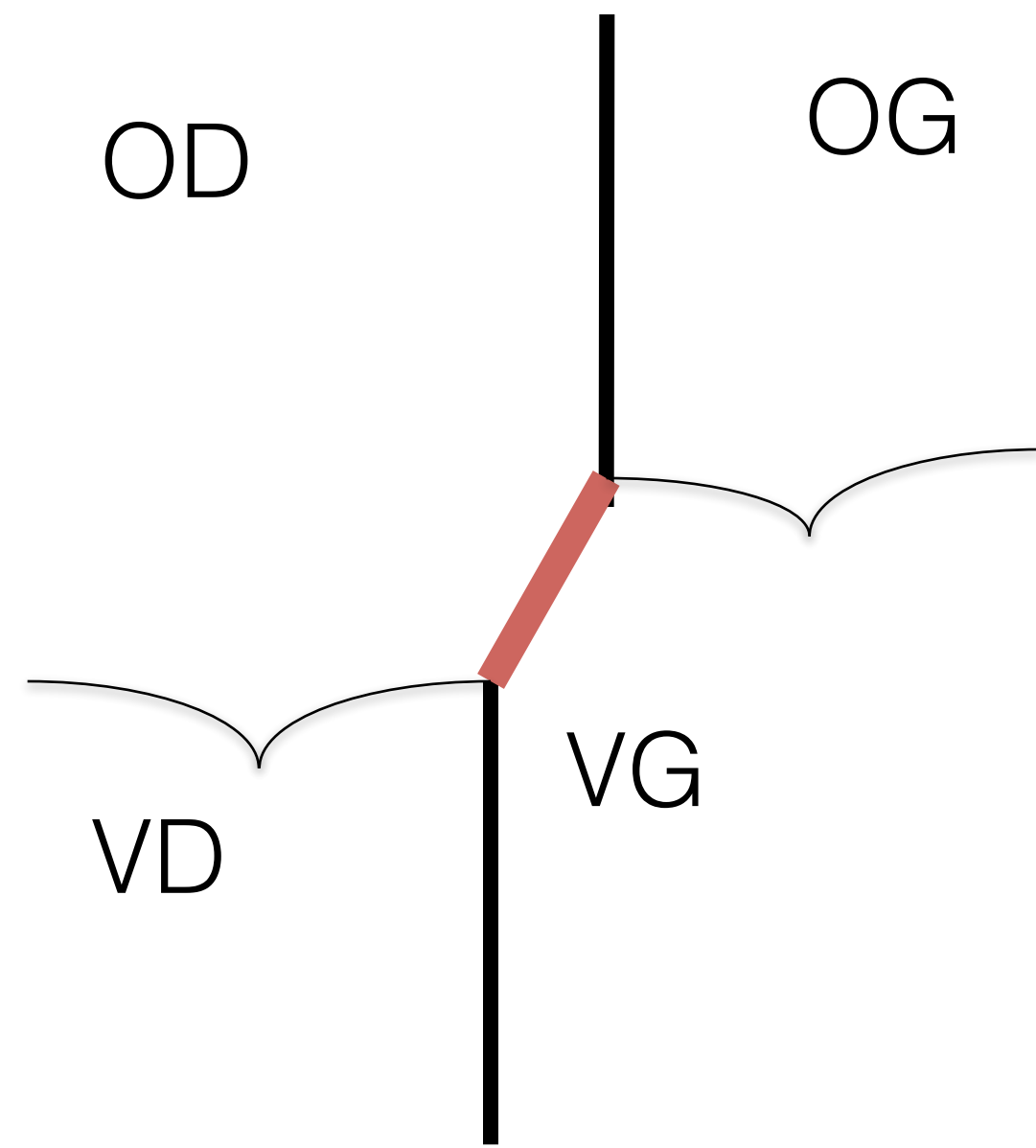


## **CAV : l'aorte est « unwedged », au-dessus de la valve commune**

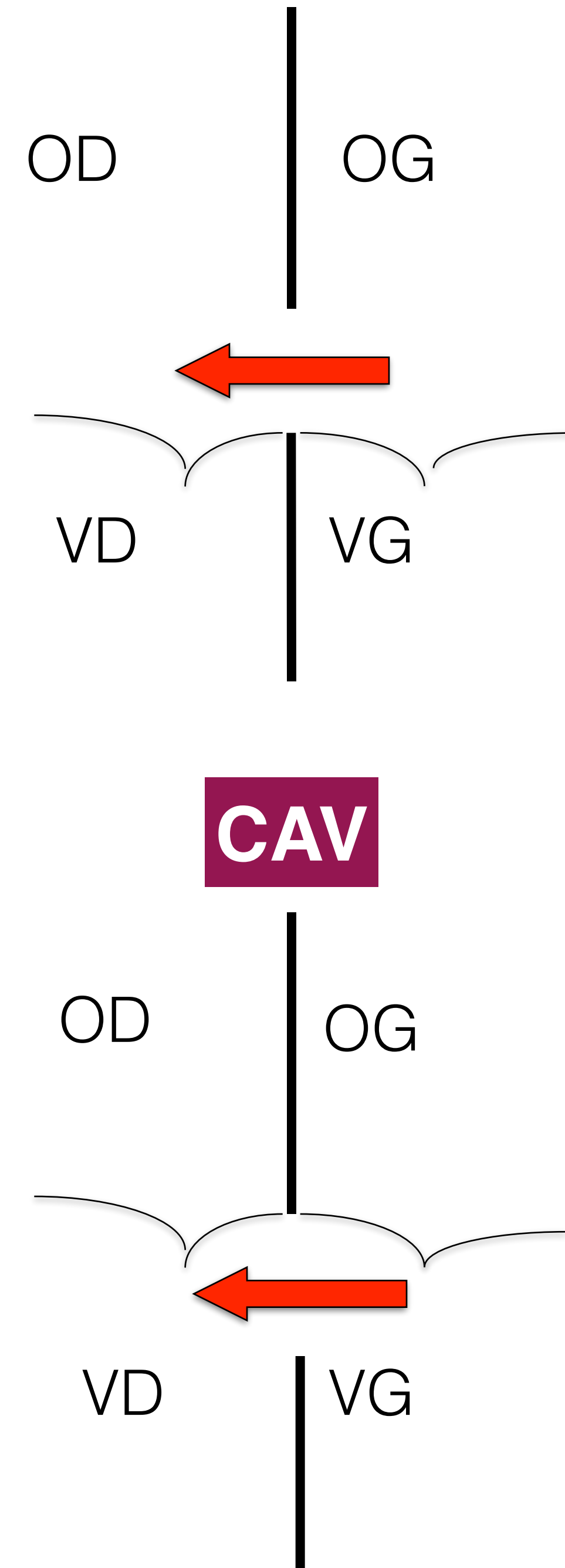
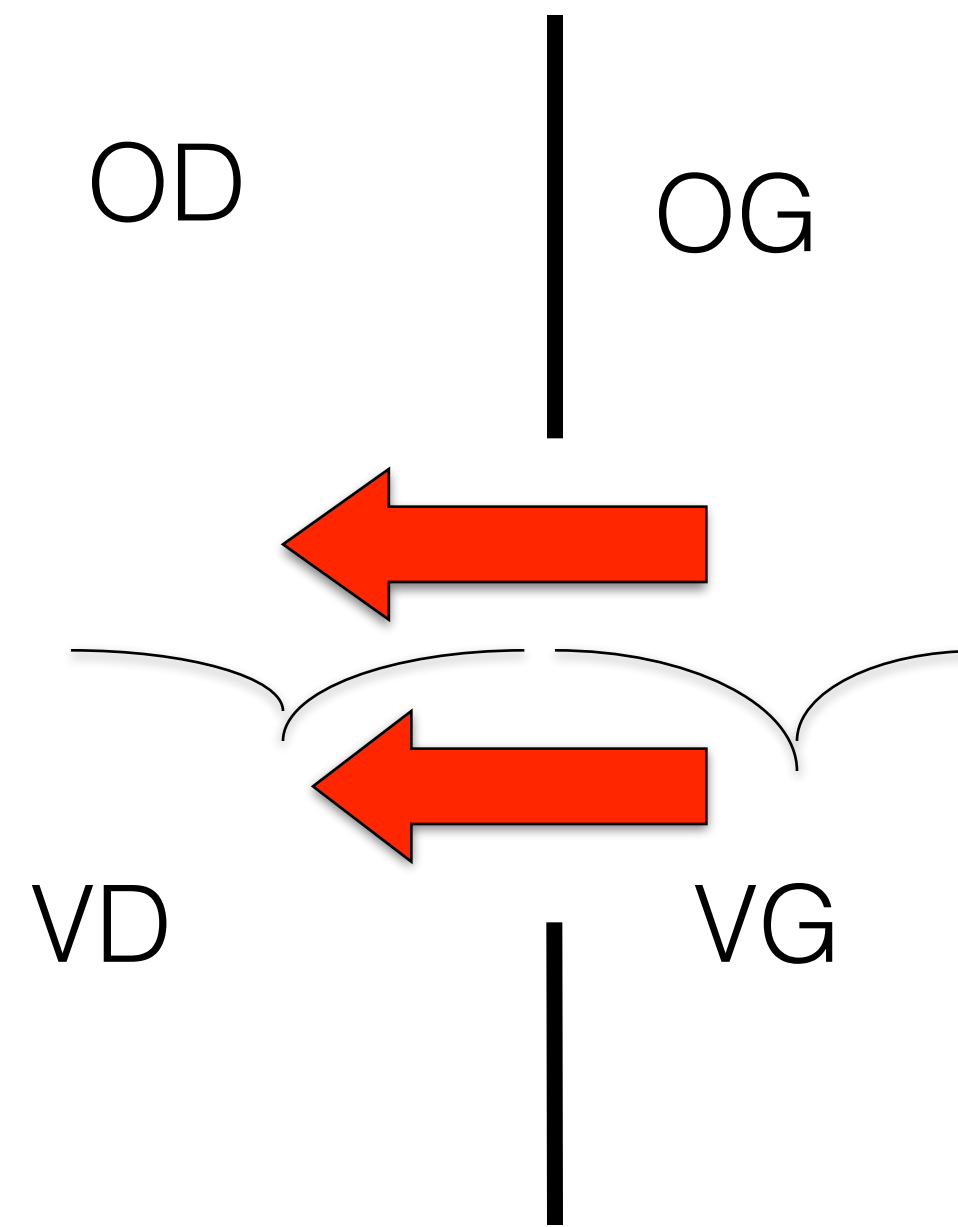
- CAV : défaut de formation du septum d'admission
- Aspect « scooped-out »
- Voie d'éjection plus longue et plus étroite
- Mais continuité mitro-aortique



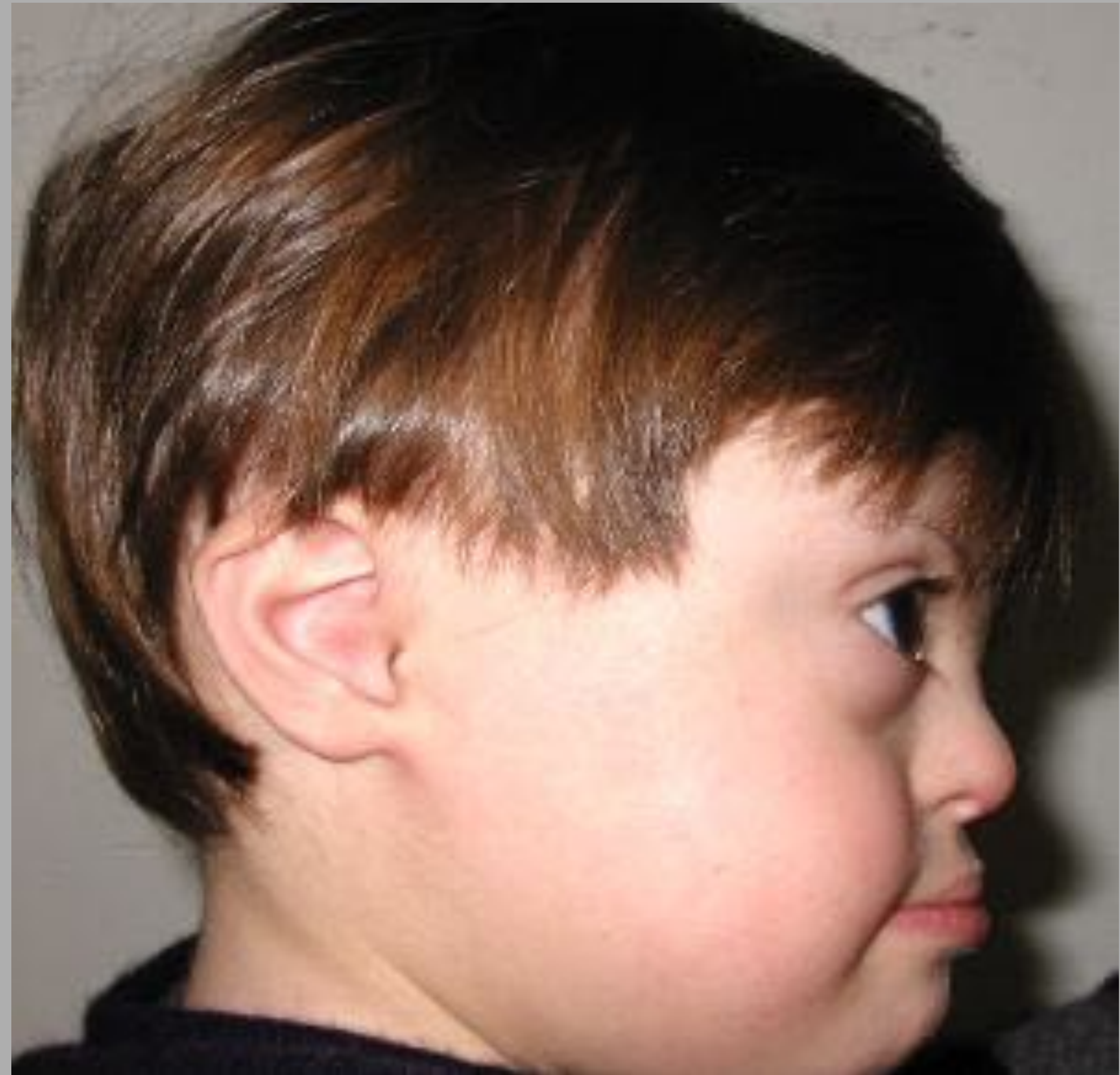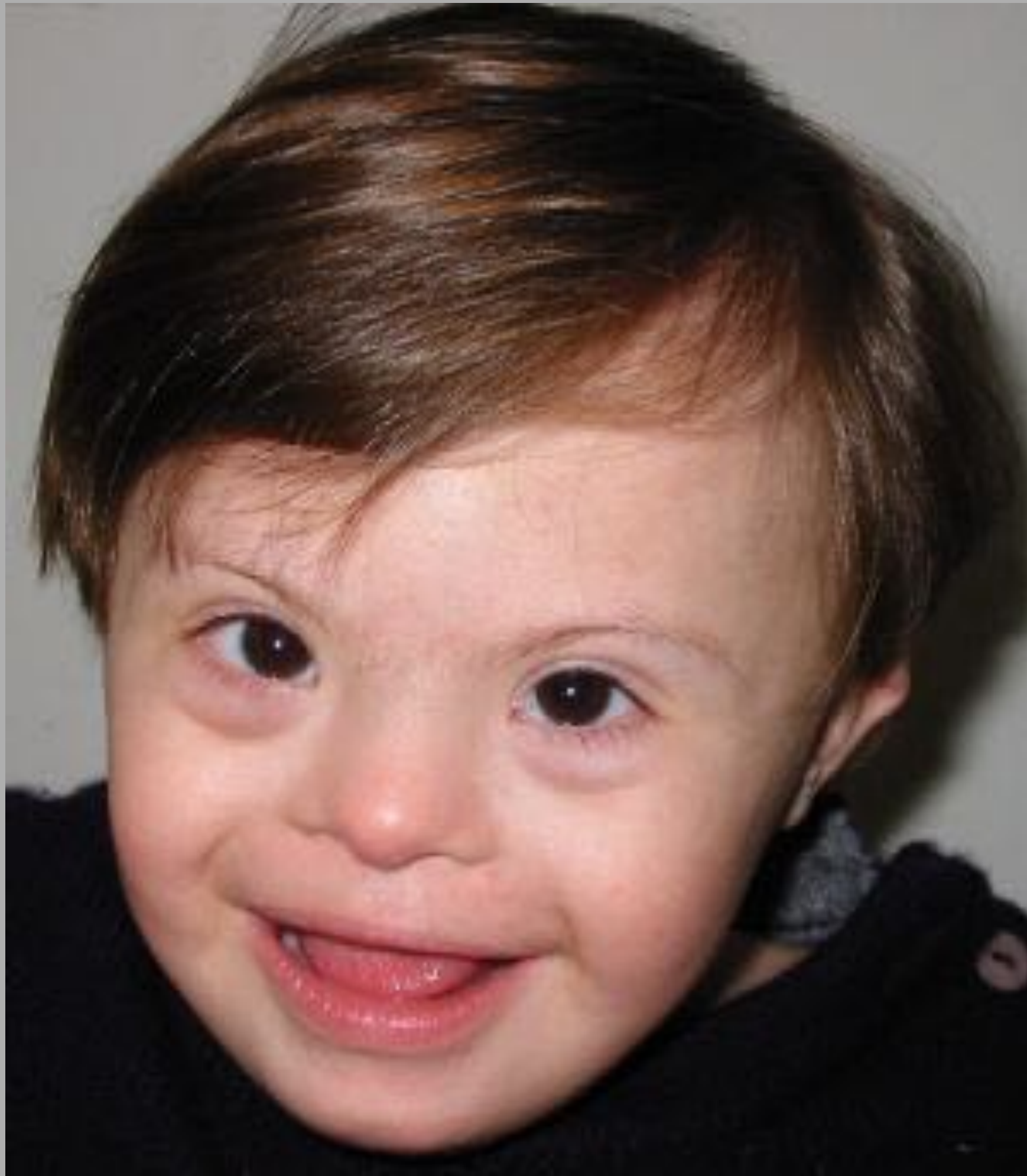# Septation atrioventriculaire

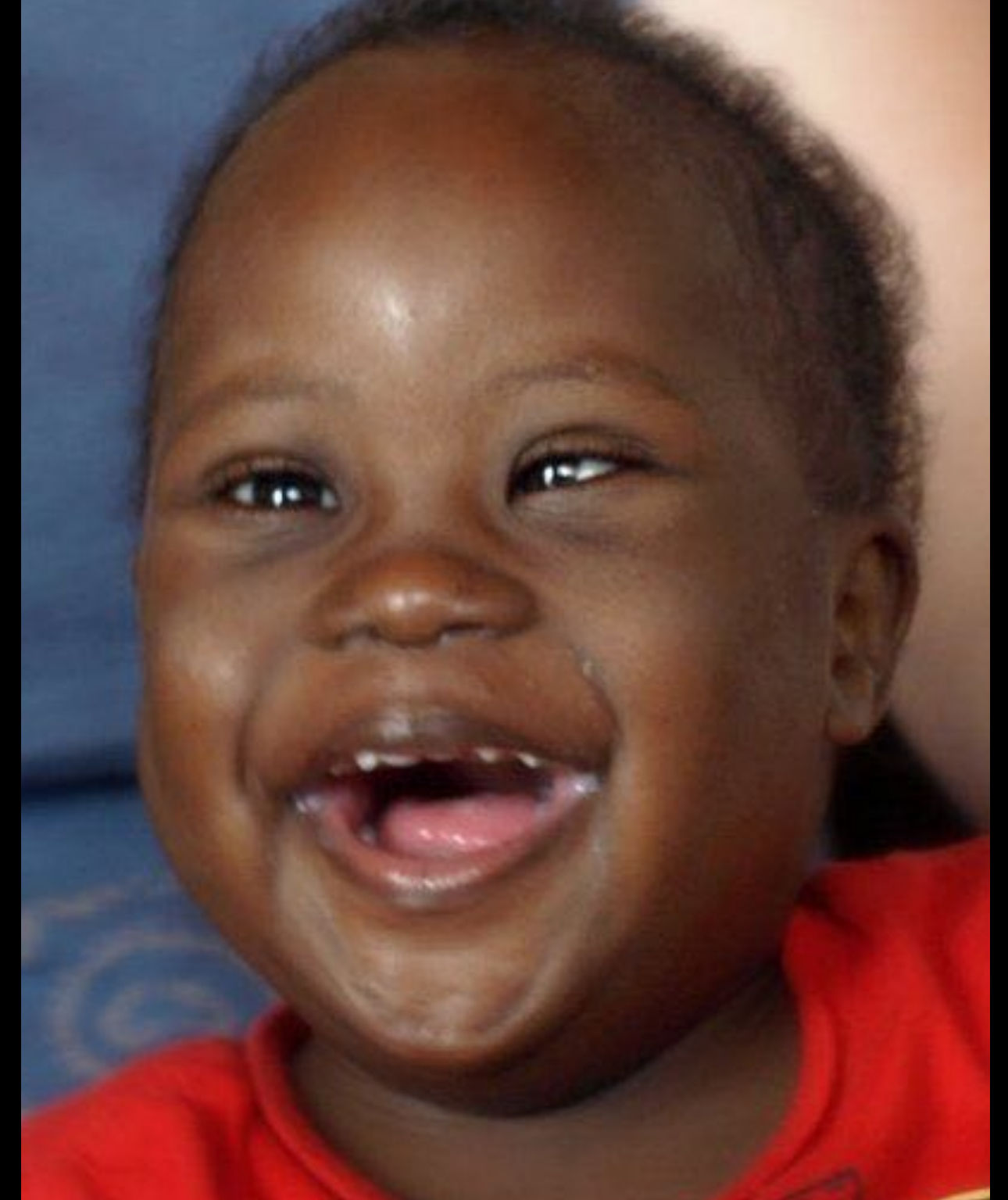
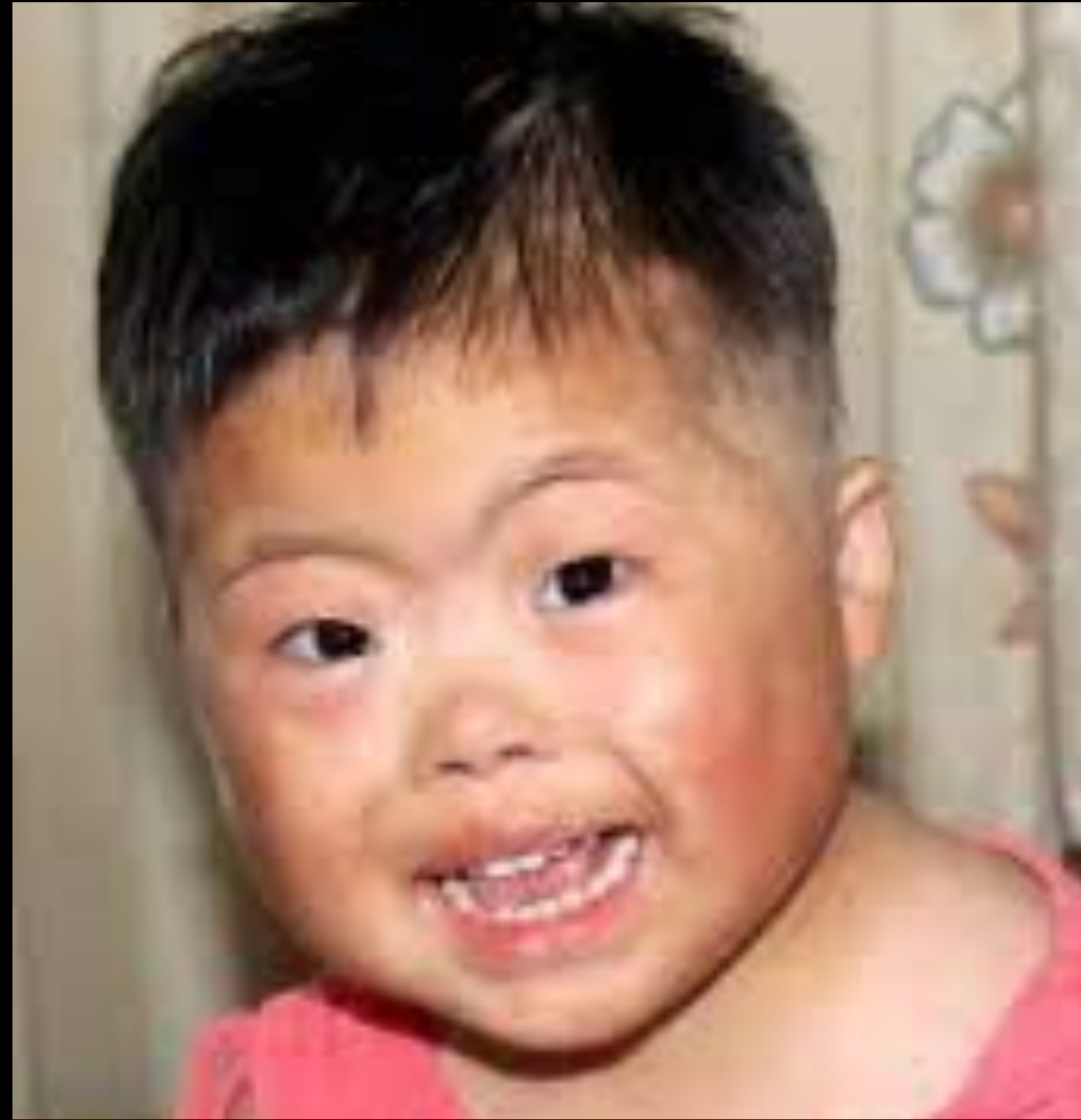
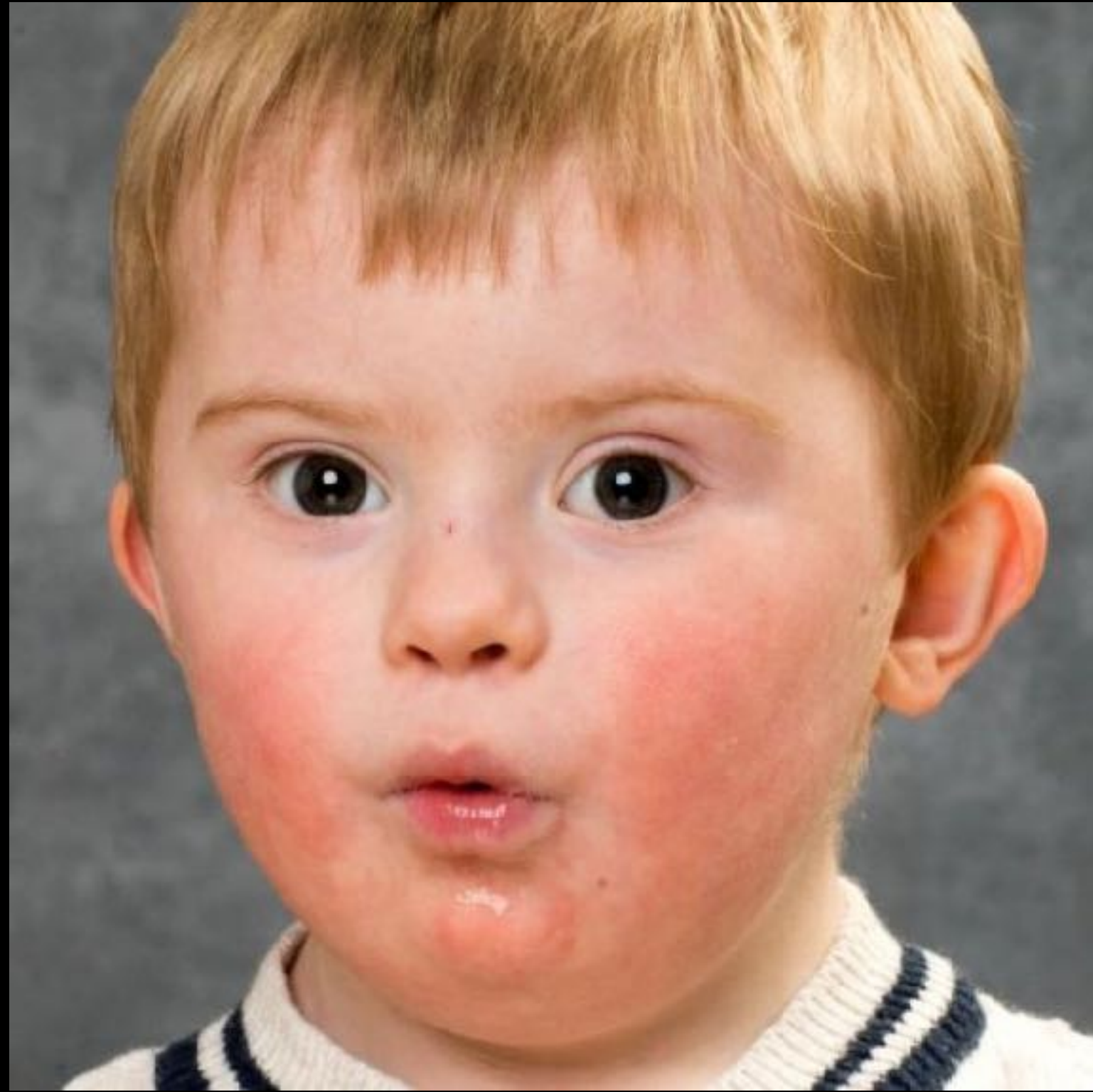
**Coeur normal**



# Genetics of AVSD





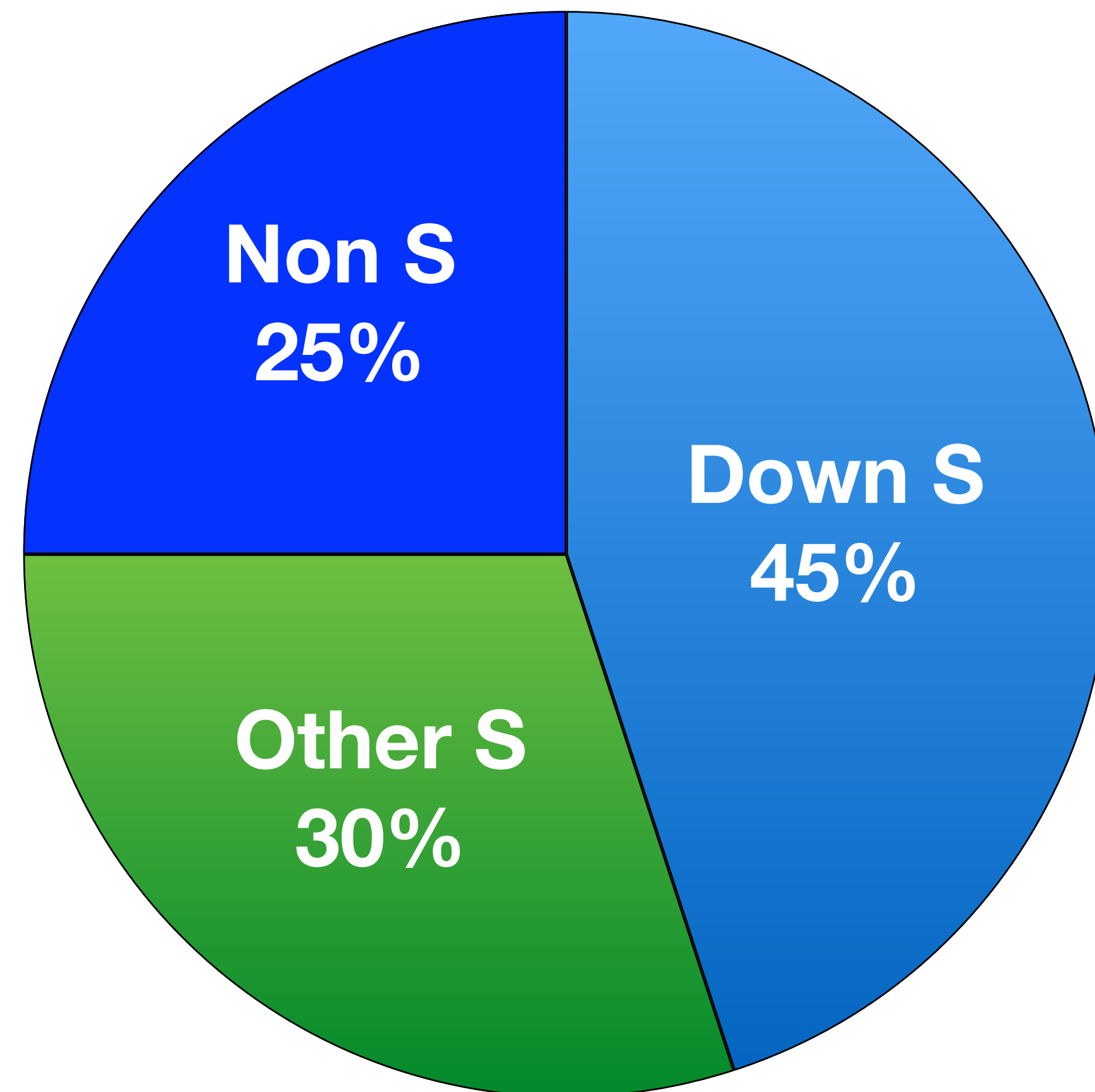


# Atrioventricular Canal Defect Without Down Syndrome: A Heterogeneous Malformation

**Maria Cristina Digilio,<sup>1</sup> Bruno Marino,<sup>1\*</sup> Alessandra Toscano,<sup>1</sup> Aldo Giannotti,<sup>1</sup> and Bruno Dallapiccola<sup>2</sup>**


<sup>1</sup>*Departments of Pediatric Cardiology and Medical Genetics, Bambino Gesù Hospital, Rome, Italy*

<sup>2</sup>*Chair of Medical Genetics, Tor Vergata University, and C.S.S.—Mendel Institute, Rome, Italy*



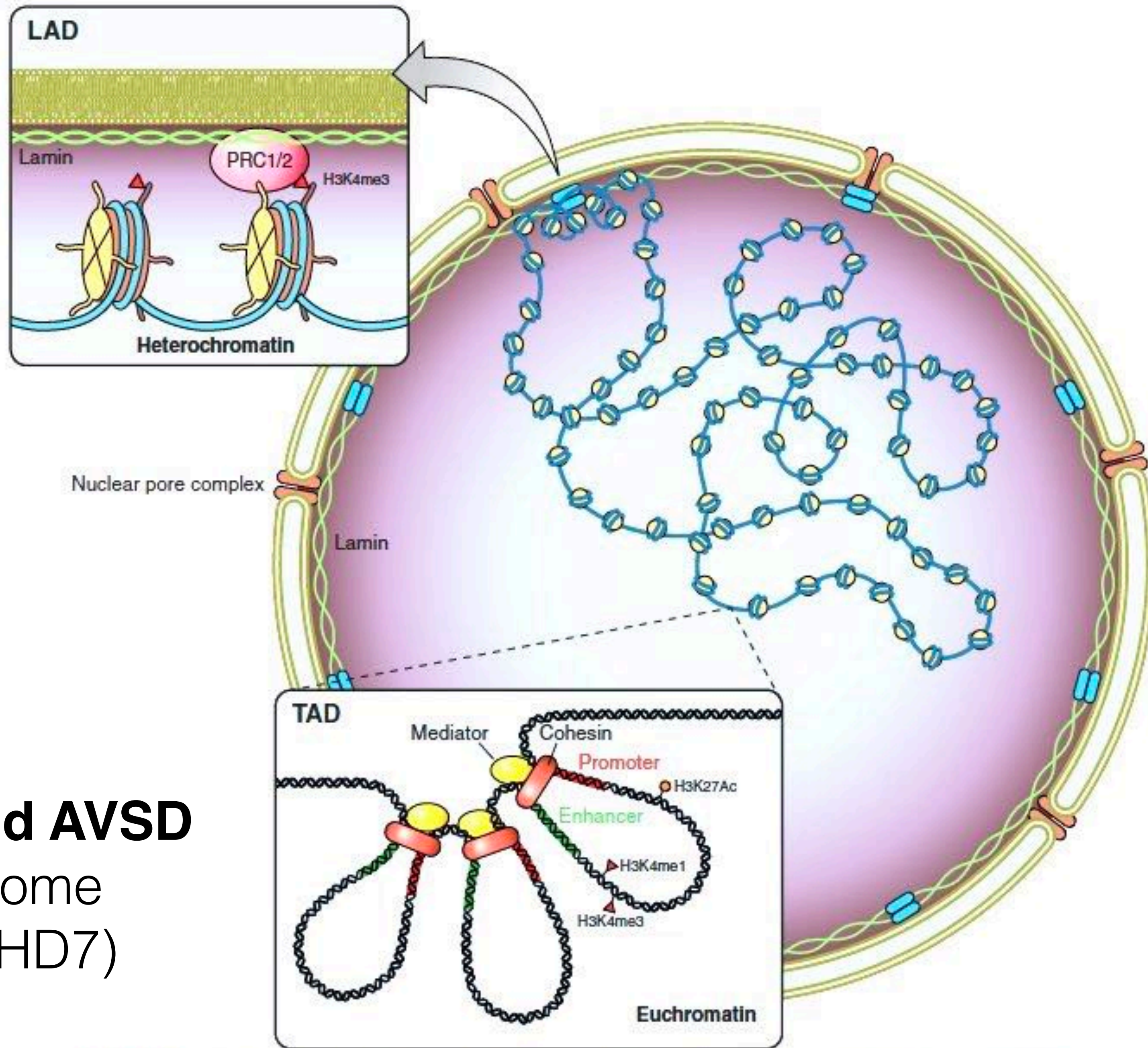
- Complete AV Canal is prevalent in patients with chromosomal imbalance
- Additional cardiac defects are prevalent in patients with:
  - chromosomal imbalance different from Trisomy 21
  - nonsyndromic AV canal

# A multigenic model for the development of CHD in trisomy 21 with effects of several genetic variants



Genomic variability of chr21 (trisomic regions) may contribute to the CHD in Down syndrome.

The CHD risk of Down syndrome is determined not only by trisomy 21 but also the genome-wide interaction of specific alleles.



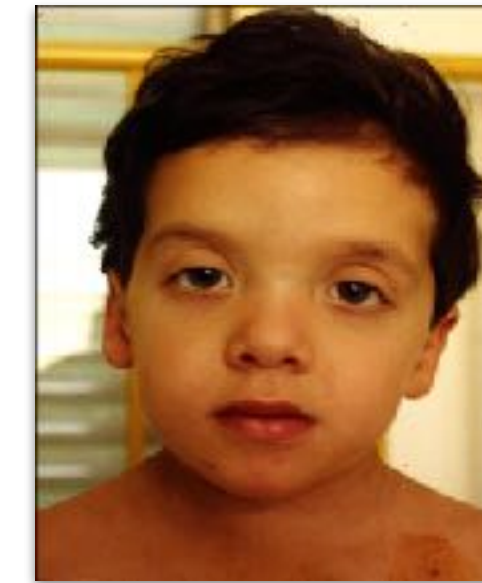# Epigenetics and AVSD

Down syndrome  
CHARGE (CHD7)

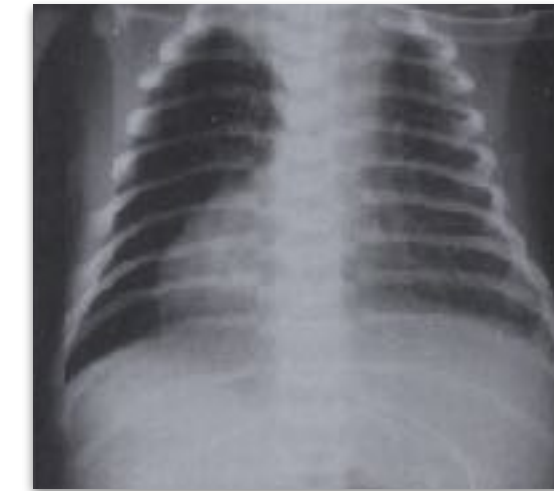**FIGURE 3.** Epigenetic components [DNA methylation, histone modifications, topological associated domains (TADs), and lamin-associated domains (LADs)] playing a role in cardiac development. PRC1/2, polycombs; NPC, nuclear pore; Me, methyl group.

# Non-Down Syndromic AV Canal

Noonan-related Syndromes



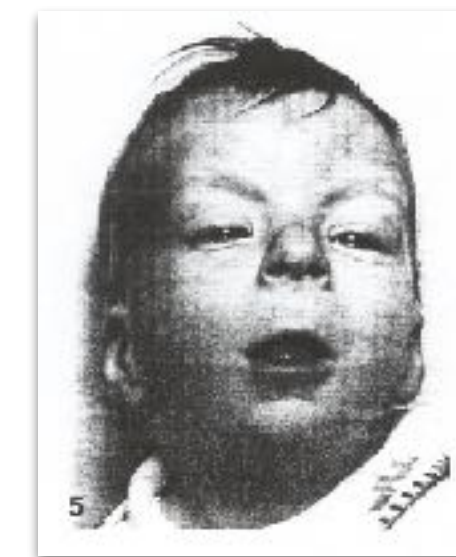Heterotaxy



del8p23 Syndrome



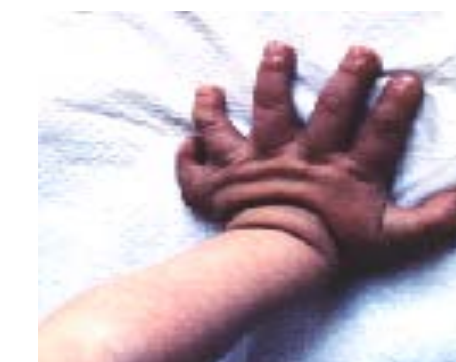del3p25 Syndrome

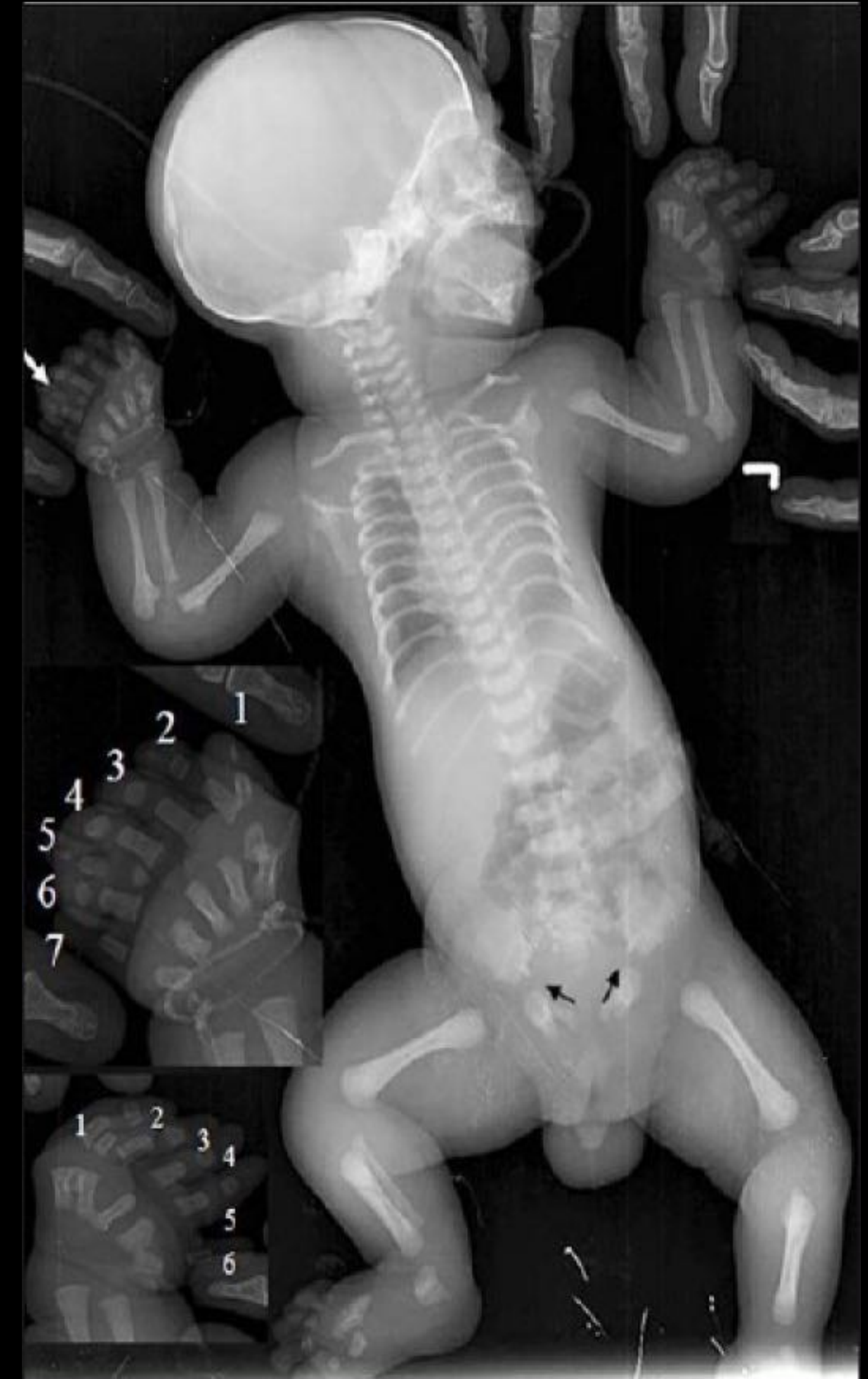
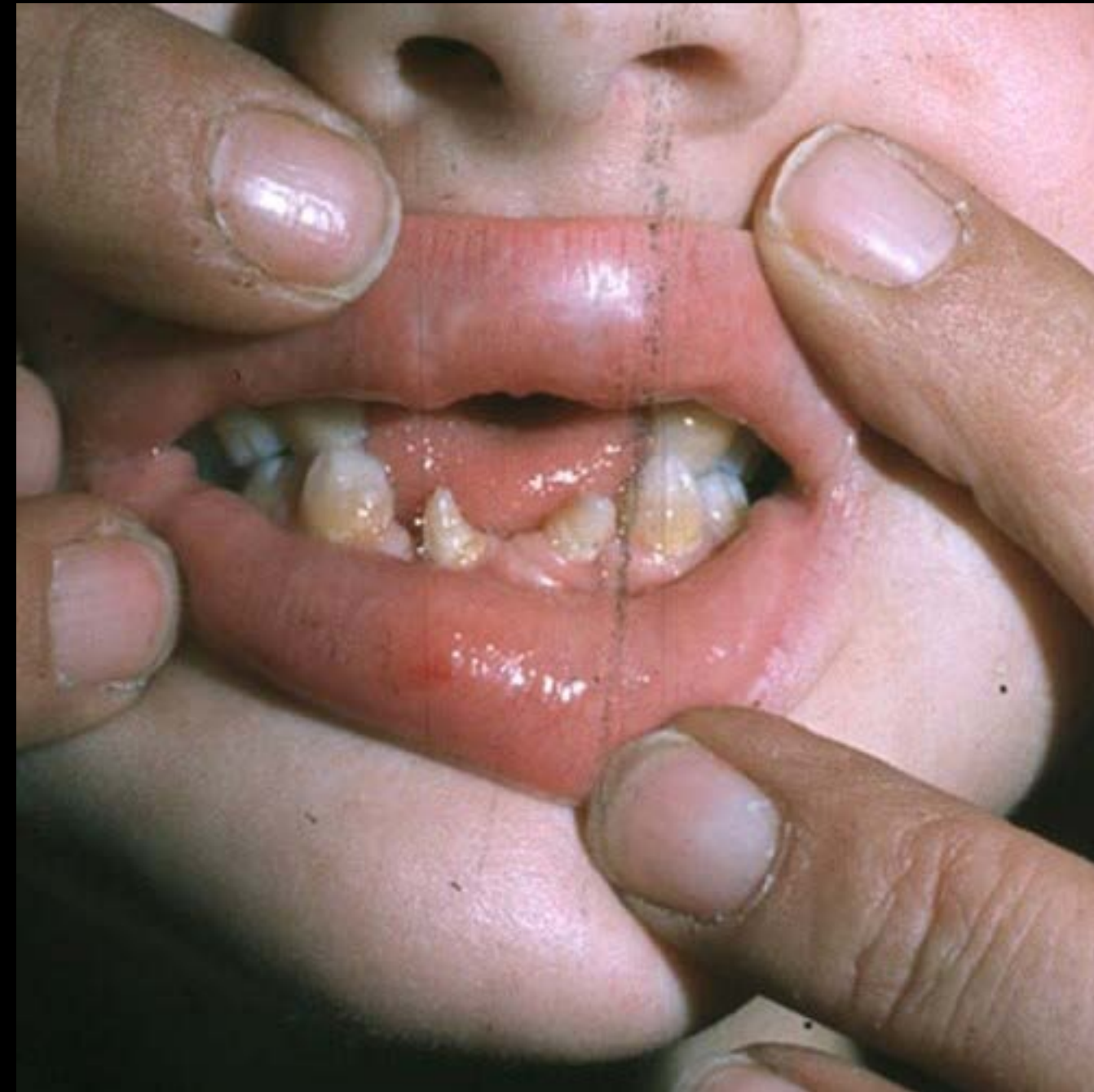
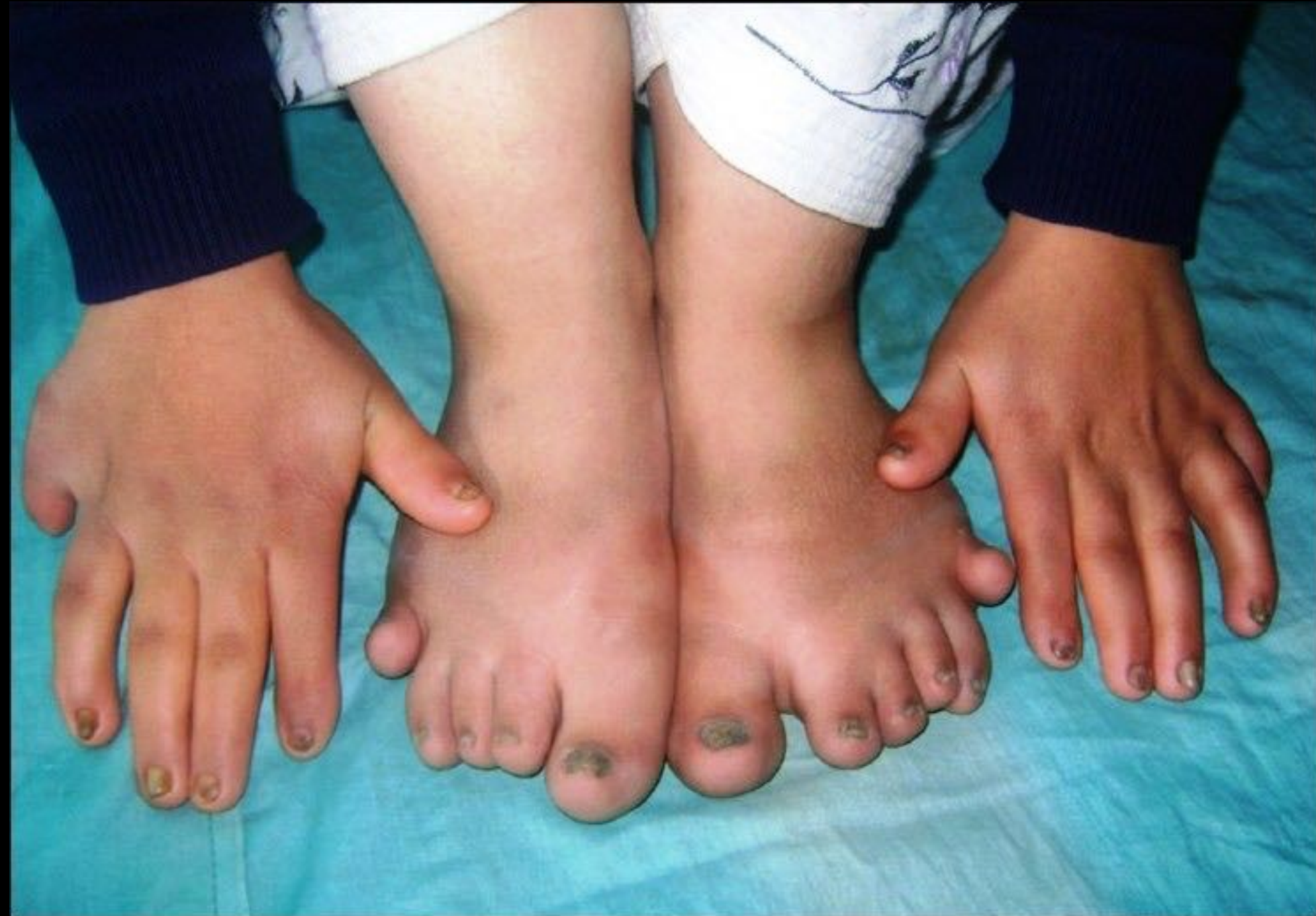CHARGE-VACTERL Syndromes



Polydactyly Syndromes

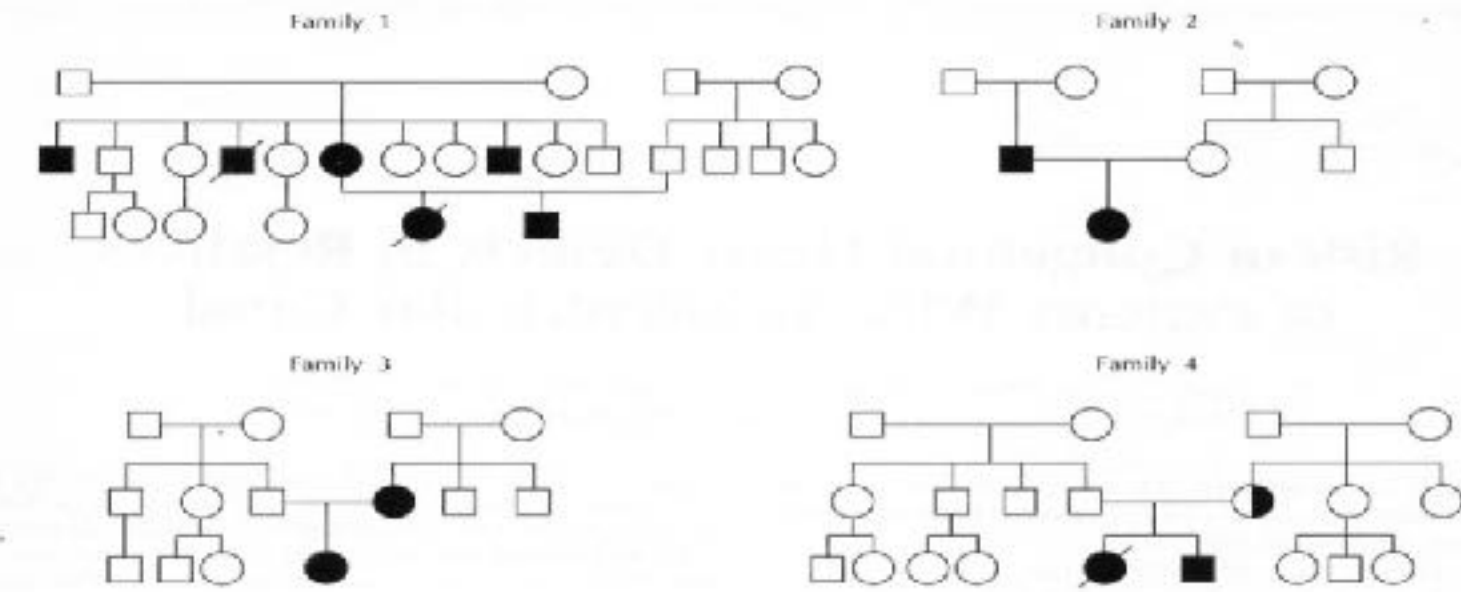




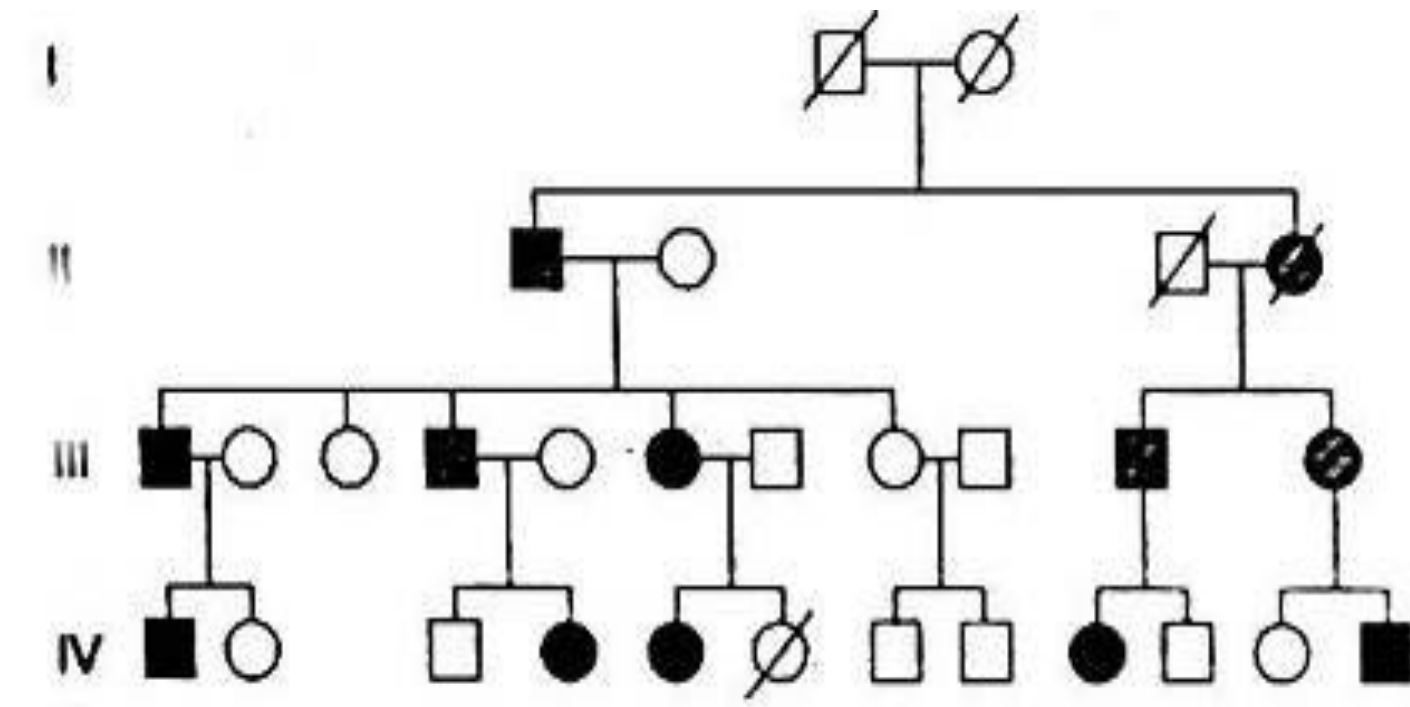
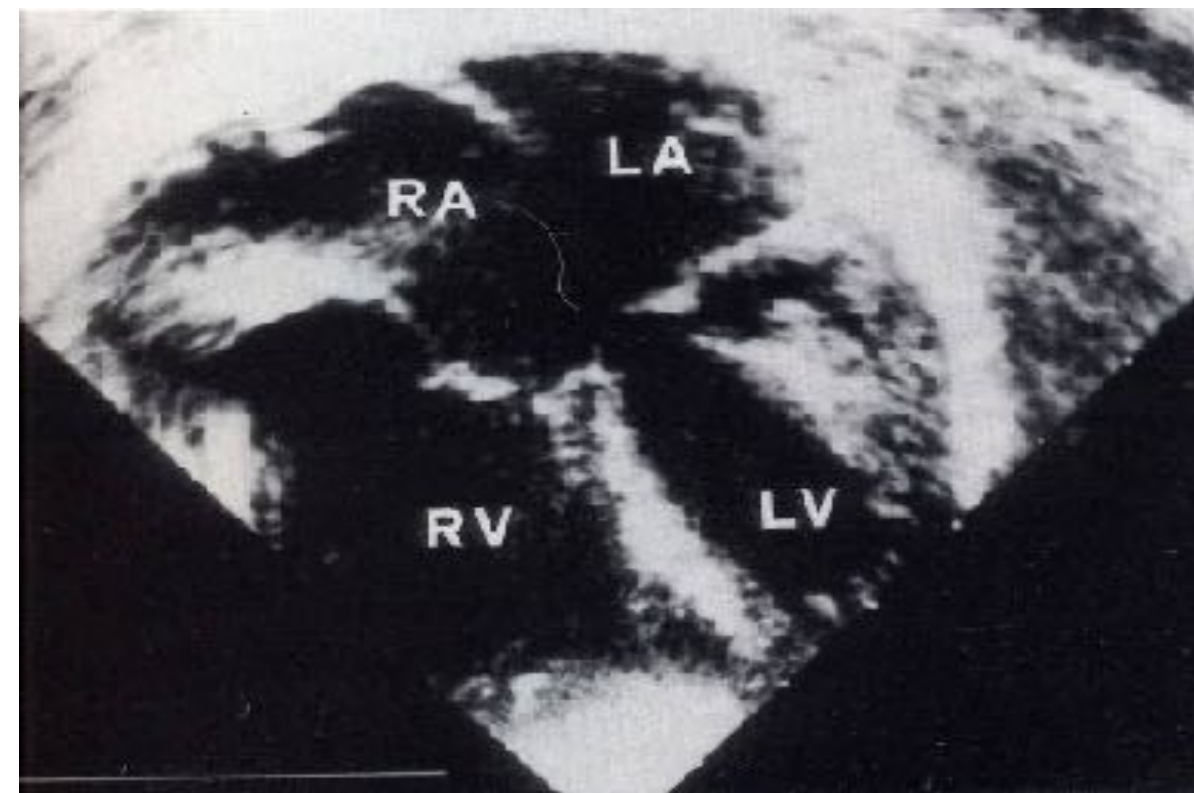
# Non-syndromic AV Canal

## Risk of Congenital Heart Defects in Relatives of Patients With Atrioventricular Canal

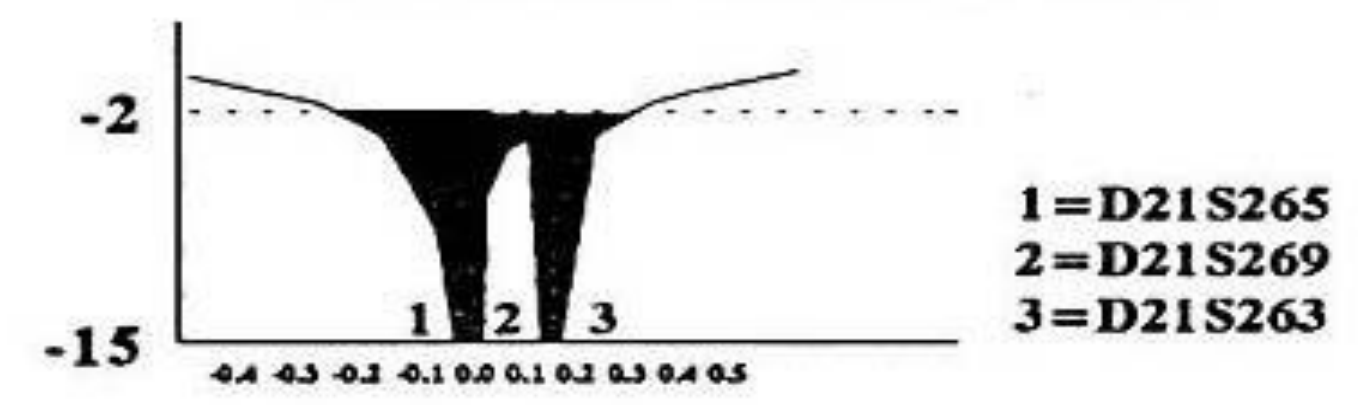
Maria Cristina Digilio, MD; Bruno Marino, MD; Maria Paola Cicini, MD;  
Aldo Giannotti, MD; Roberto Formigari, MD; Bruno Dallapiccola, MD



AJDC 1993;147:1295-1297



Multipoint linkage analysis between three markers of chromosome 21

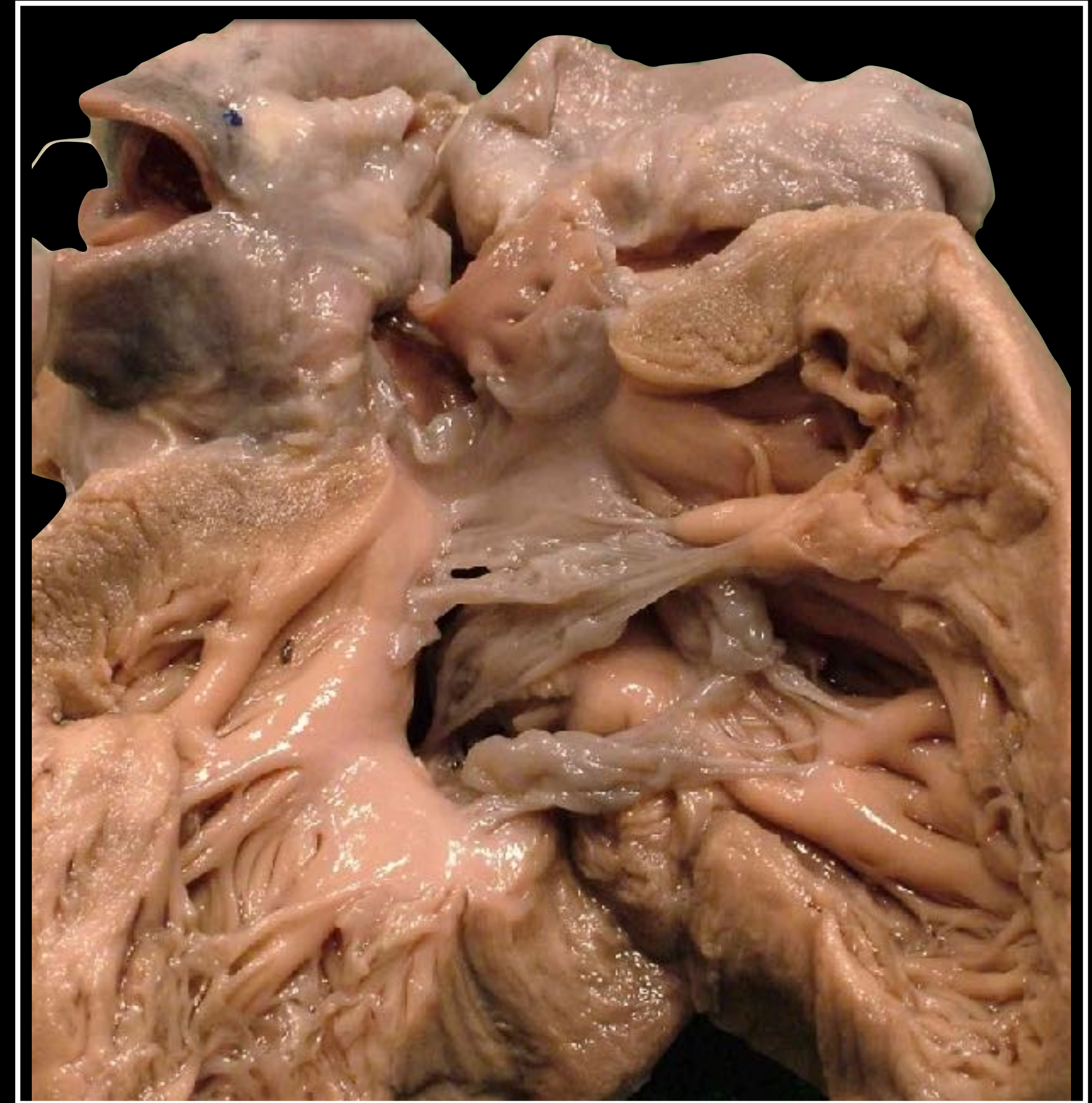
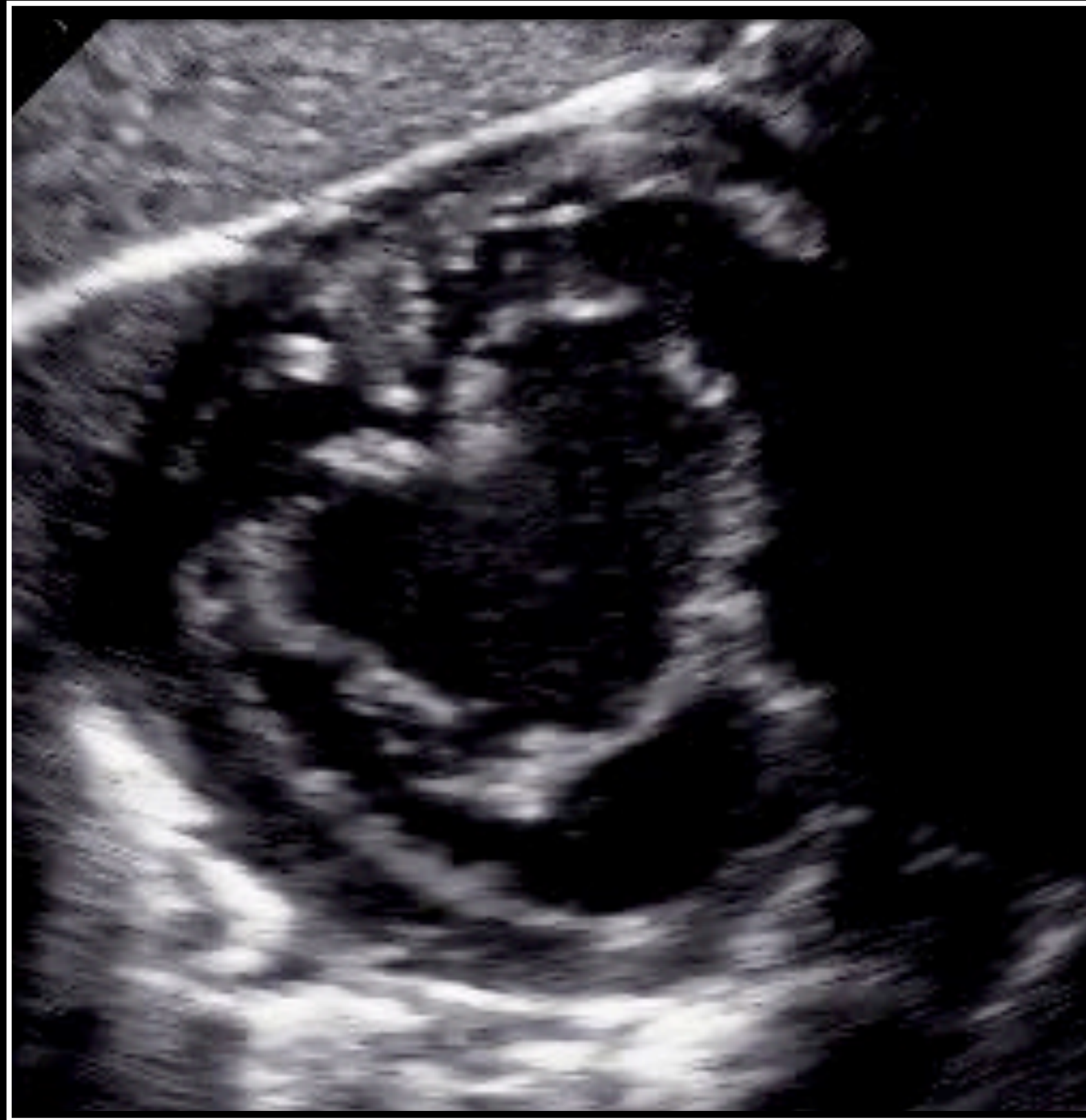

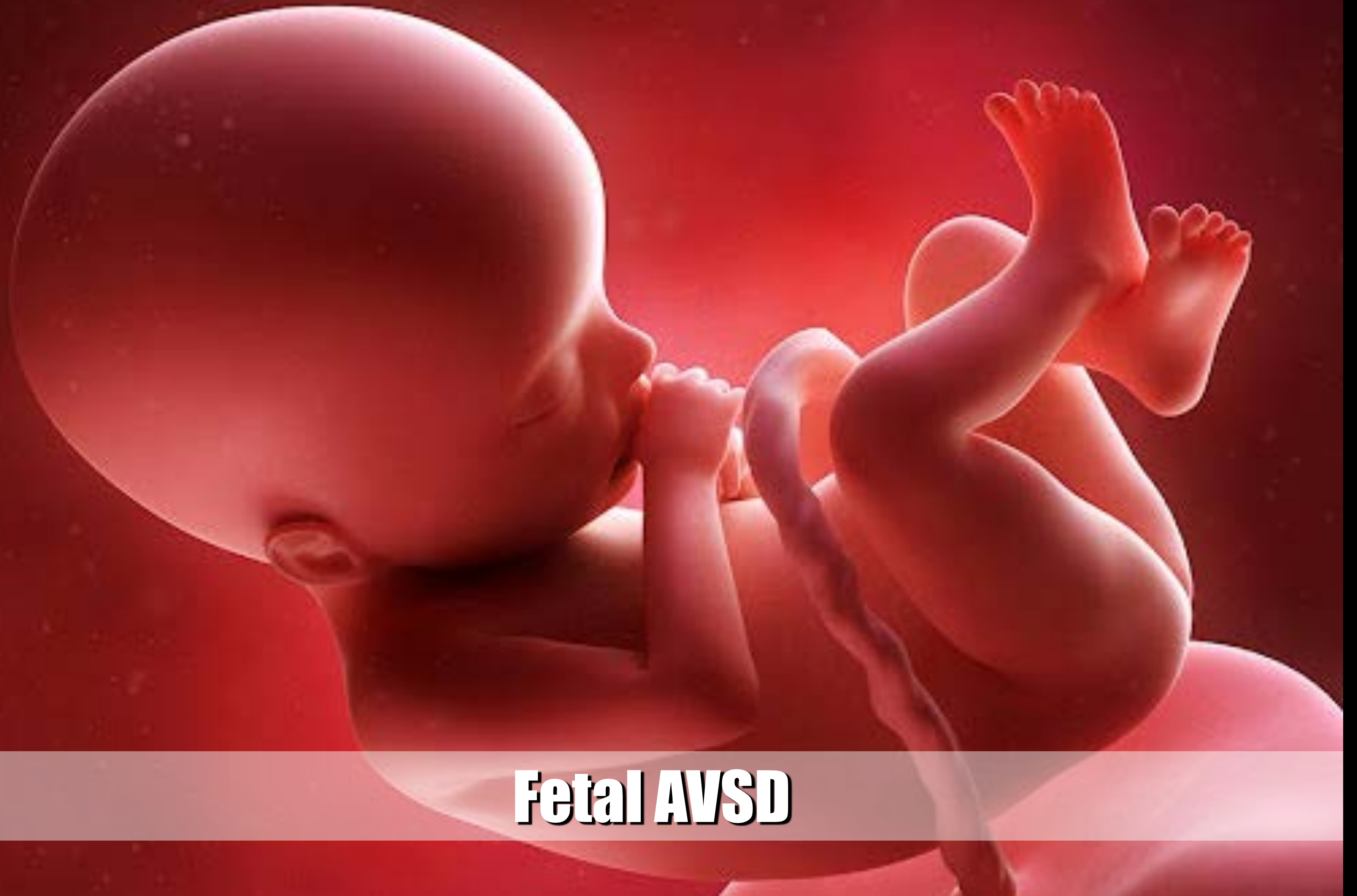Massimo Gennarelli · Giuseppe Novelli  
Maria Cristina Digilio · Aldo Giannotti · Bruno Marino  
Bruno Dallapiccola

**Exclusion of linkage with chromosome 21  
in families with recurrence  
of non-Down's atrioventricular canal**

Hum Genet 1994; 94: 708

# AVSD - Echocardiography

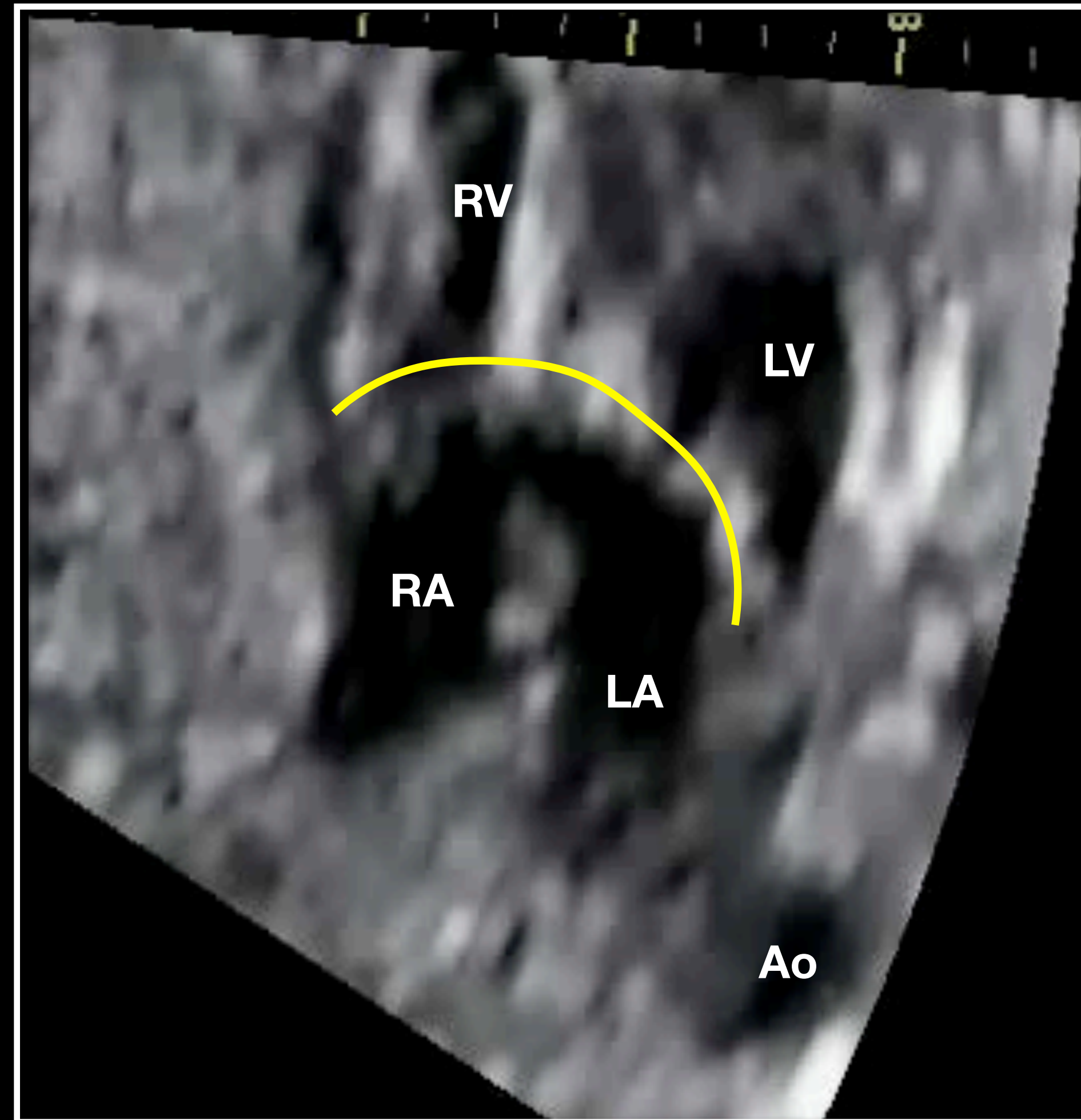


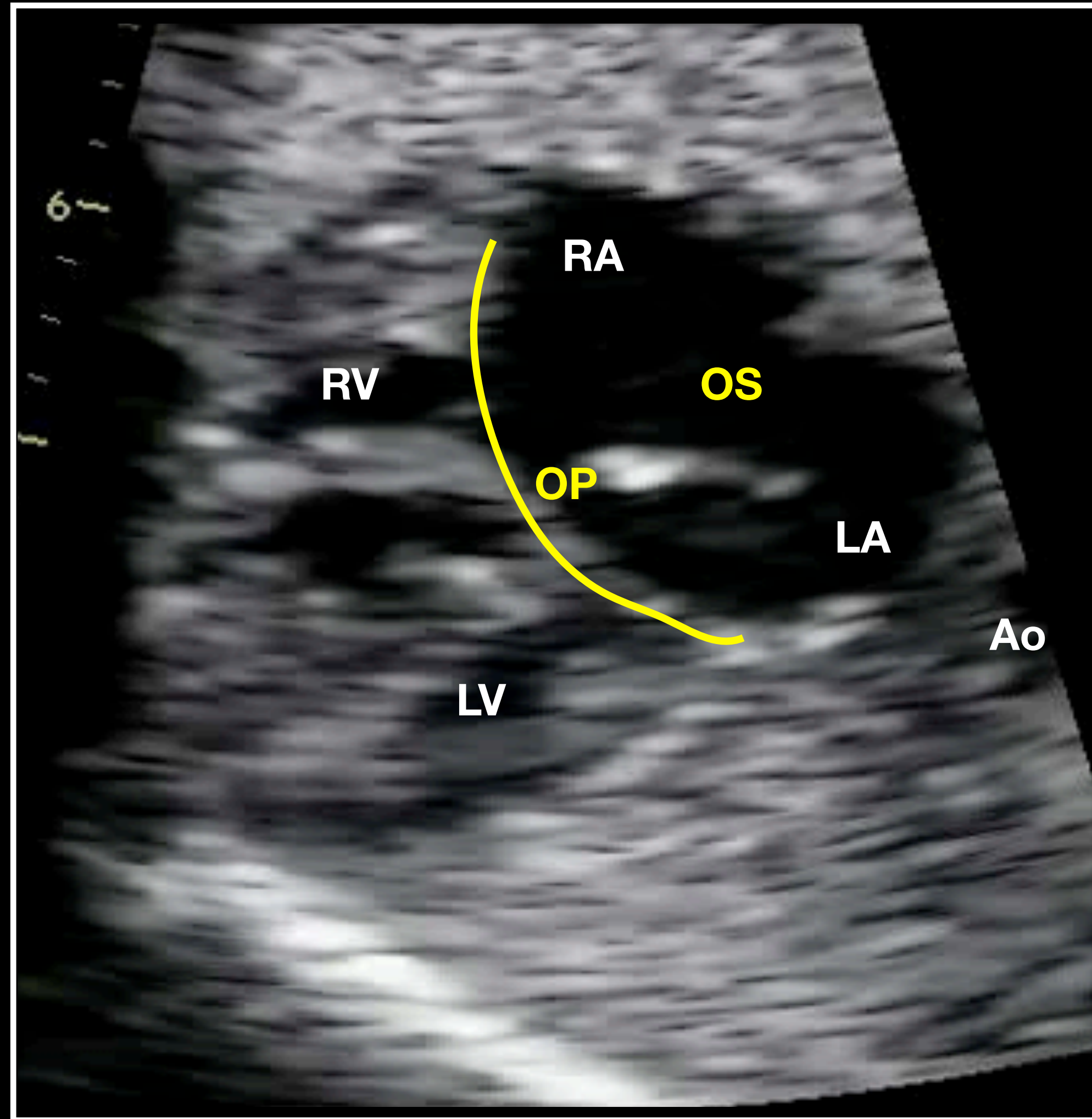


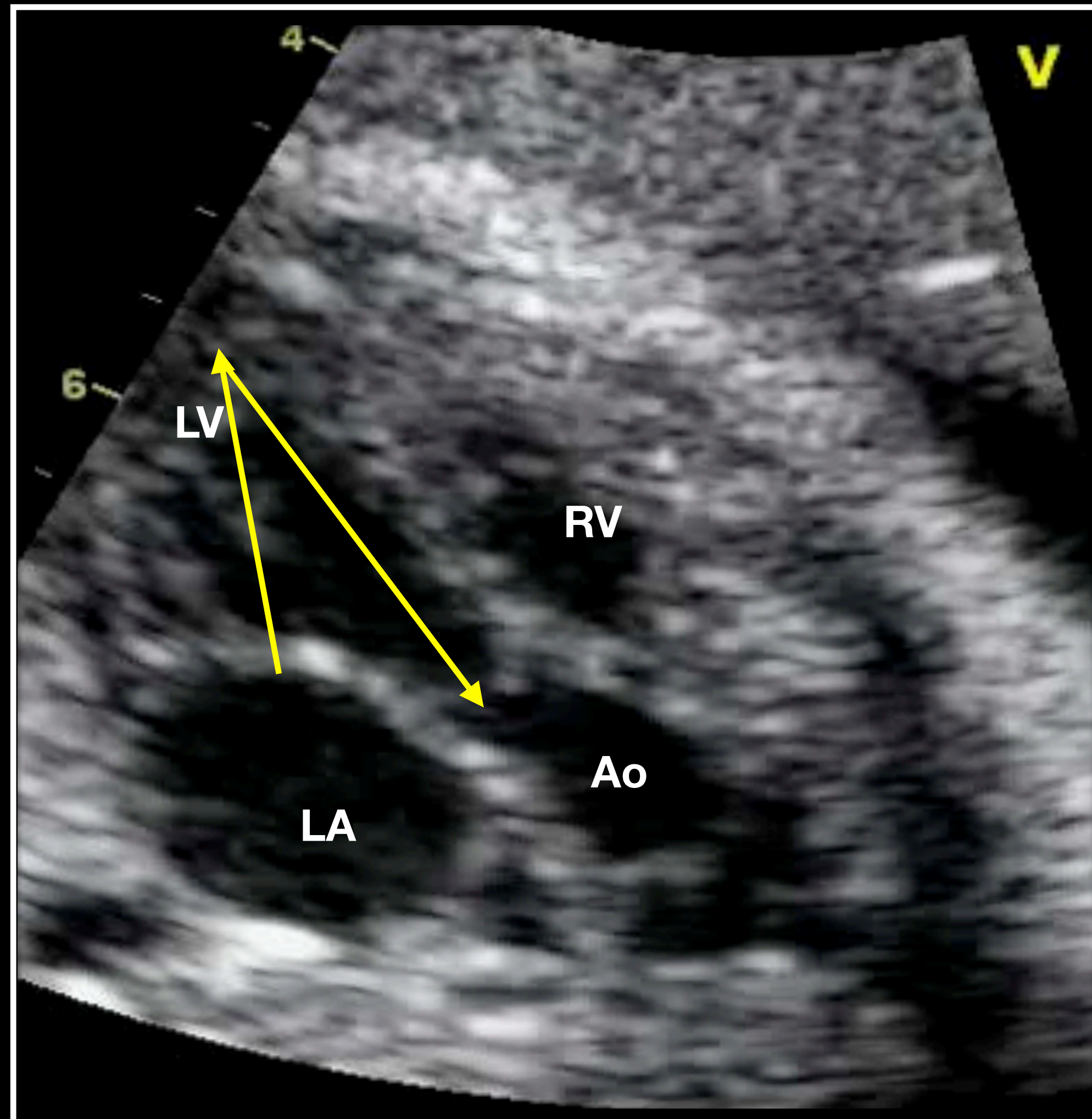
**Fetal AVSD**



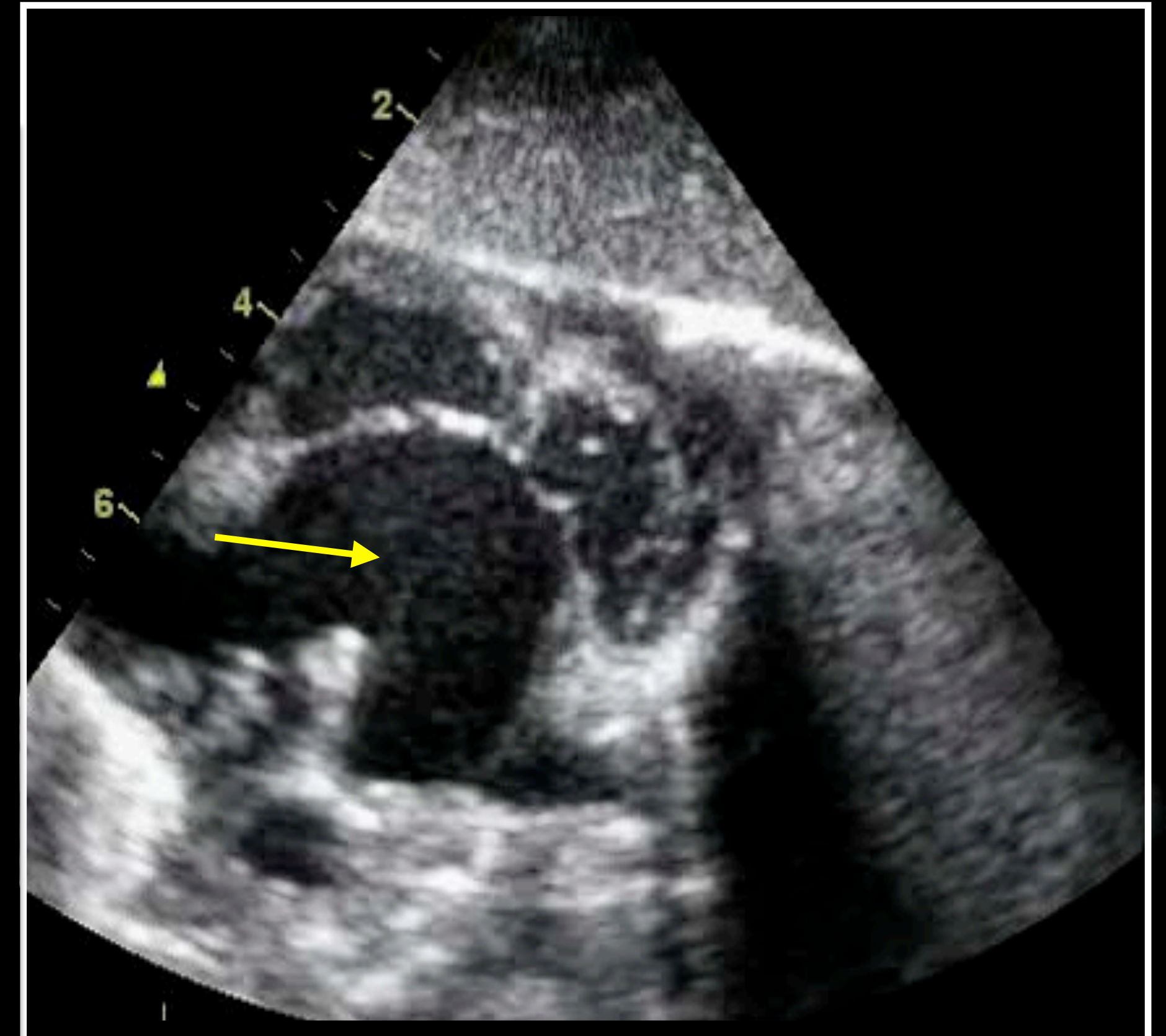
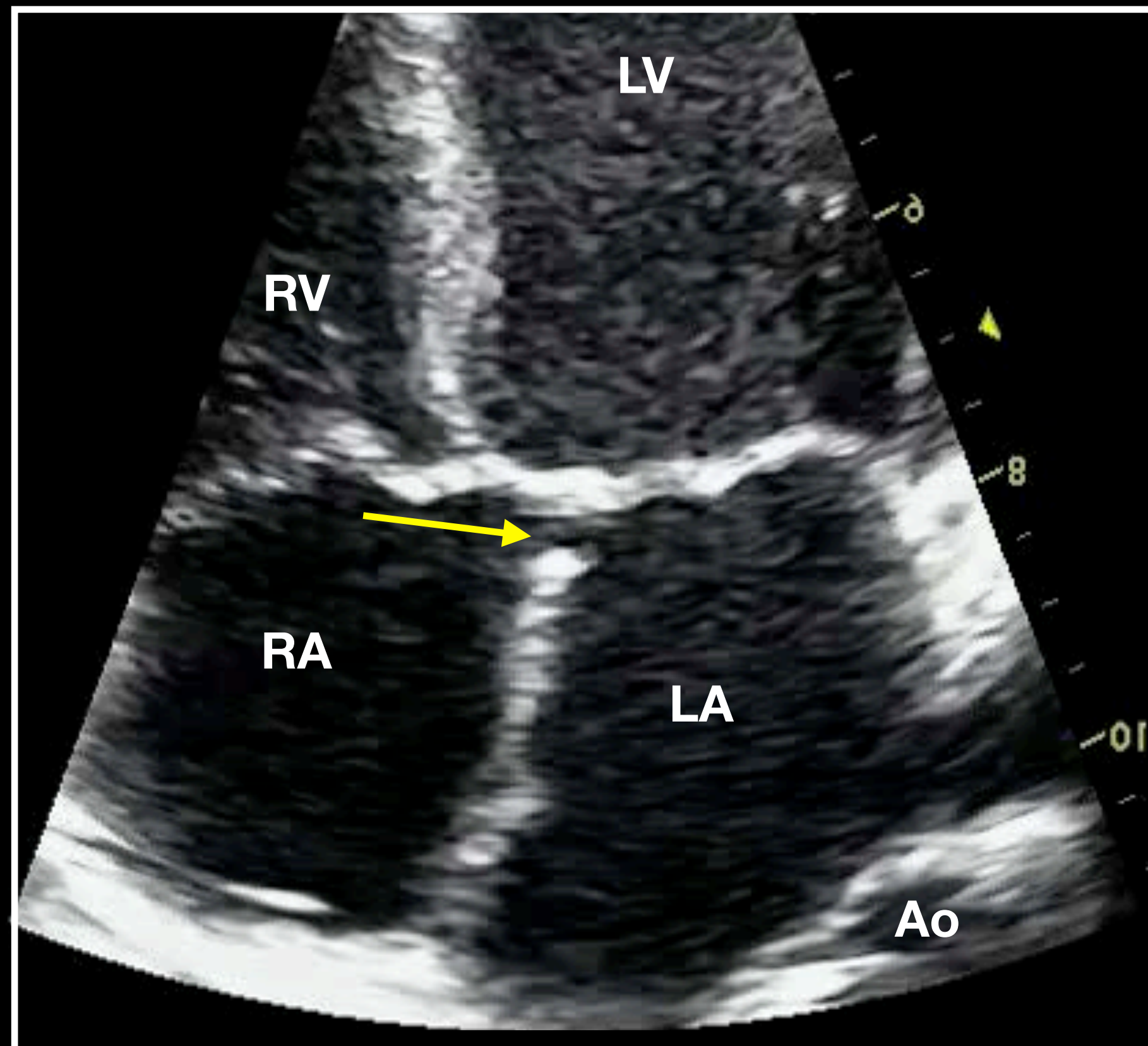
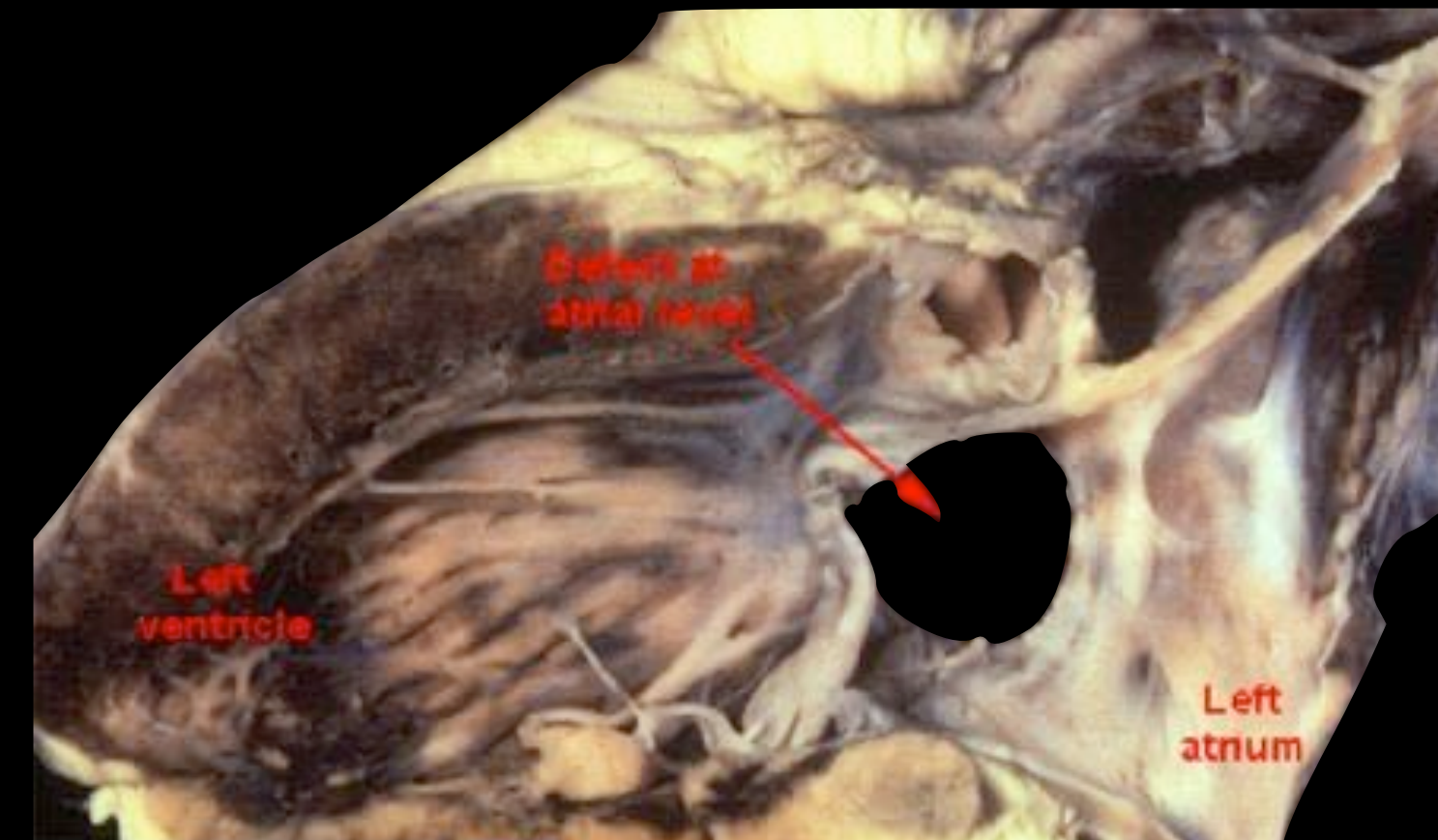
# Fetus 18 WG



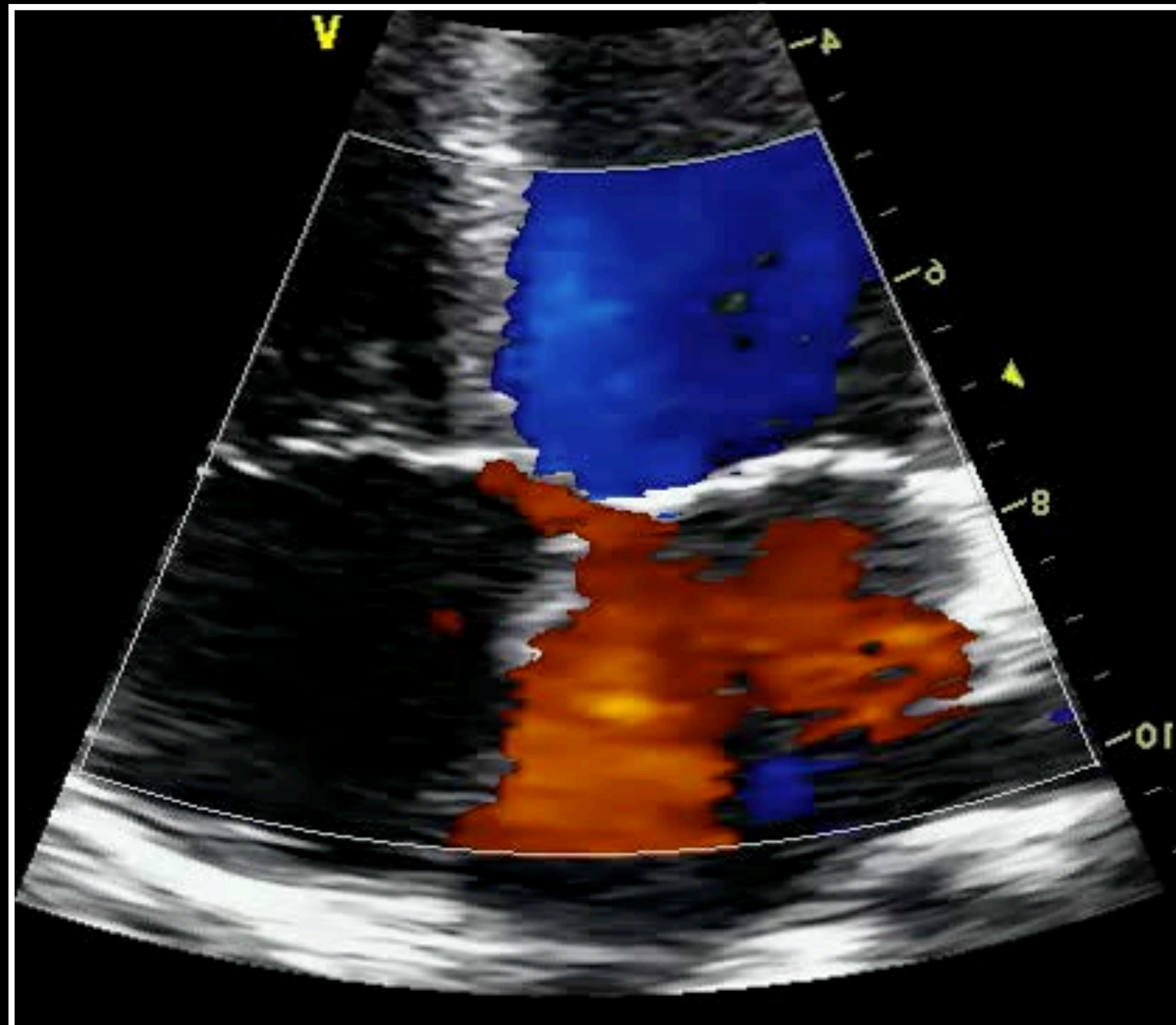




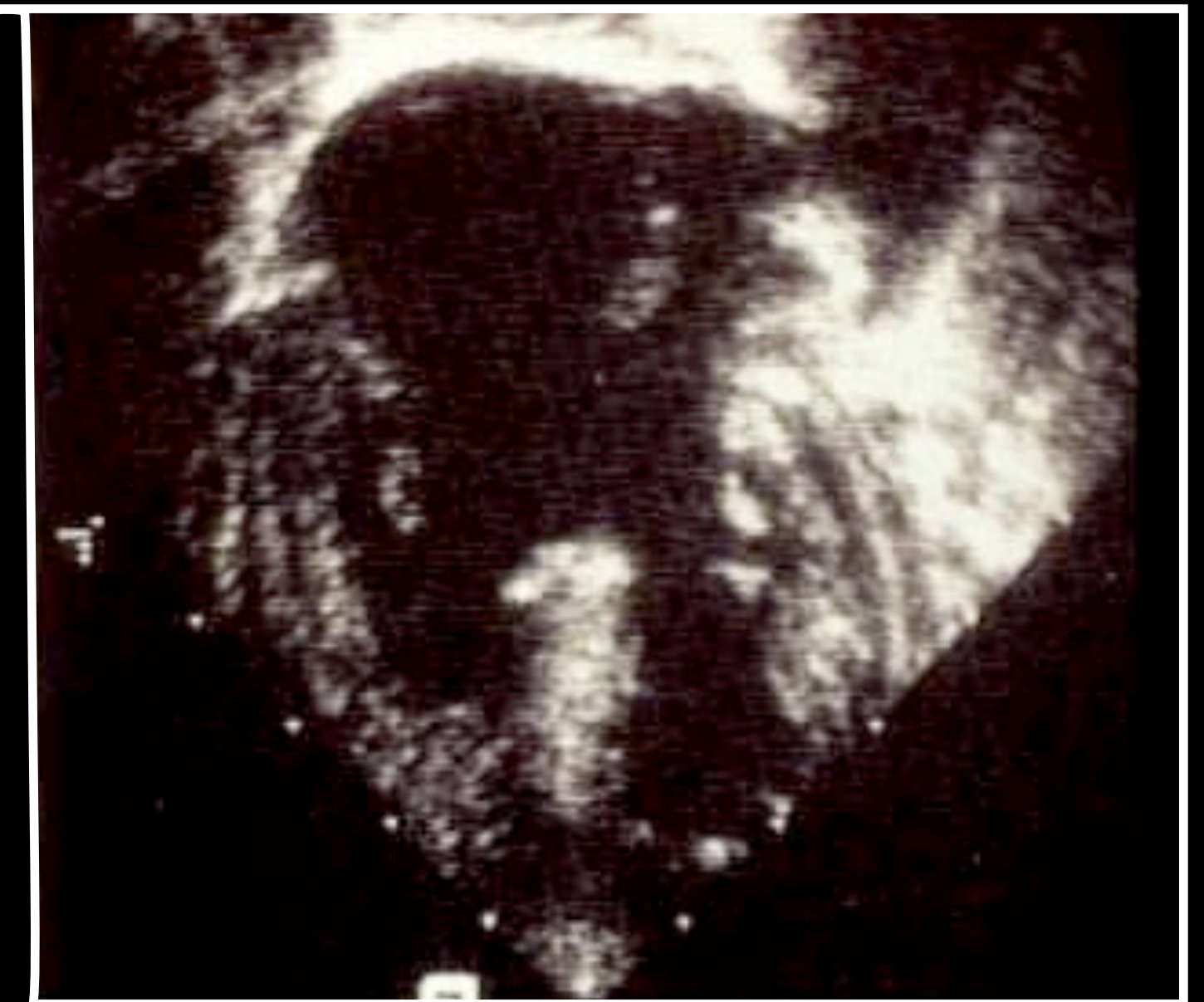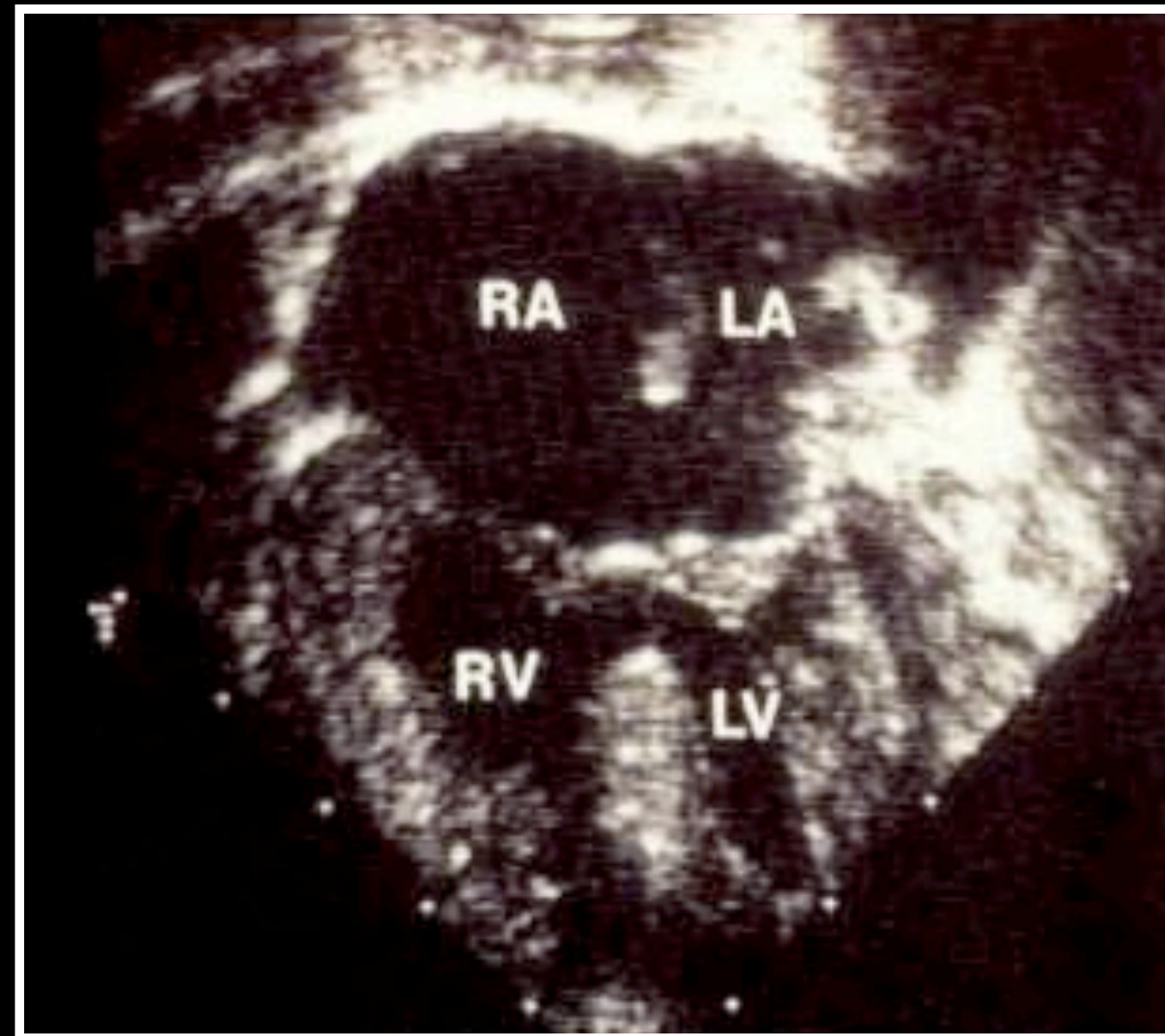
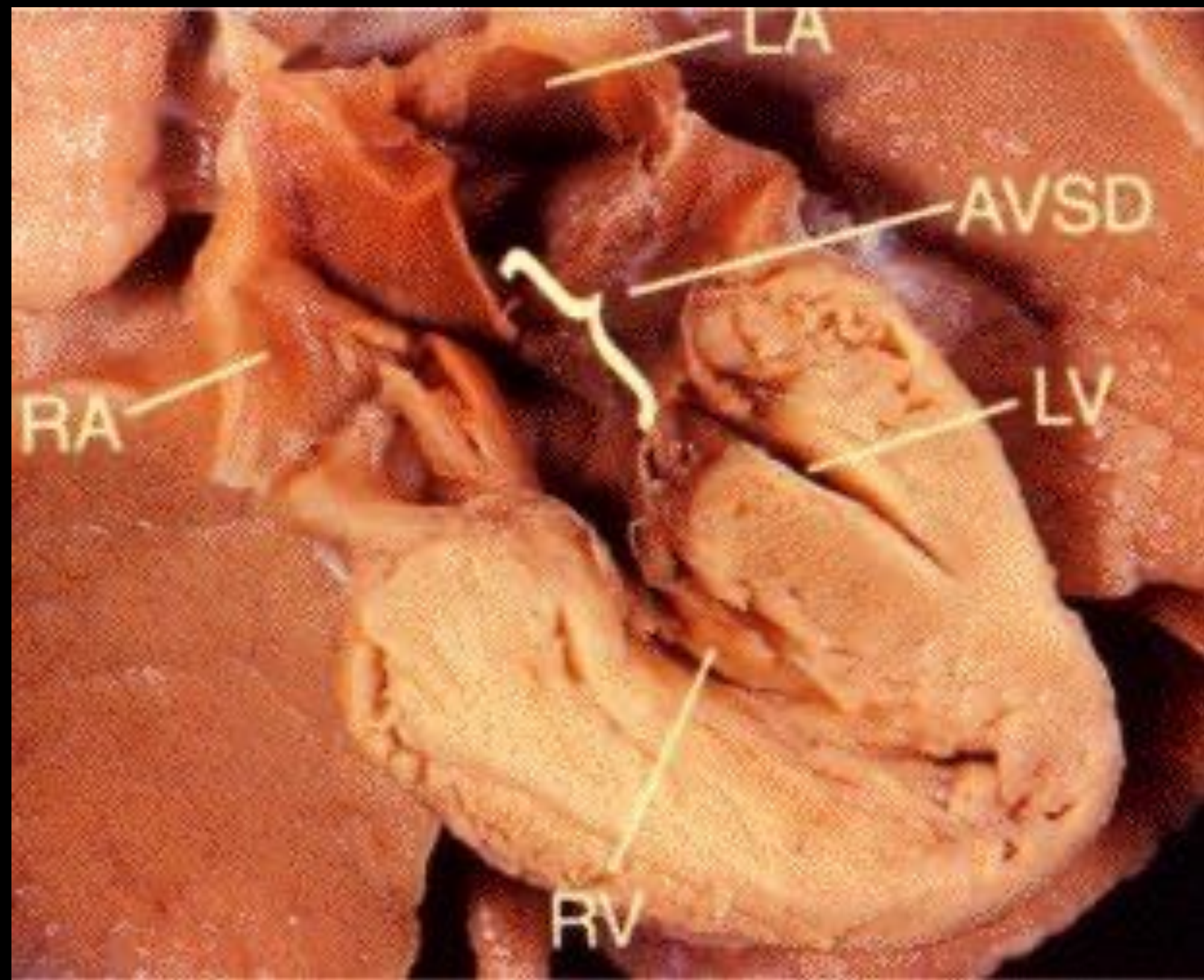
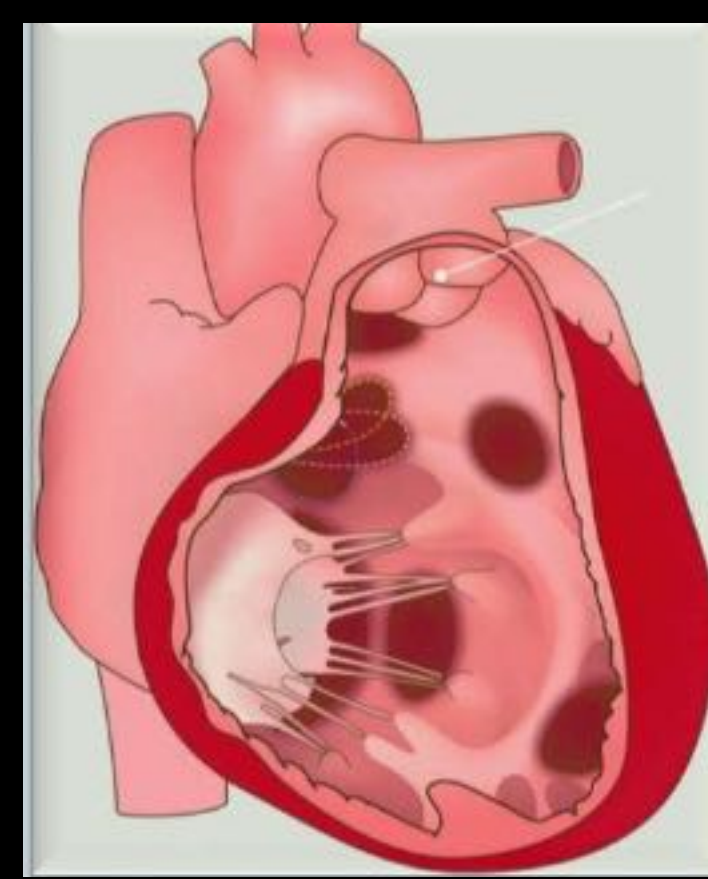
# Ostium primum



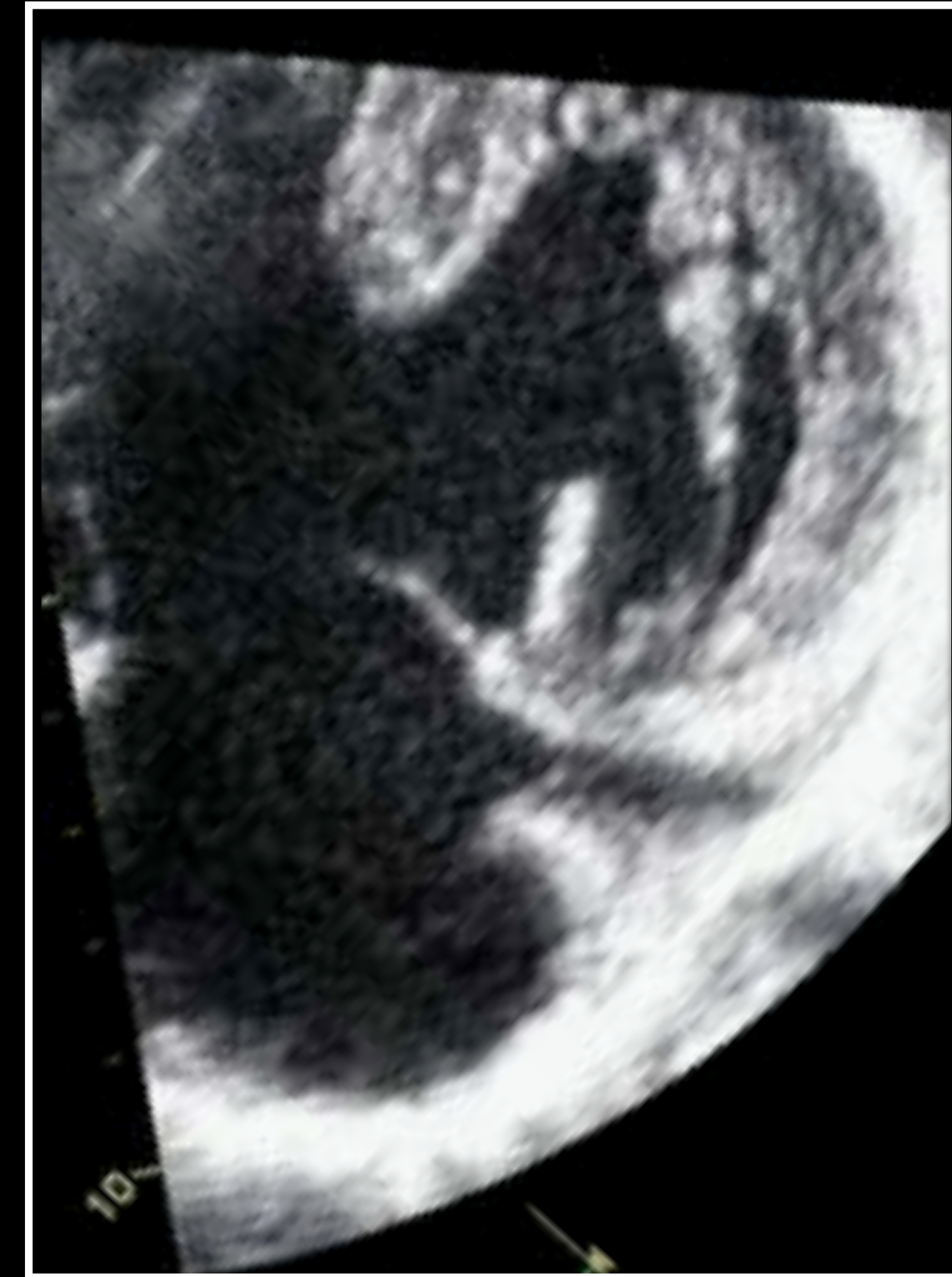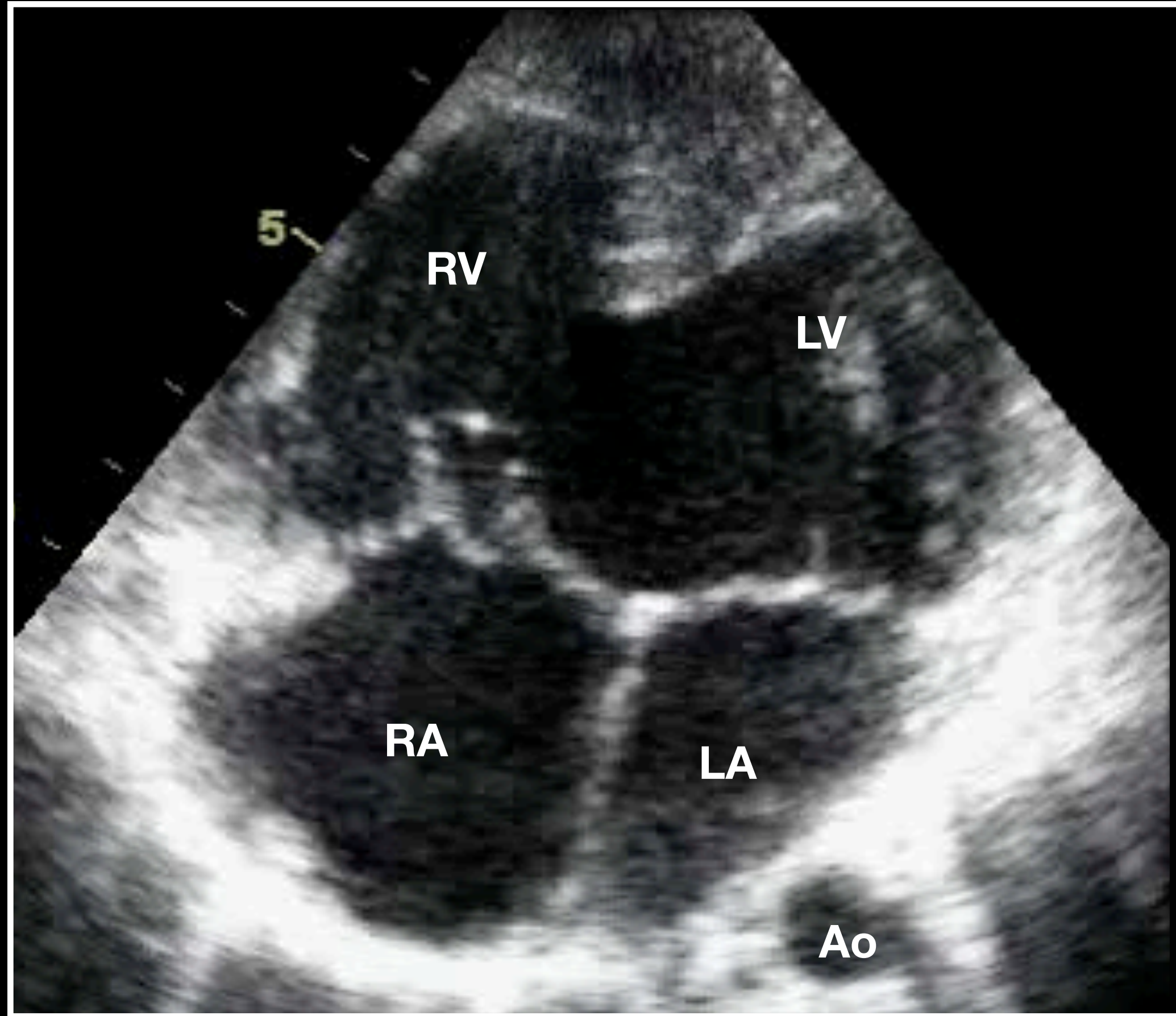
# Ostium primum small



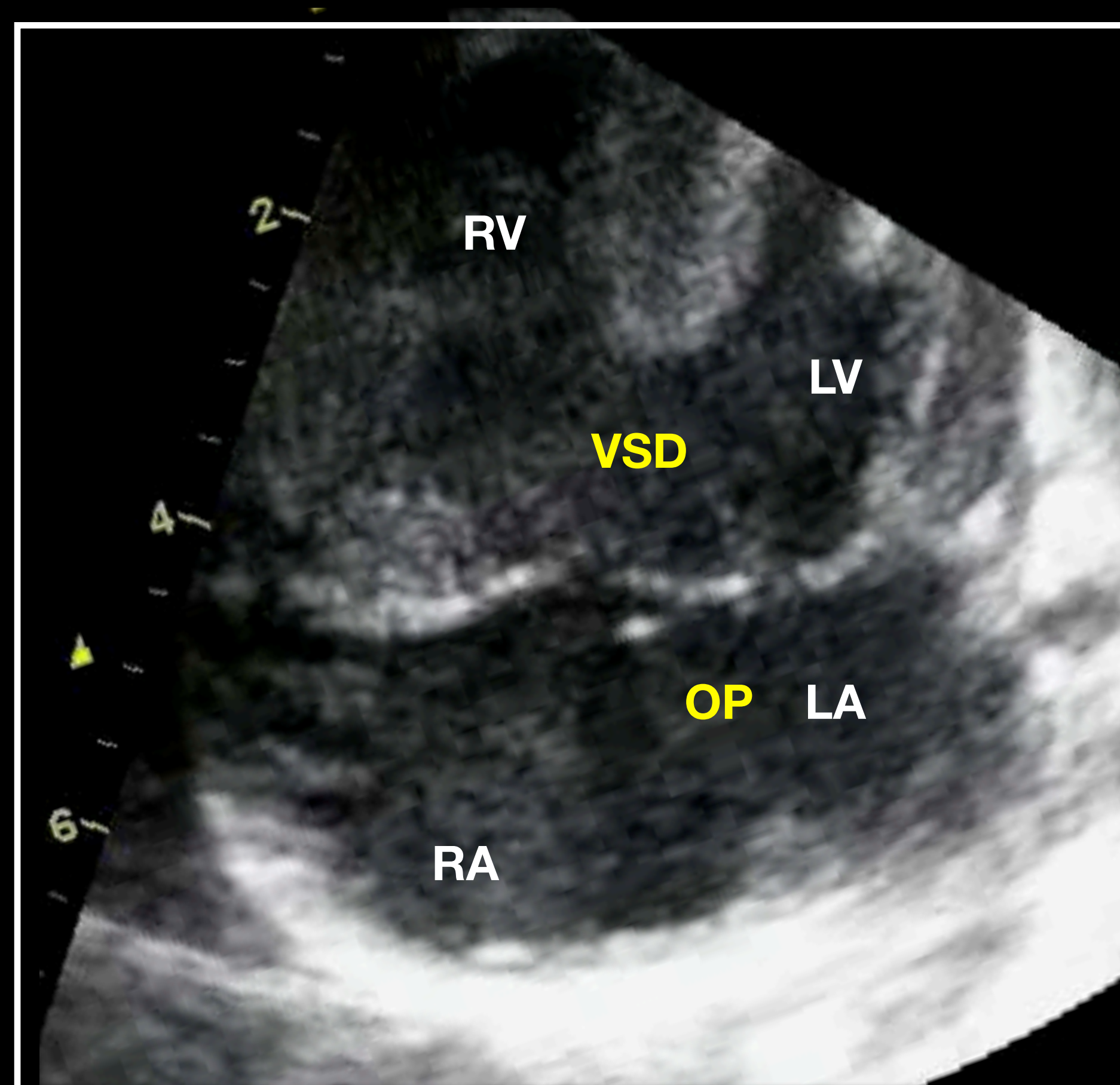
# VSD in AVSD



# Inlet VSD

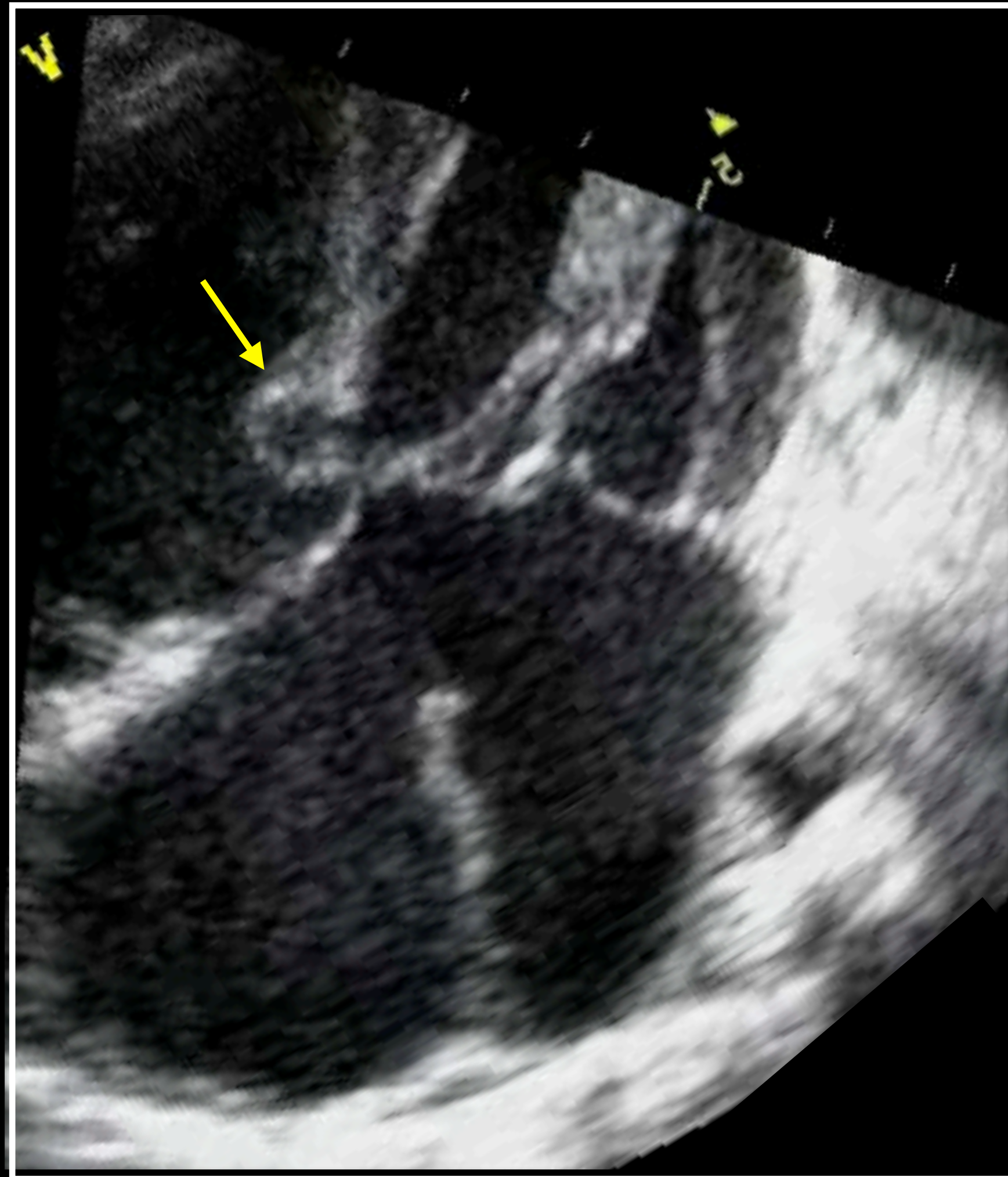


# Complete AVSD

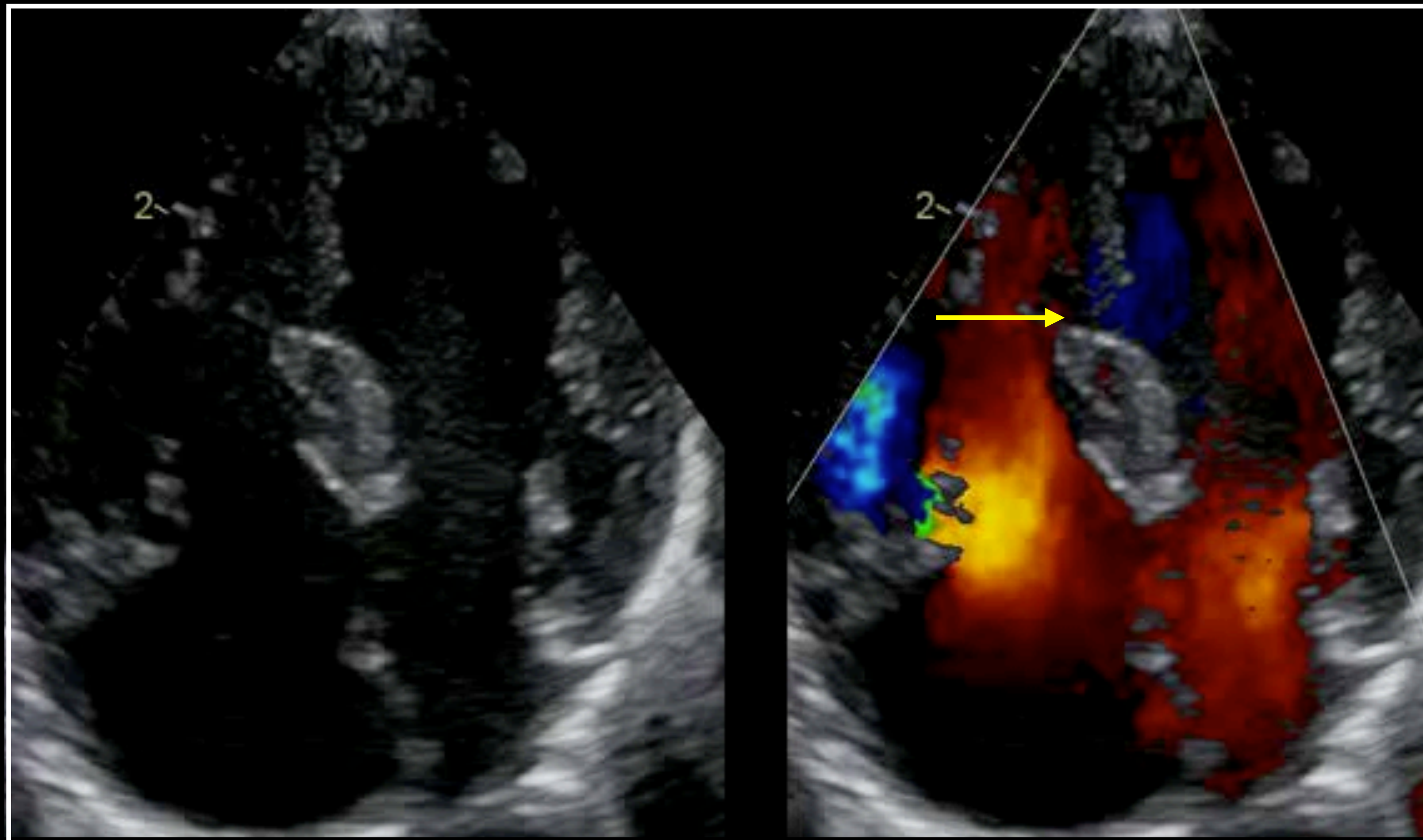




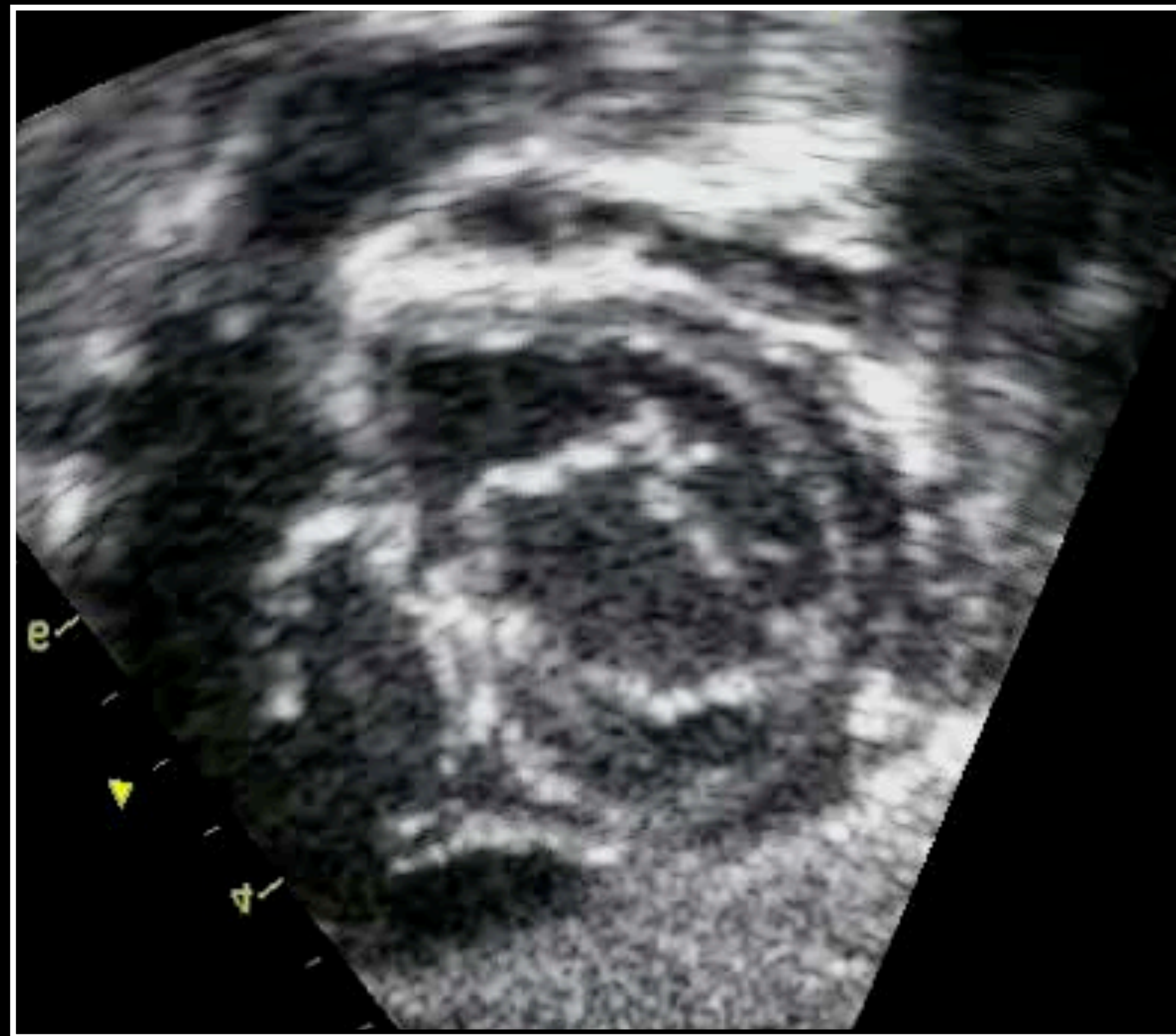
# Complete AVSD with restrictive VSD



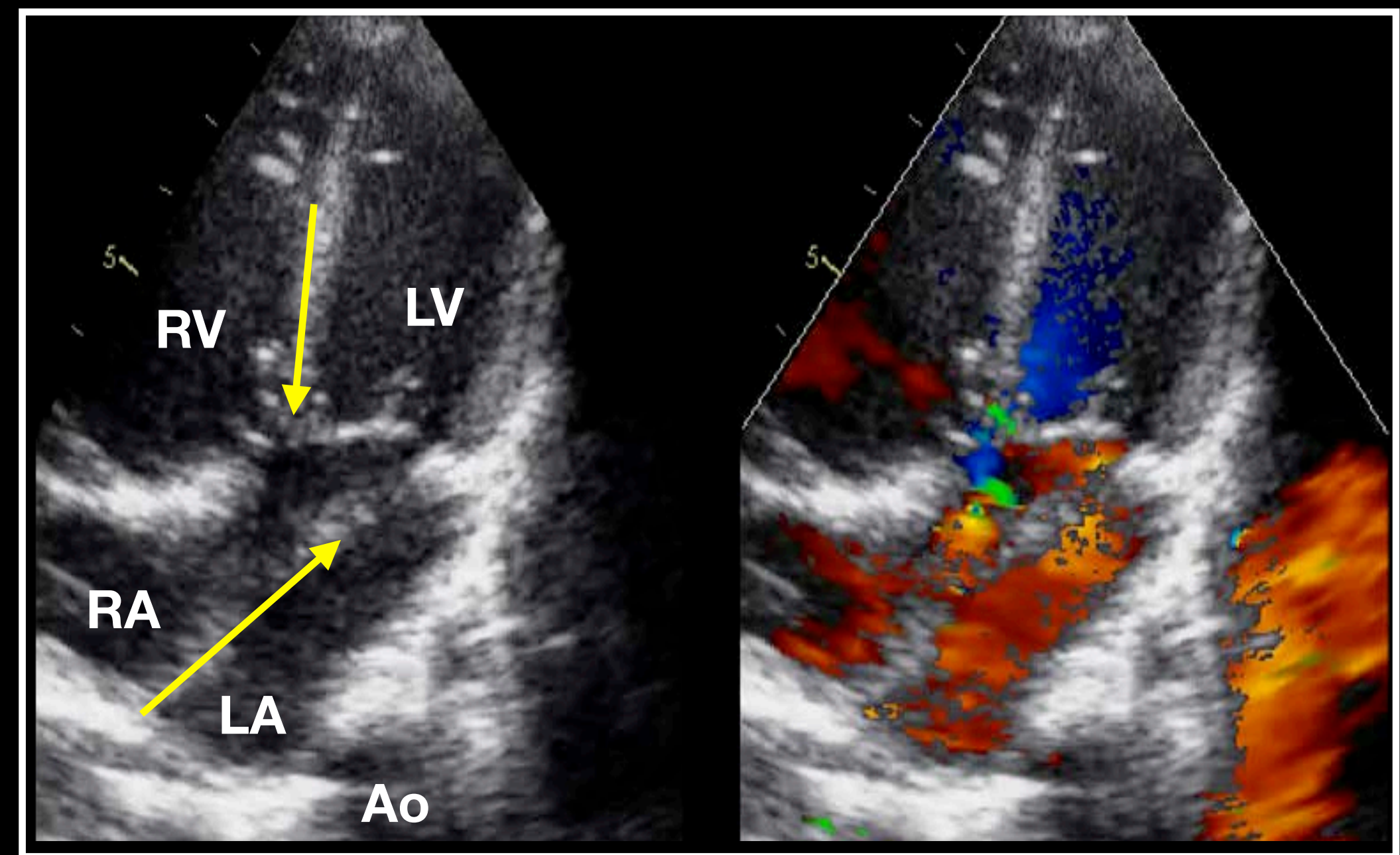
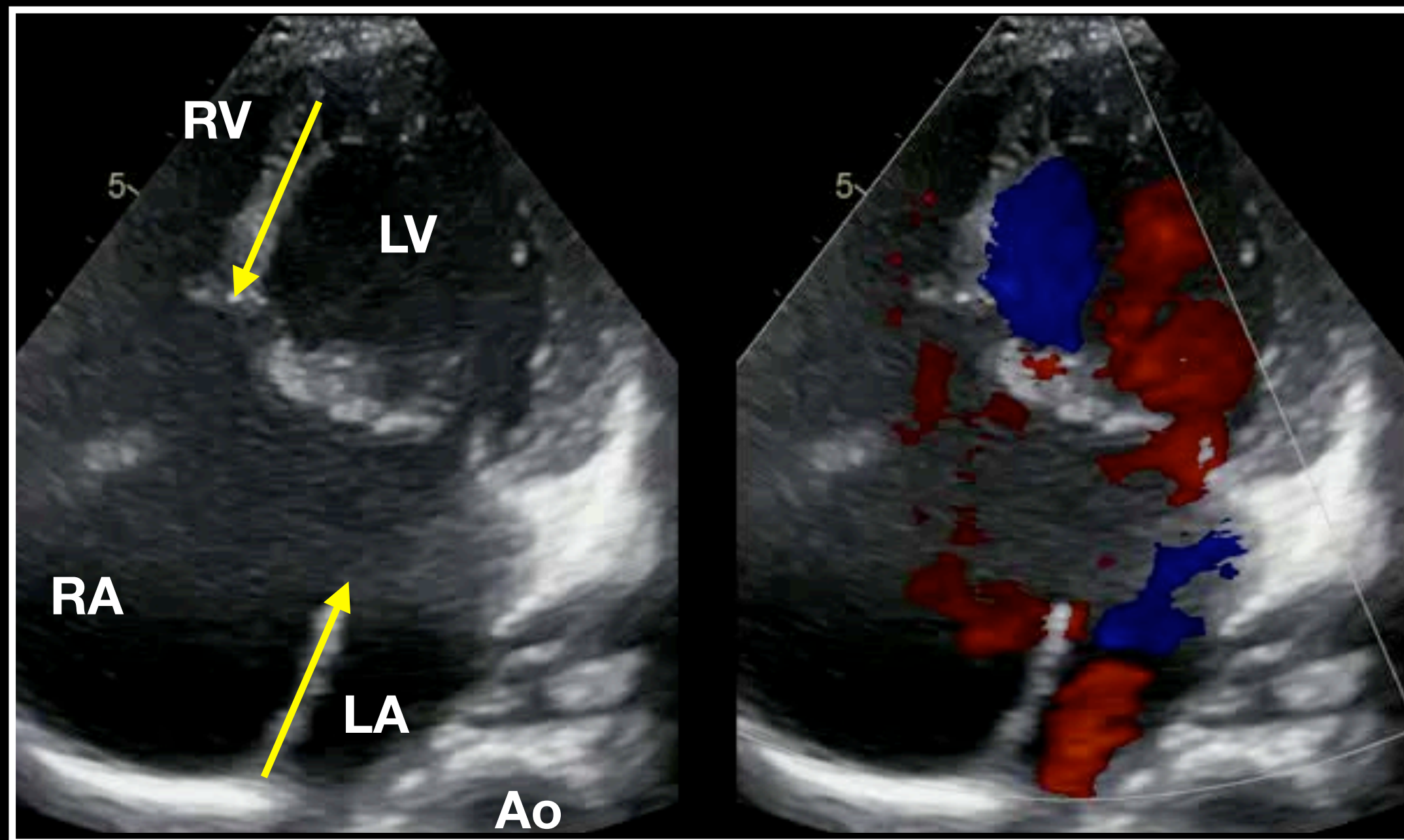
# Muscular VSD in AVSD



# Ventricles in AVSD

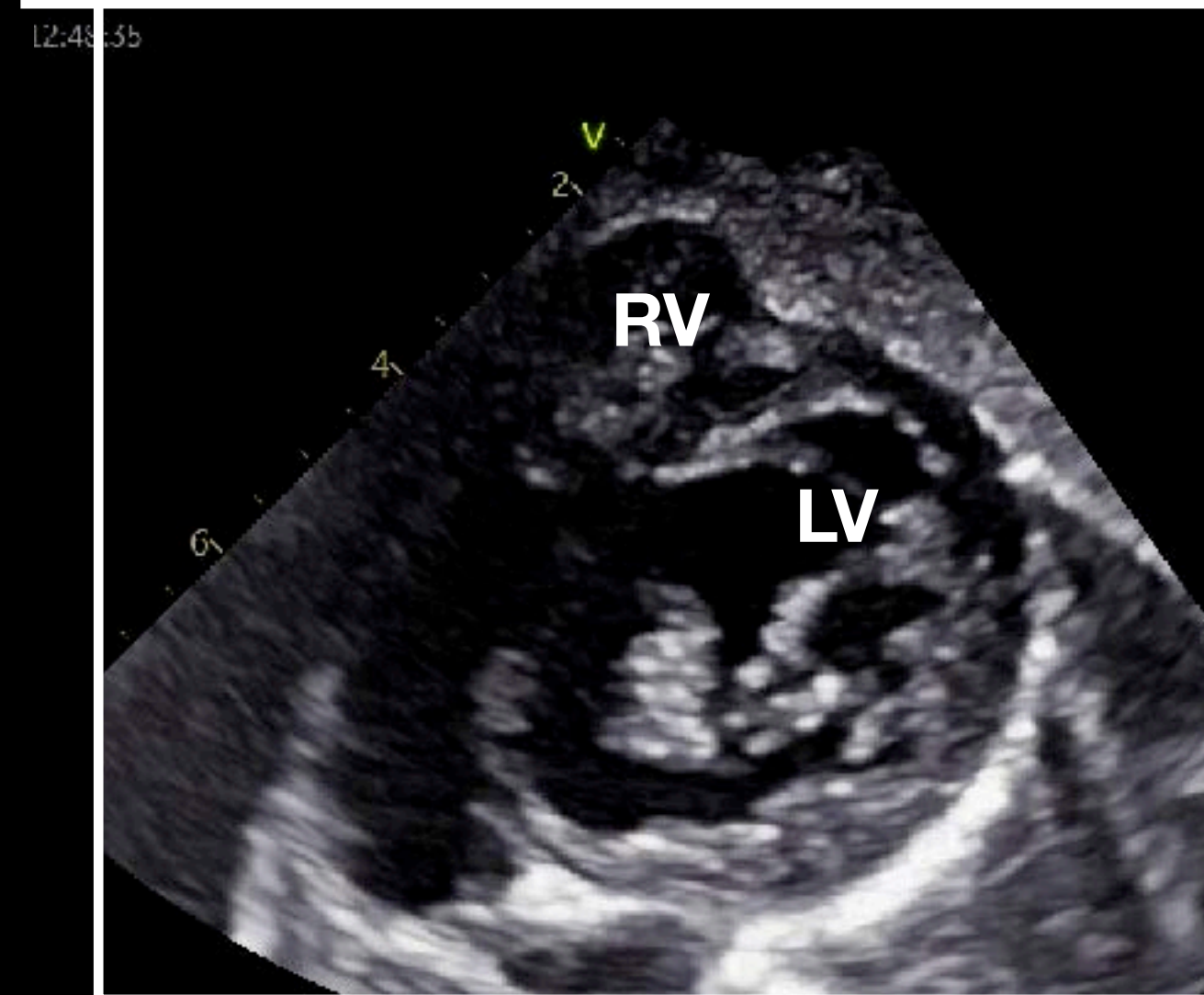
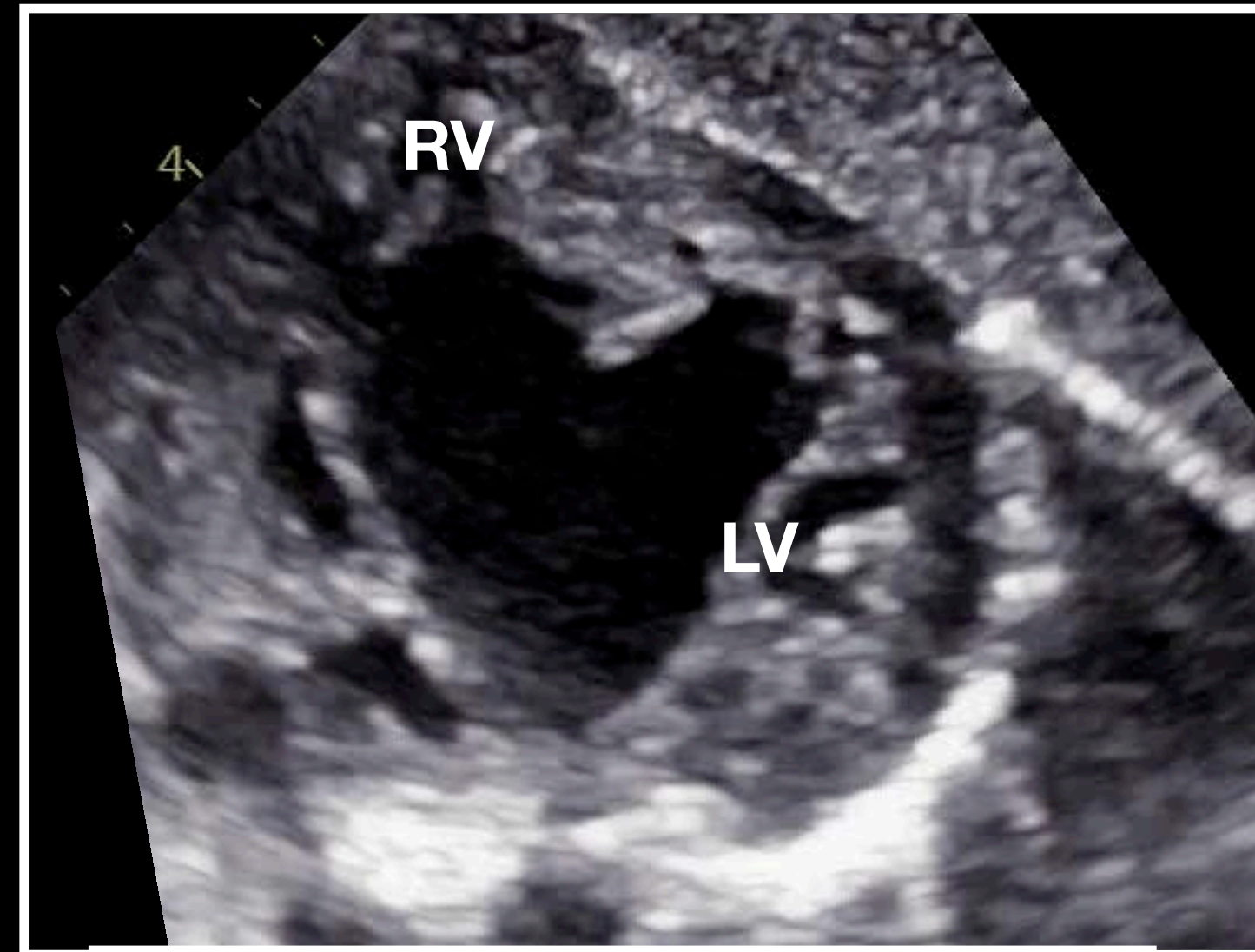
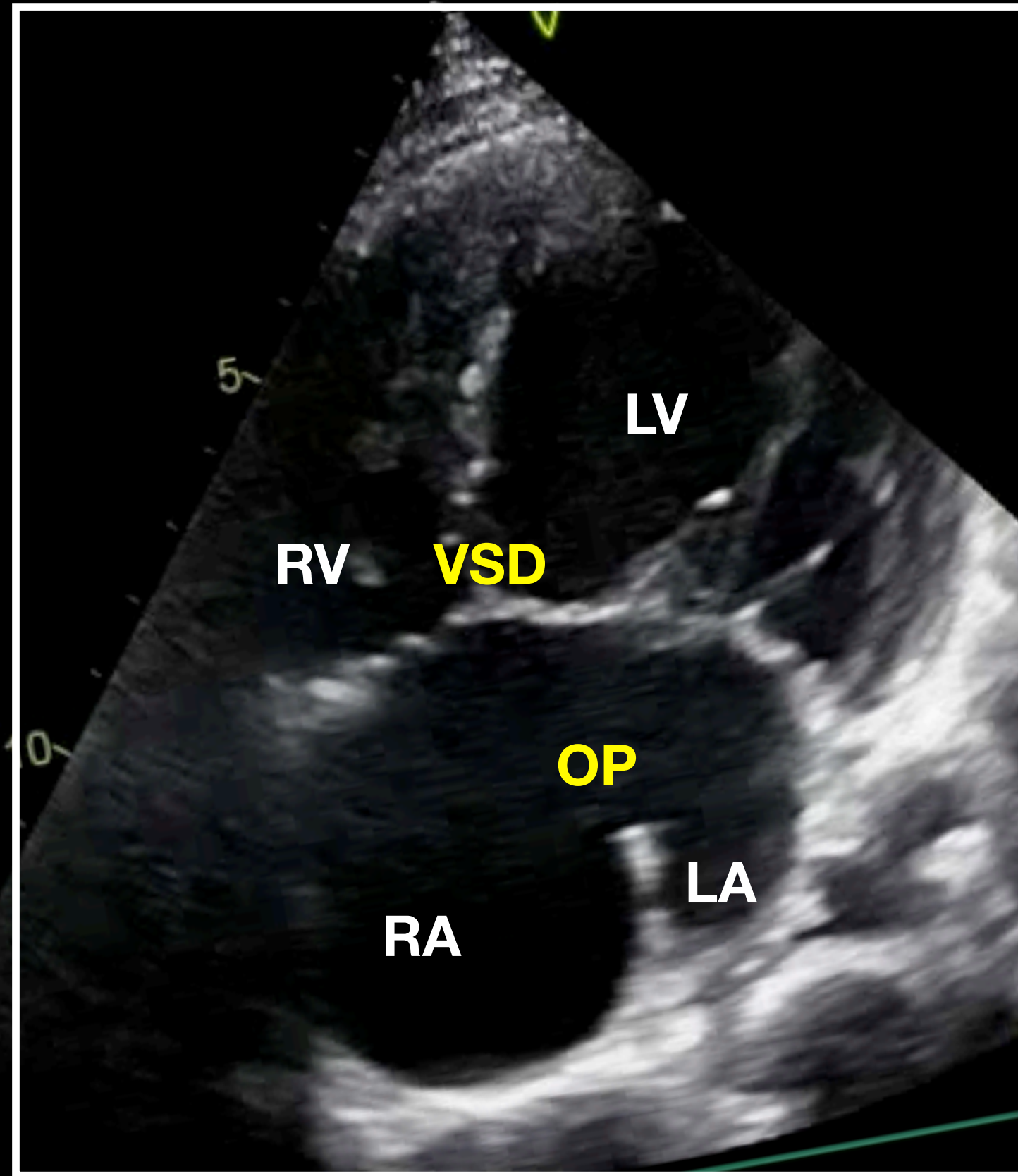


# Malalignment of atrial and ventricular septa



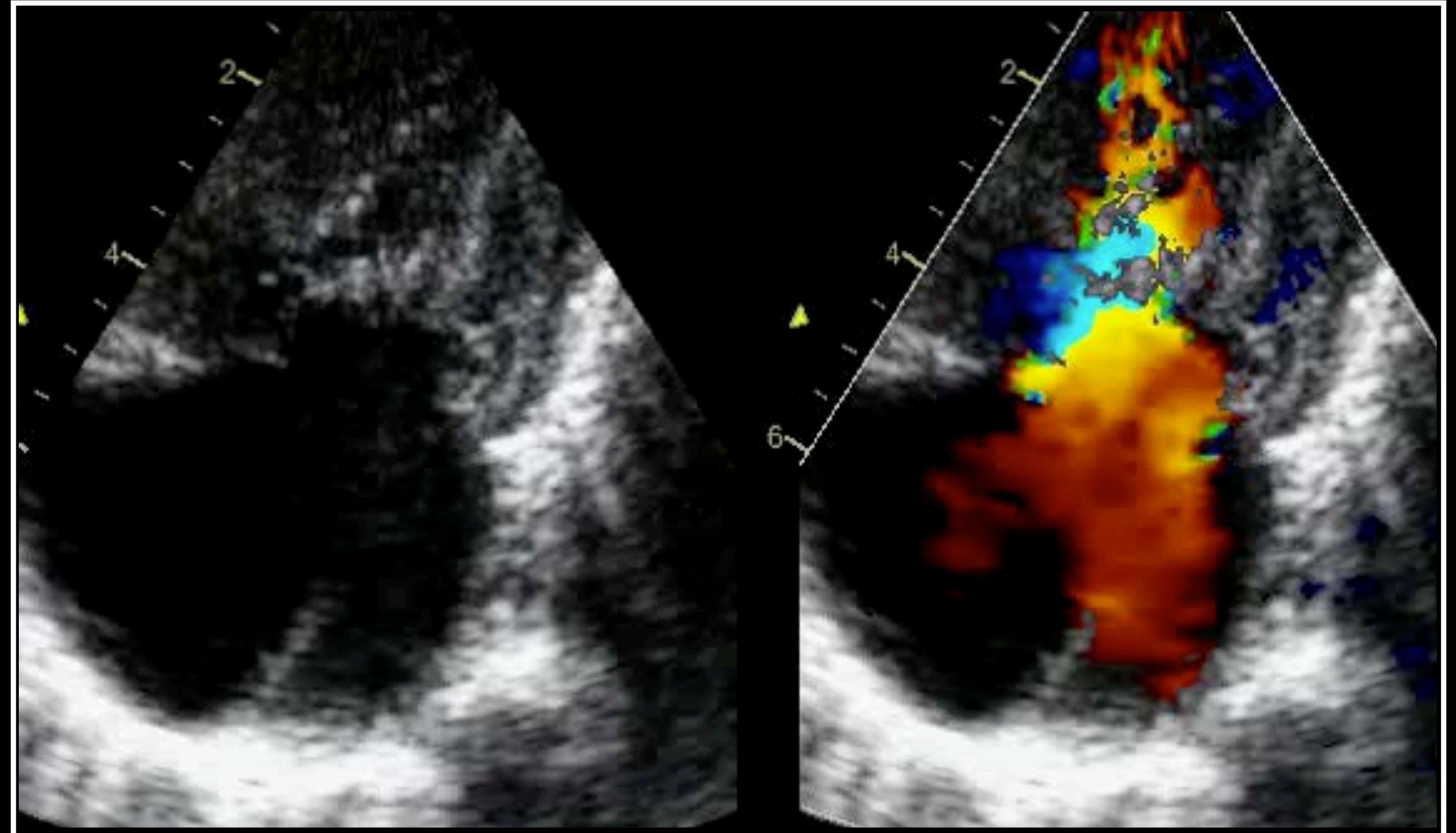
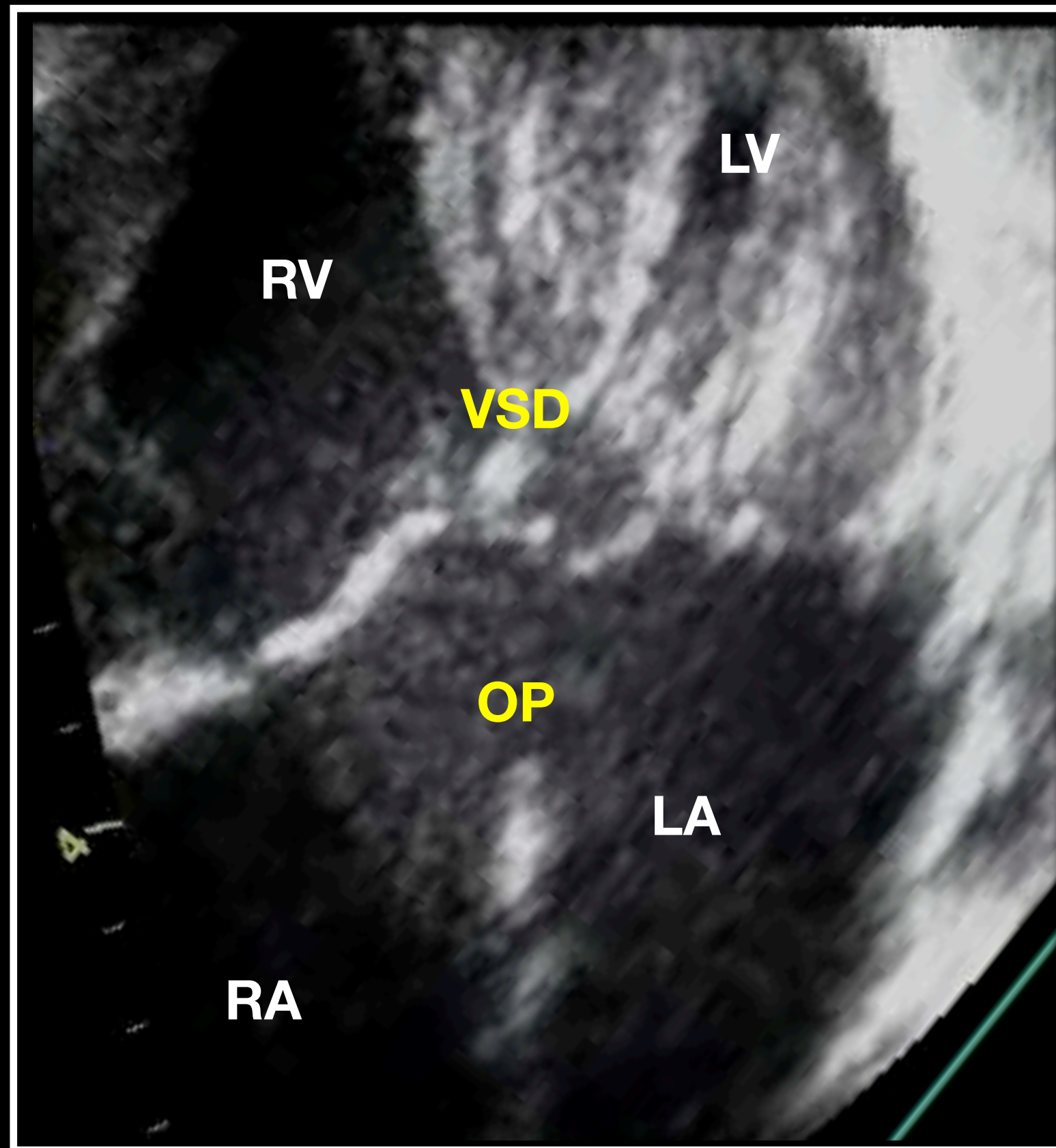
# Ventricles in AVSD

## Small RV



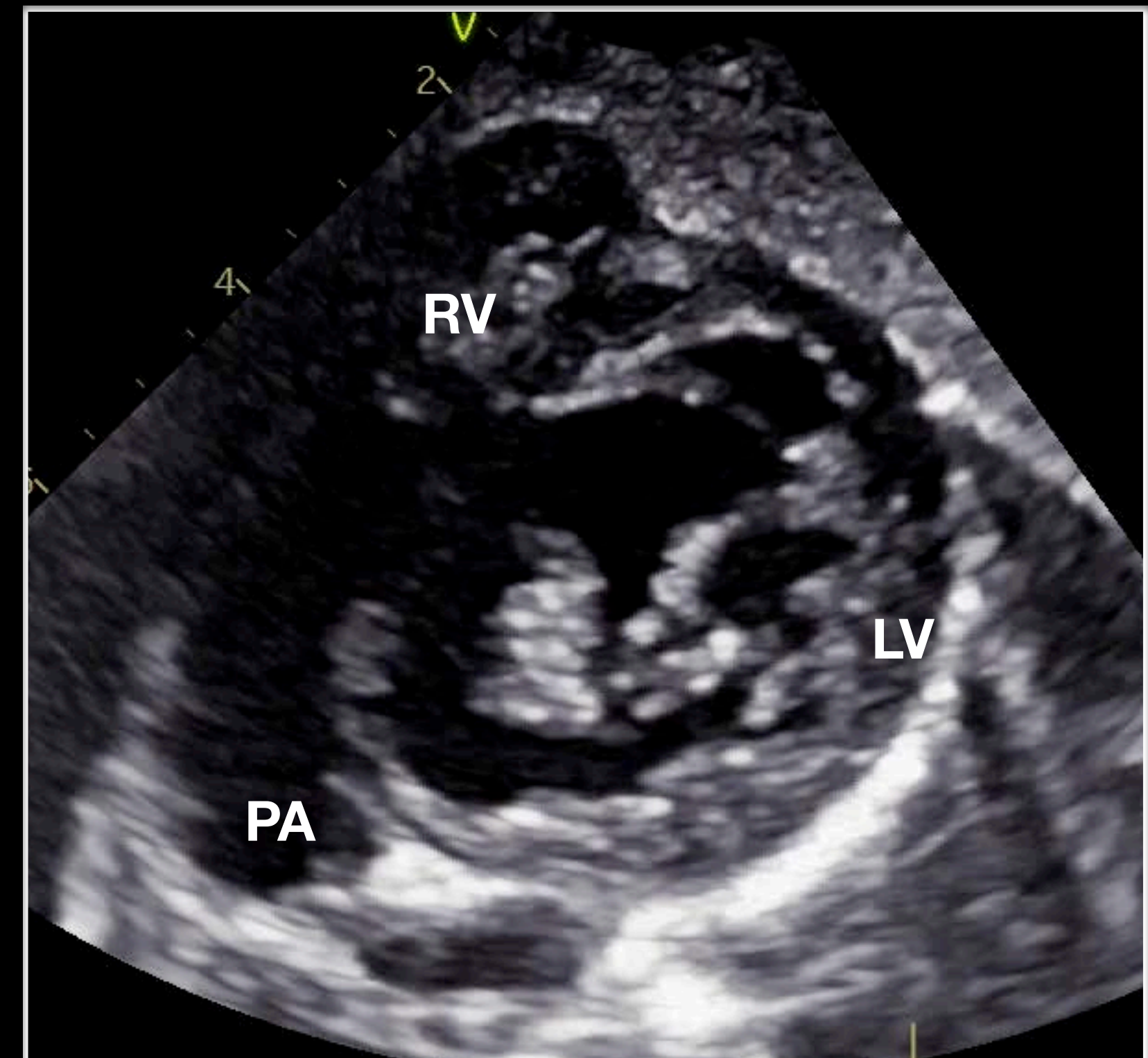
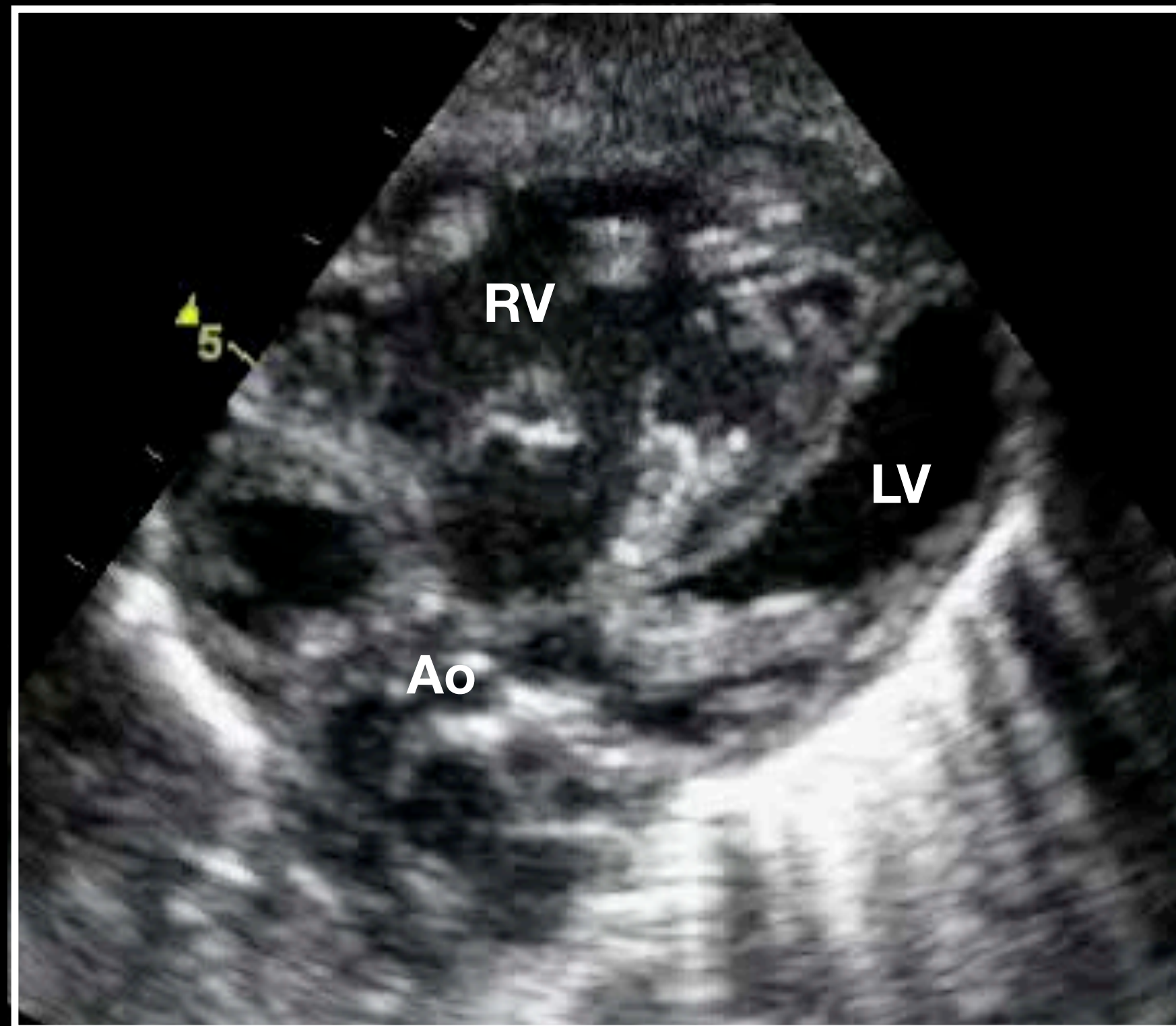
# Ventricles in AVSD

## Small LV

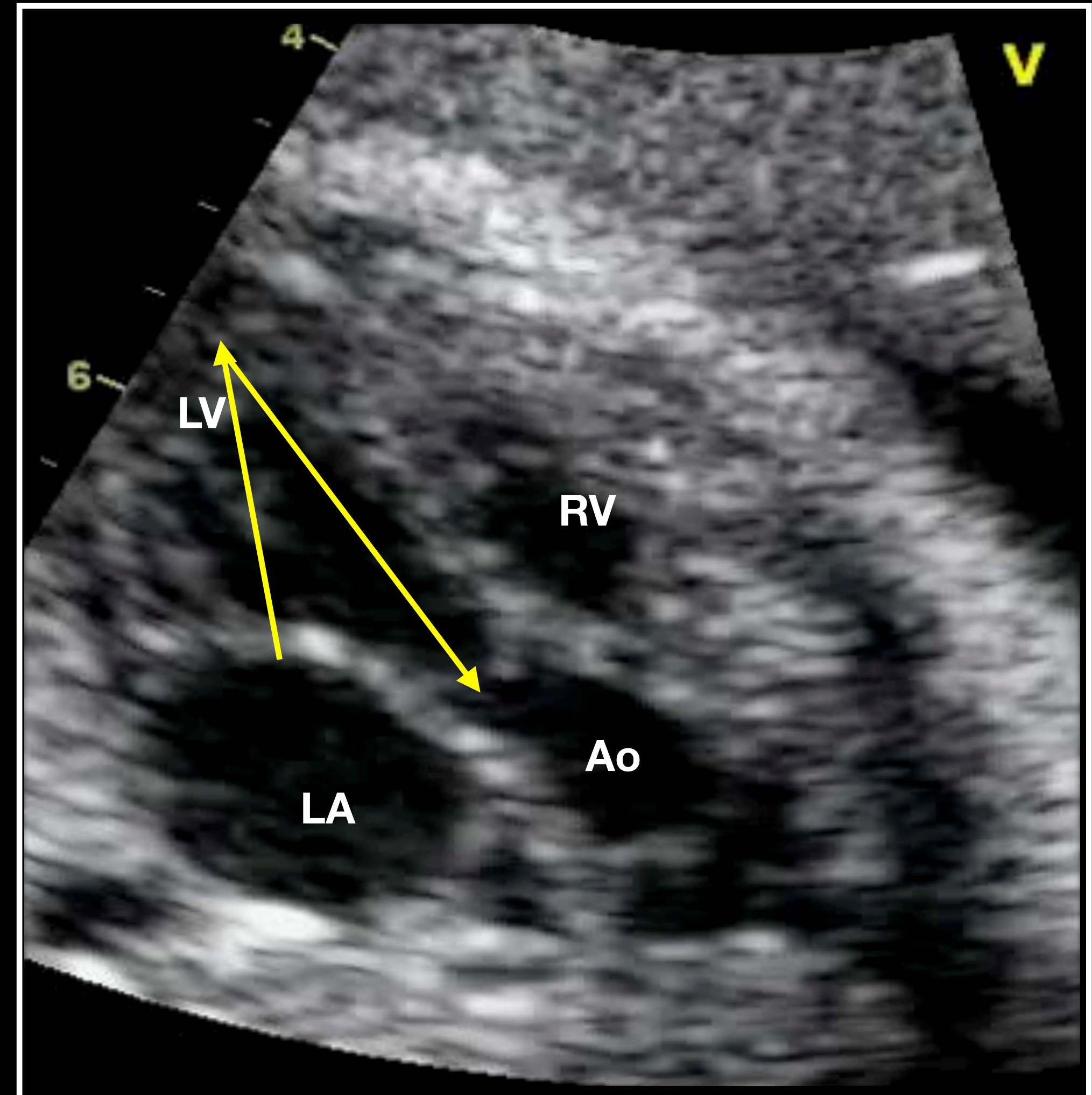
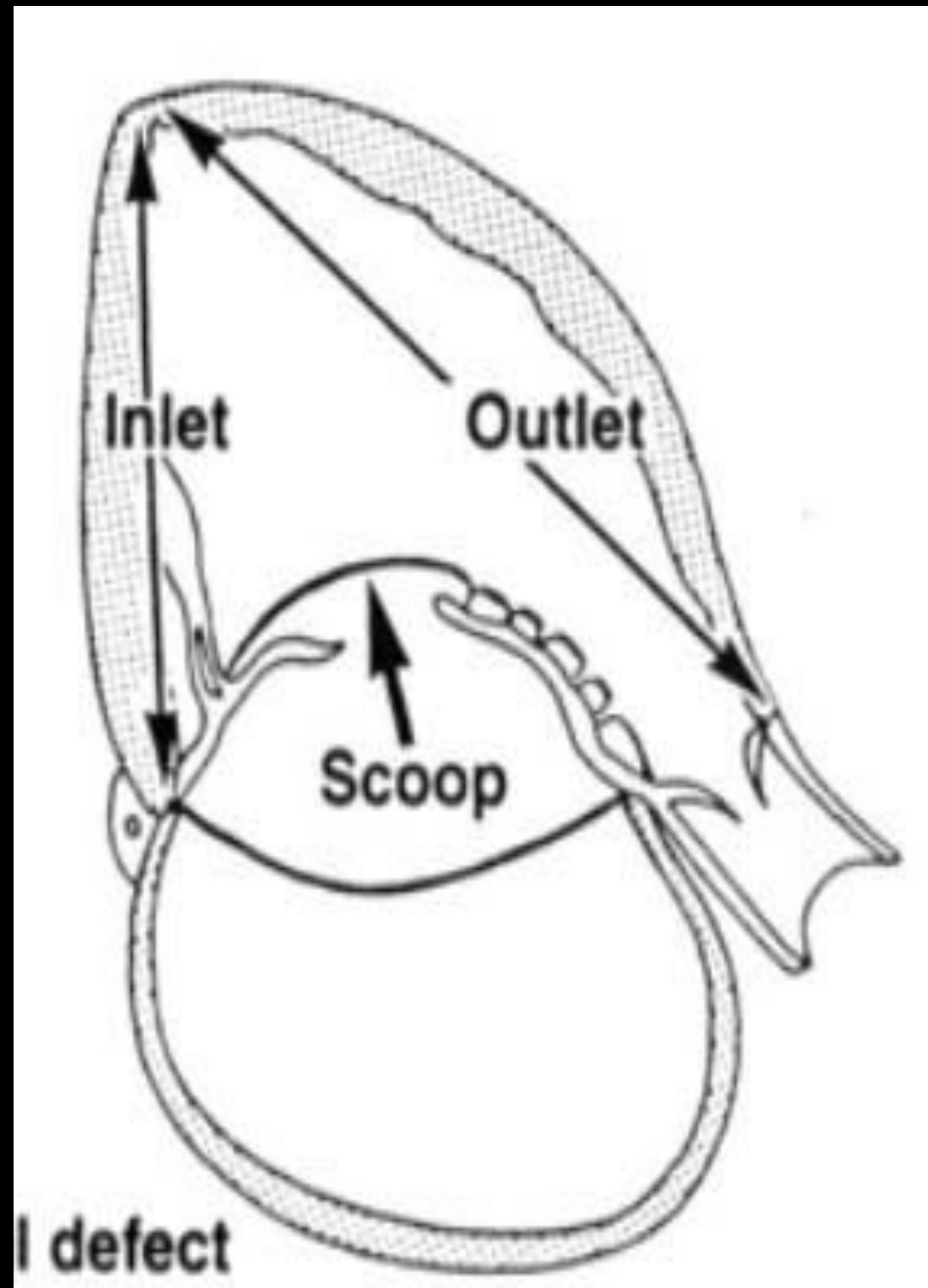


# Ventricles in AVSD

Hypoplastic left ventricle - Hypoplastic right ventricle

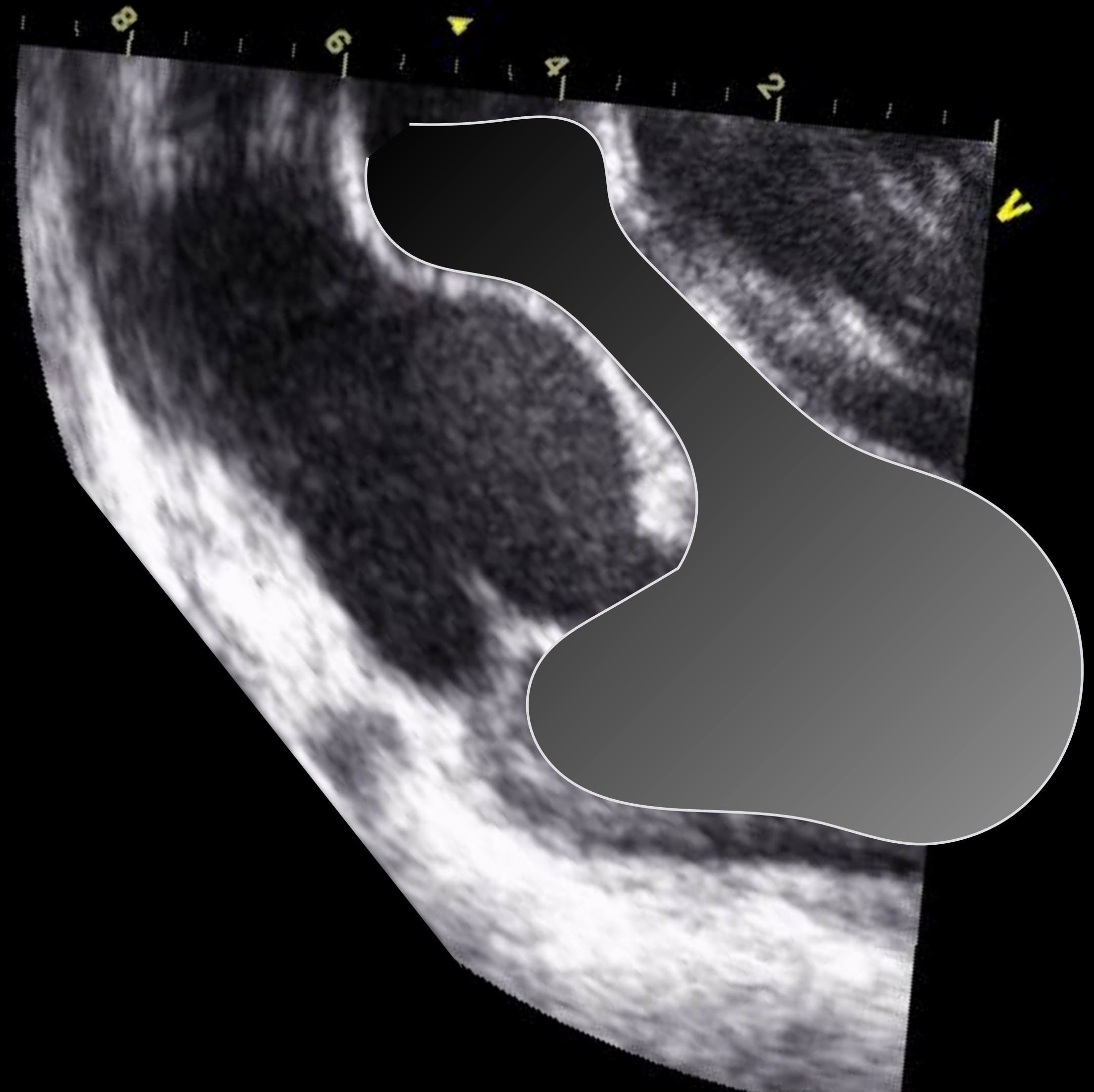
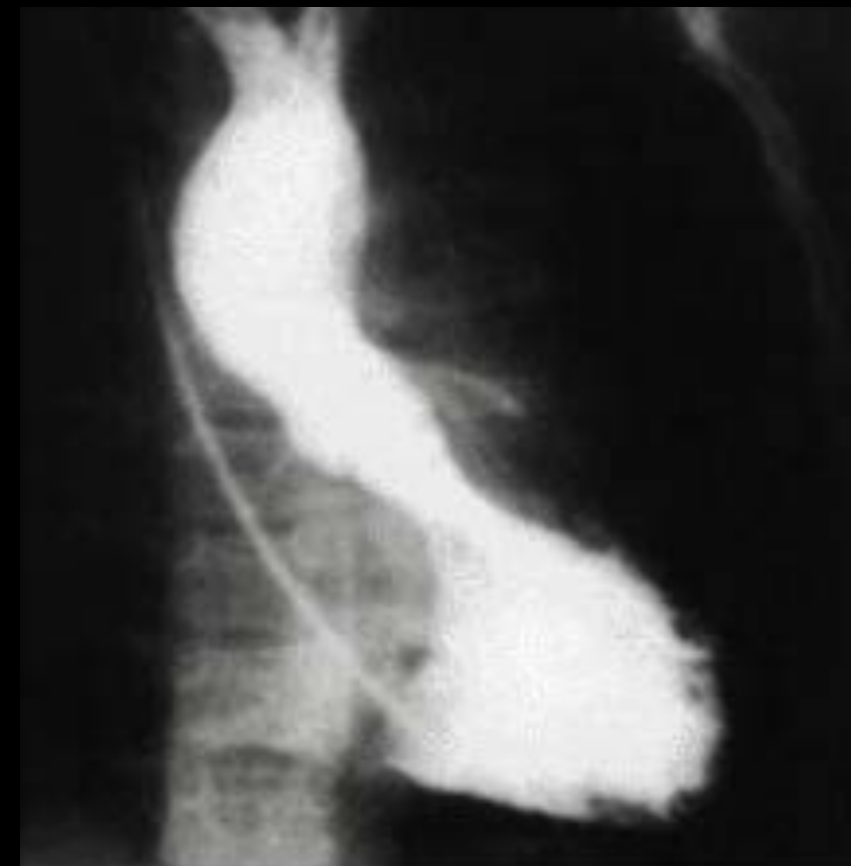
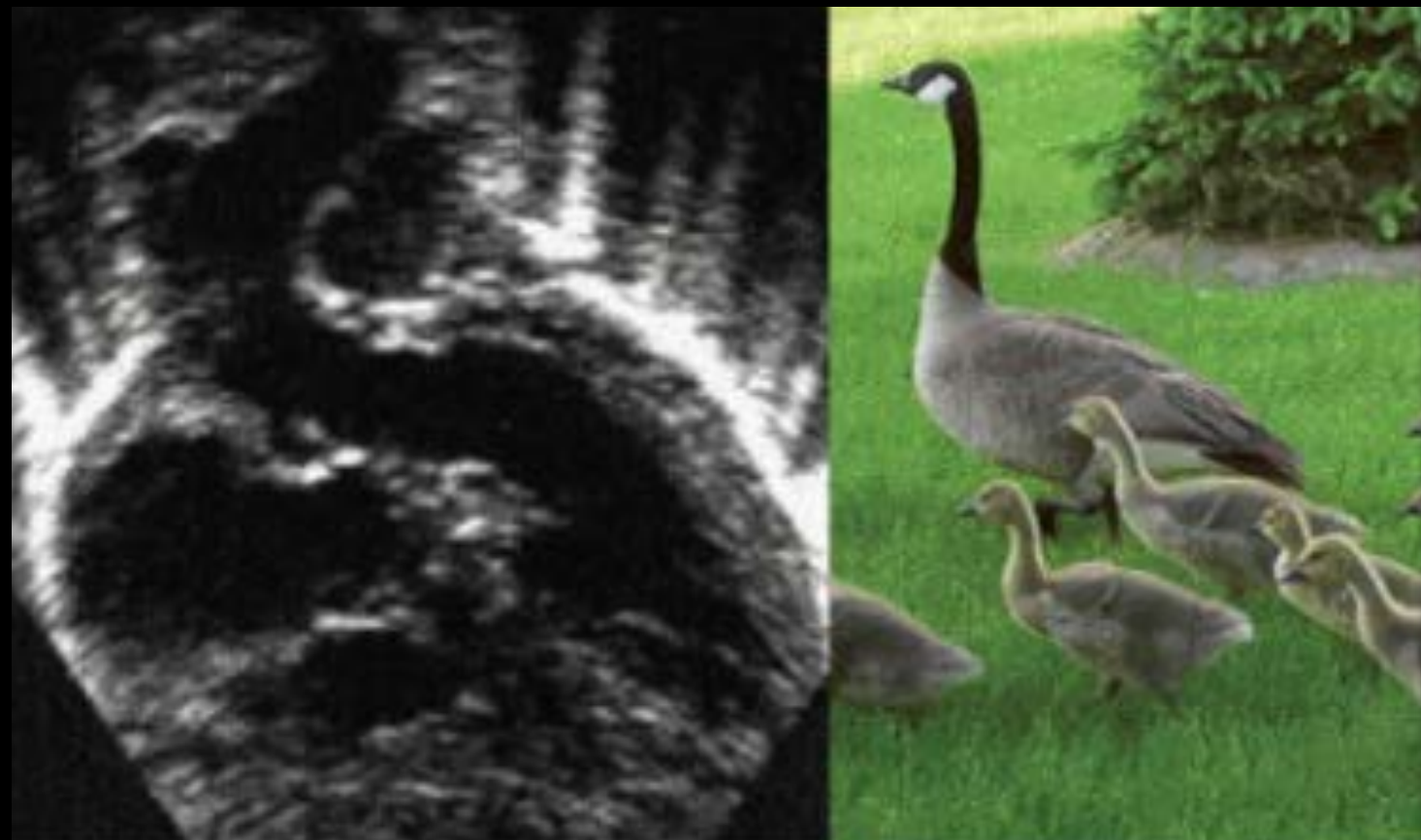
# Outflow tracts in AVSD

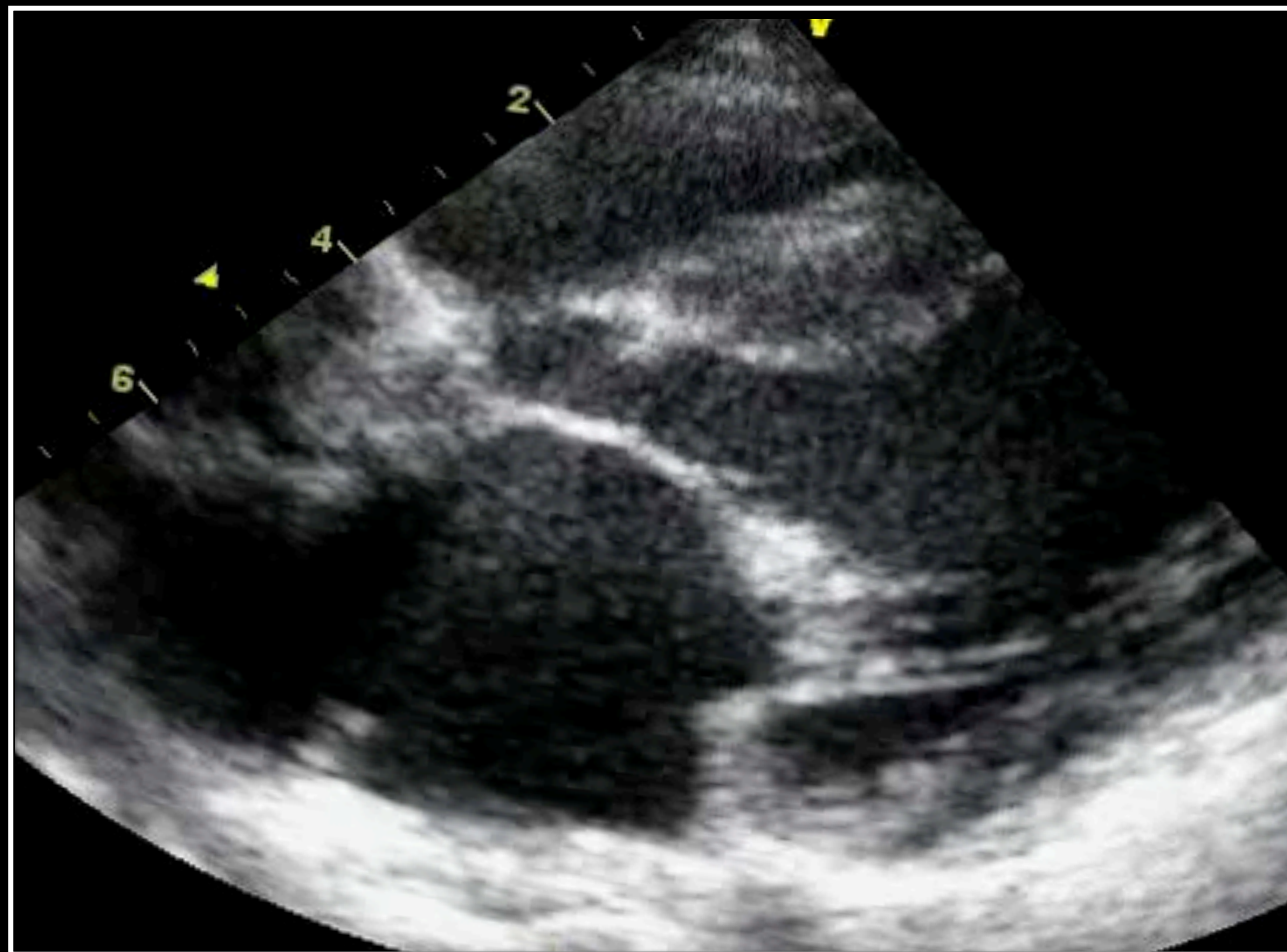




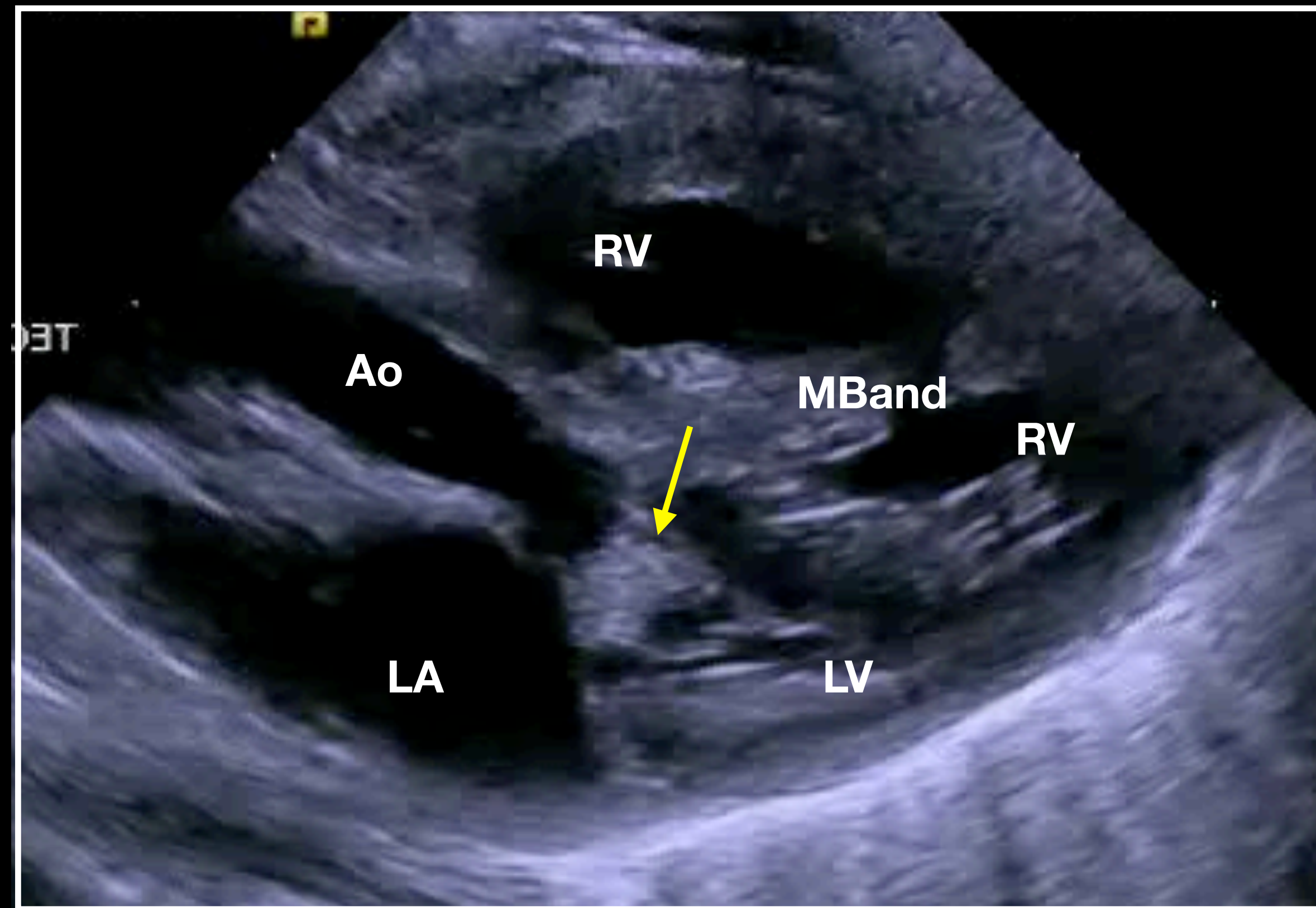
# Goose Neck in AVSD



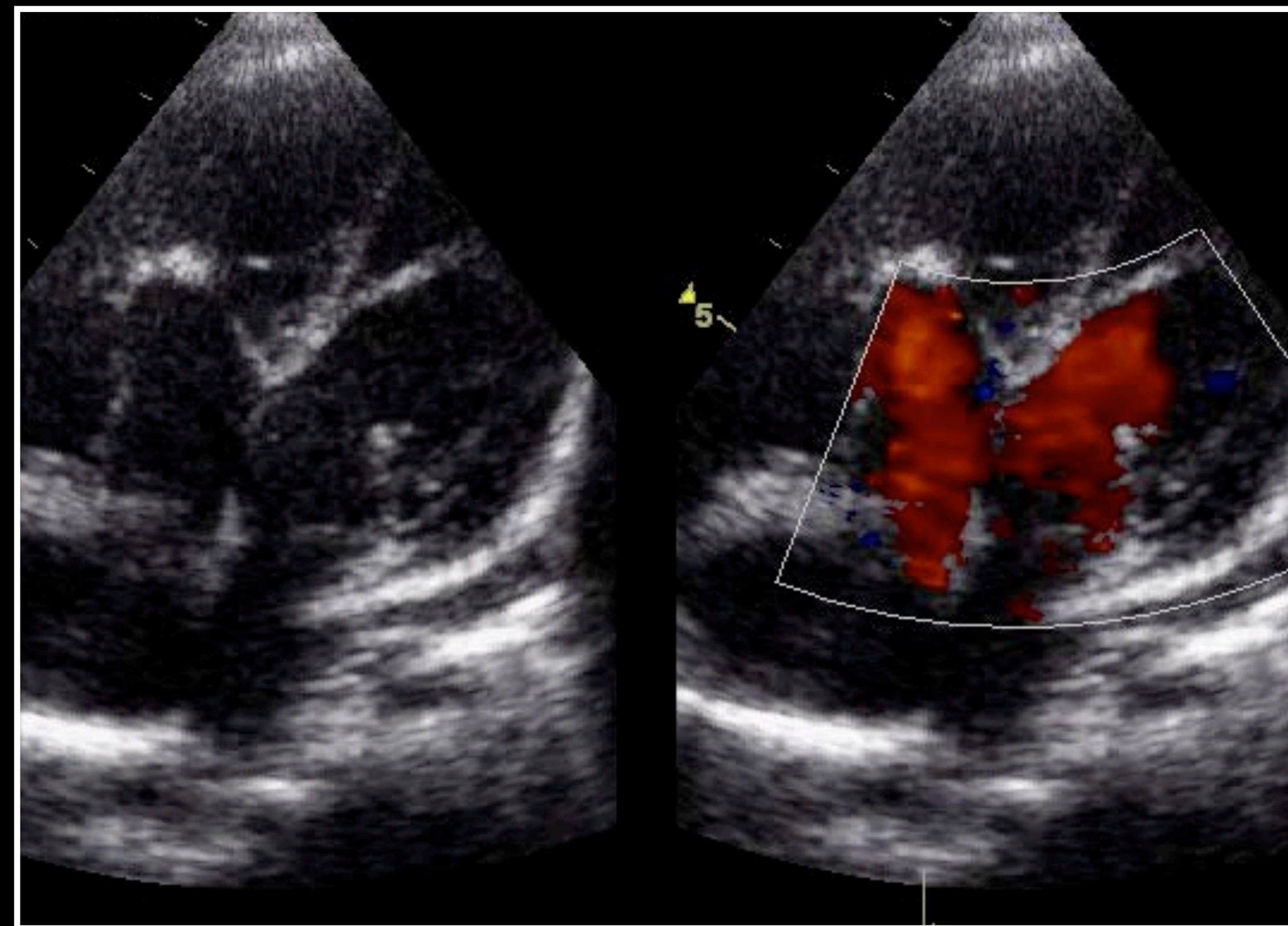
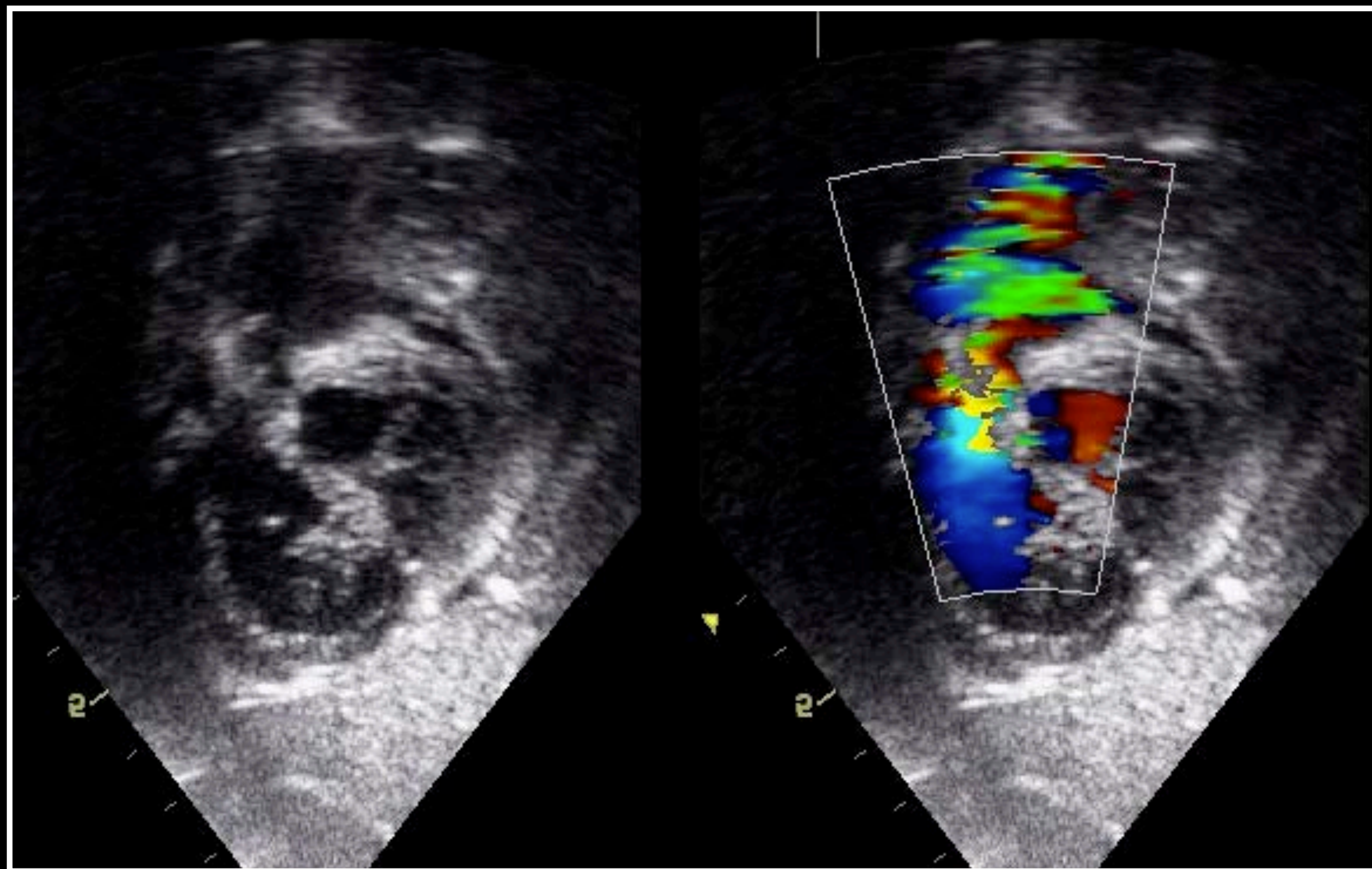
# Goose Neck in AVSD



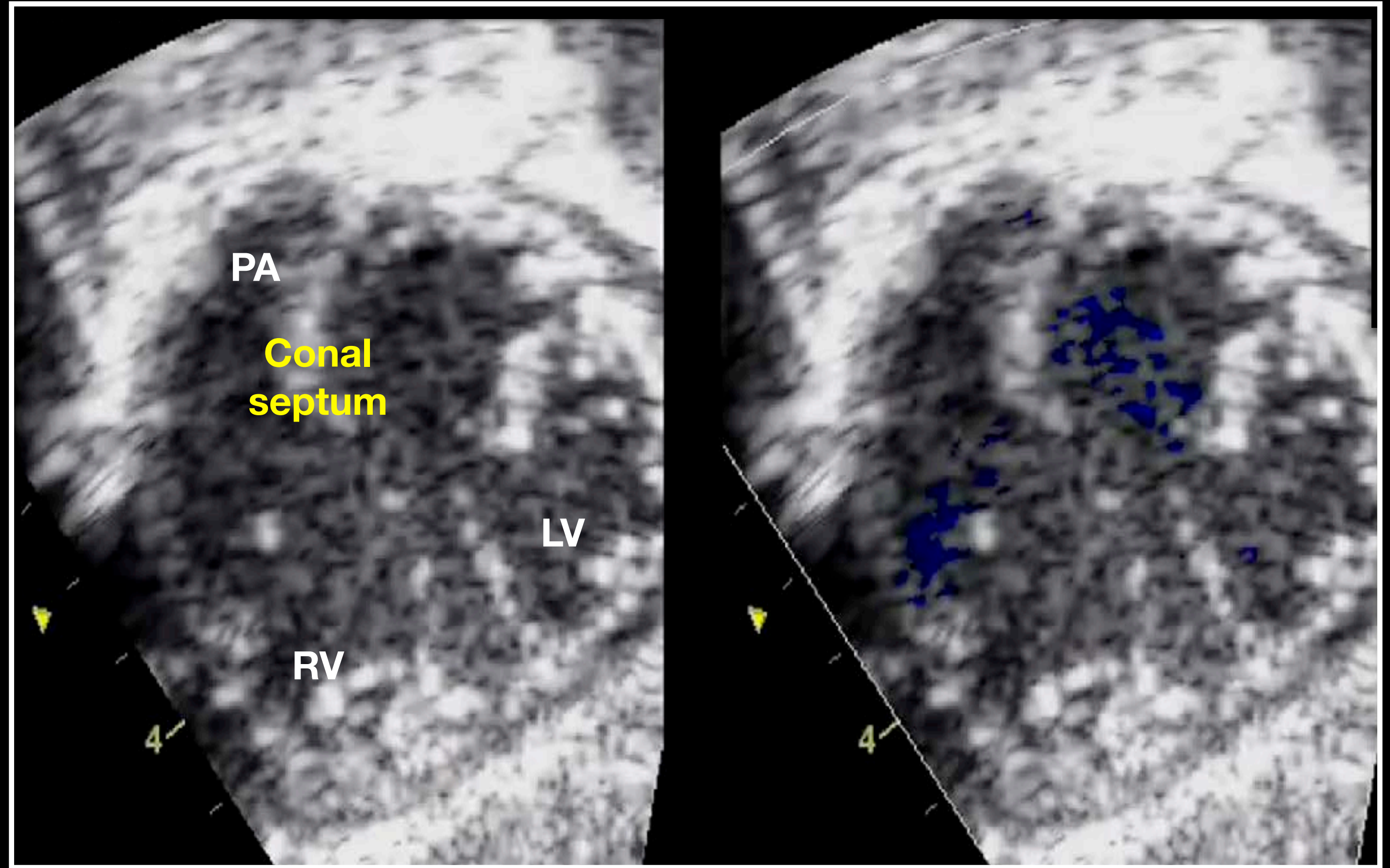
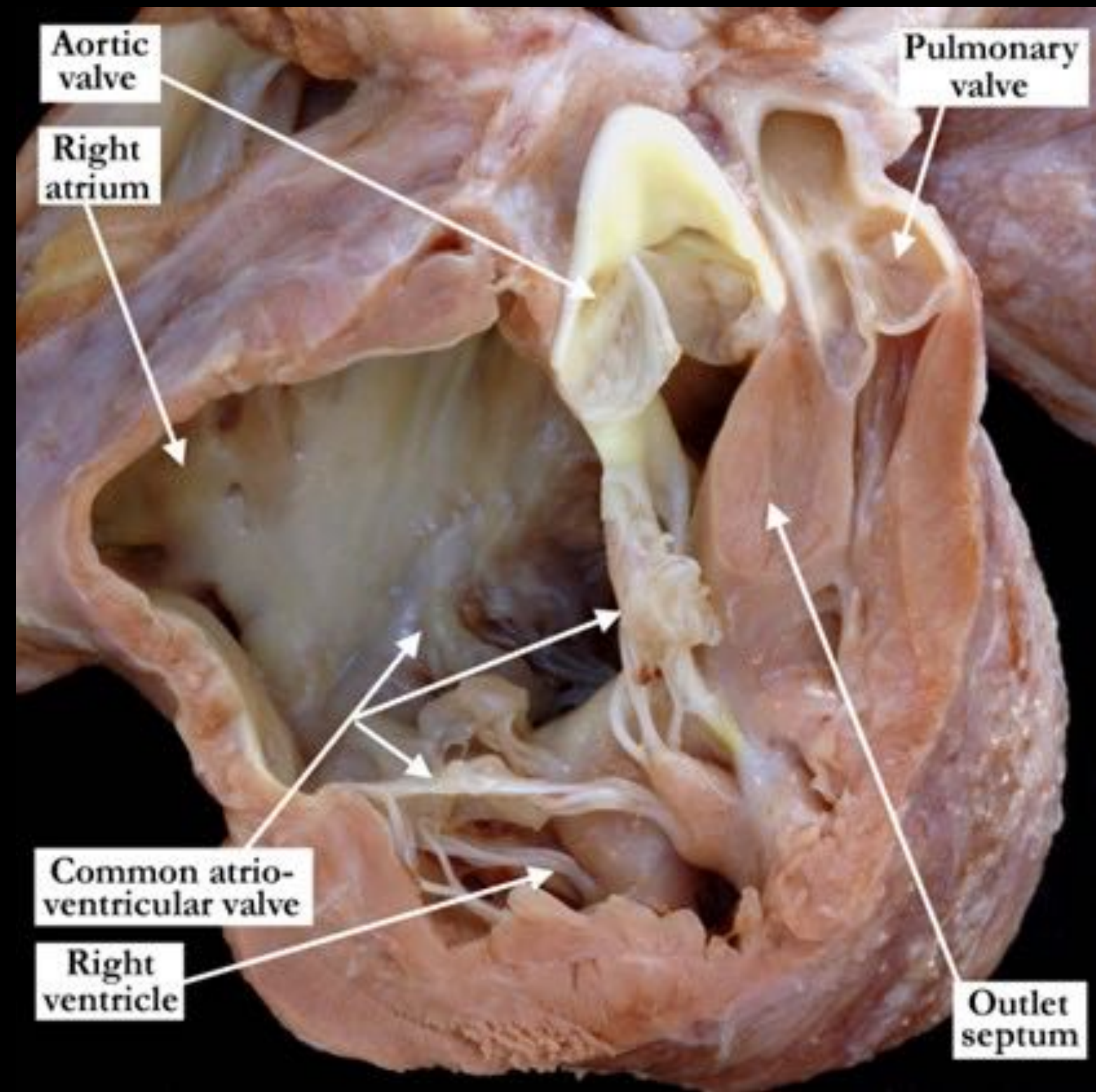
# Left outflow tract in AVSD



# Pulmonary valve stenosis in AVSD

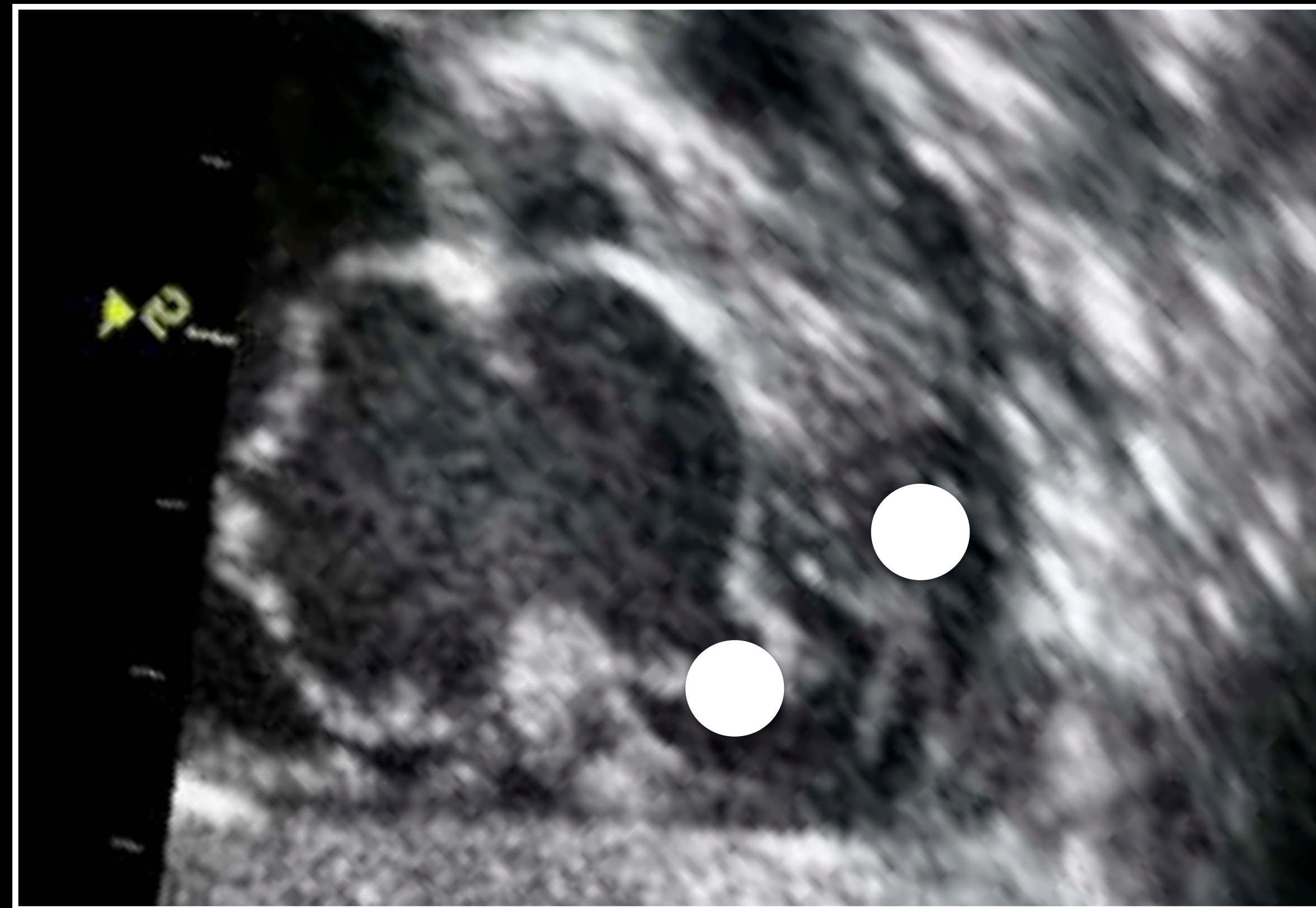


# AVSD & Fallot

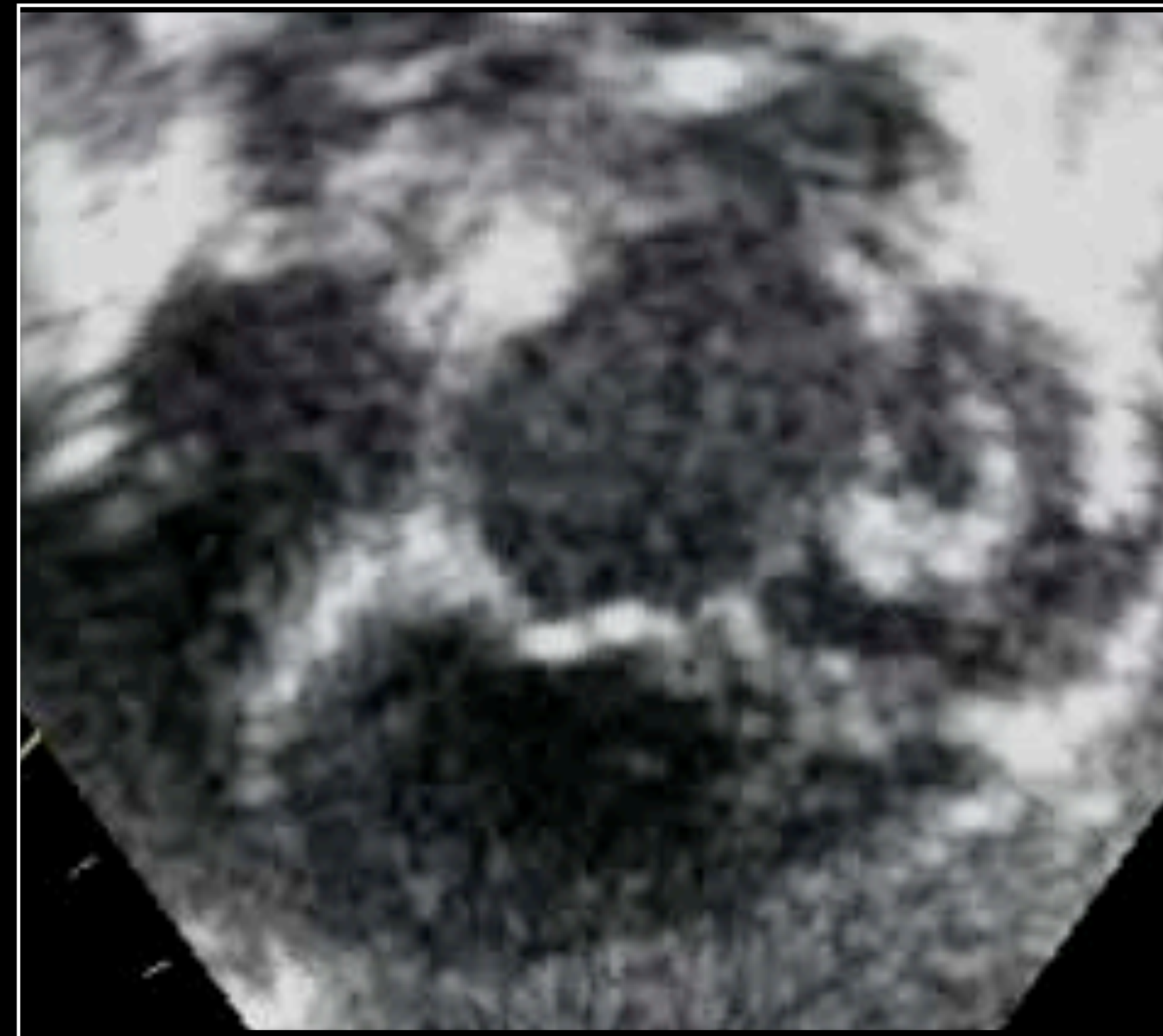
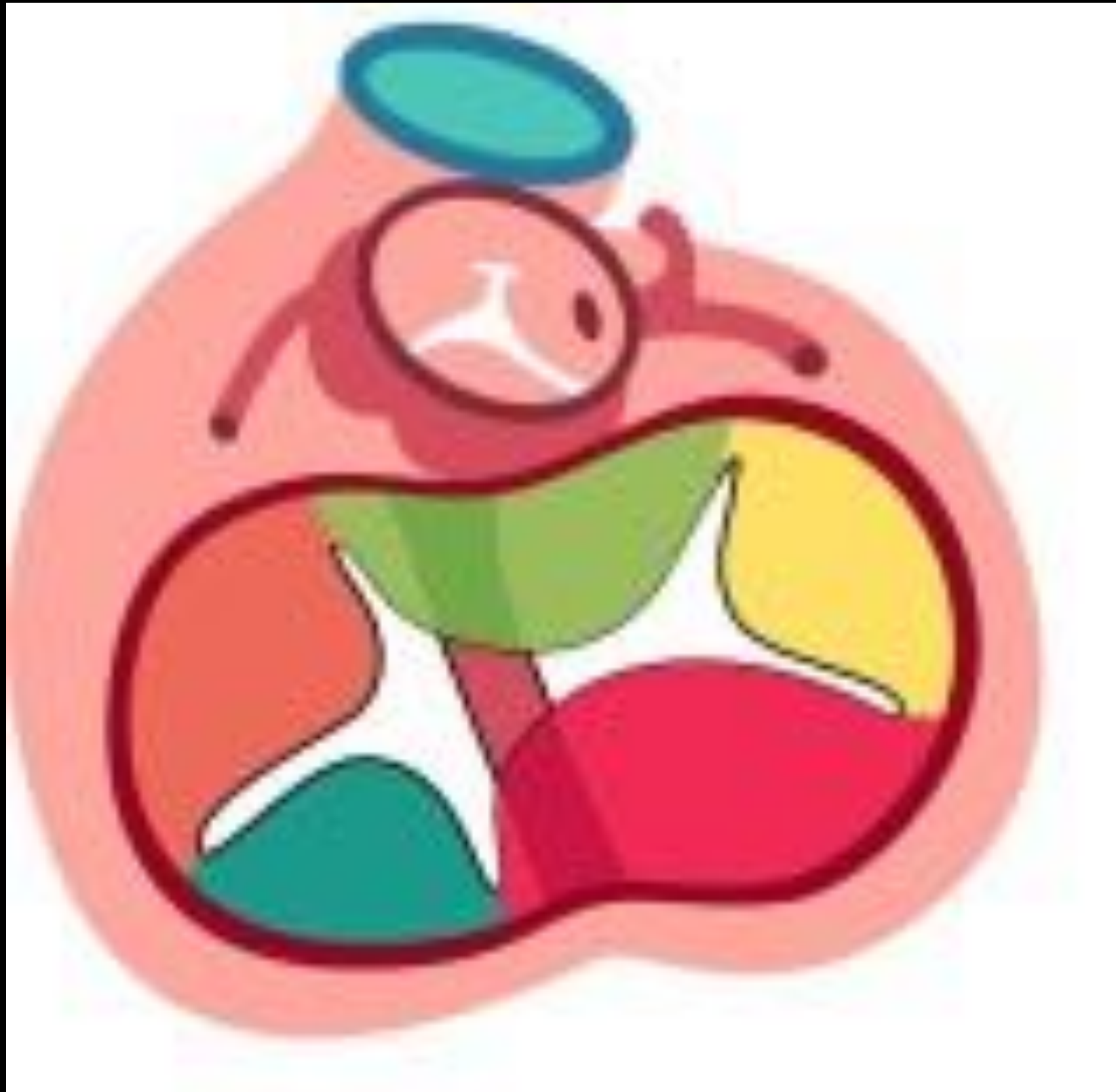
# Atrioventricular valves in AVSD

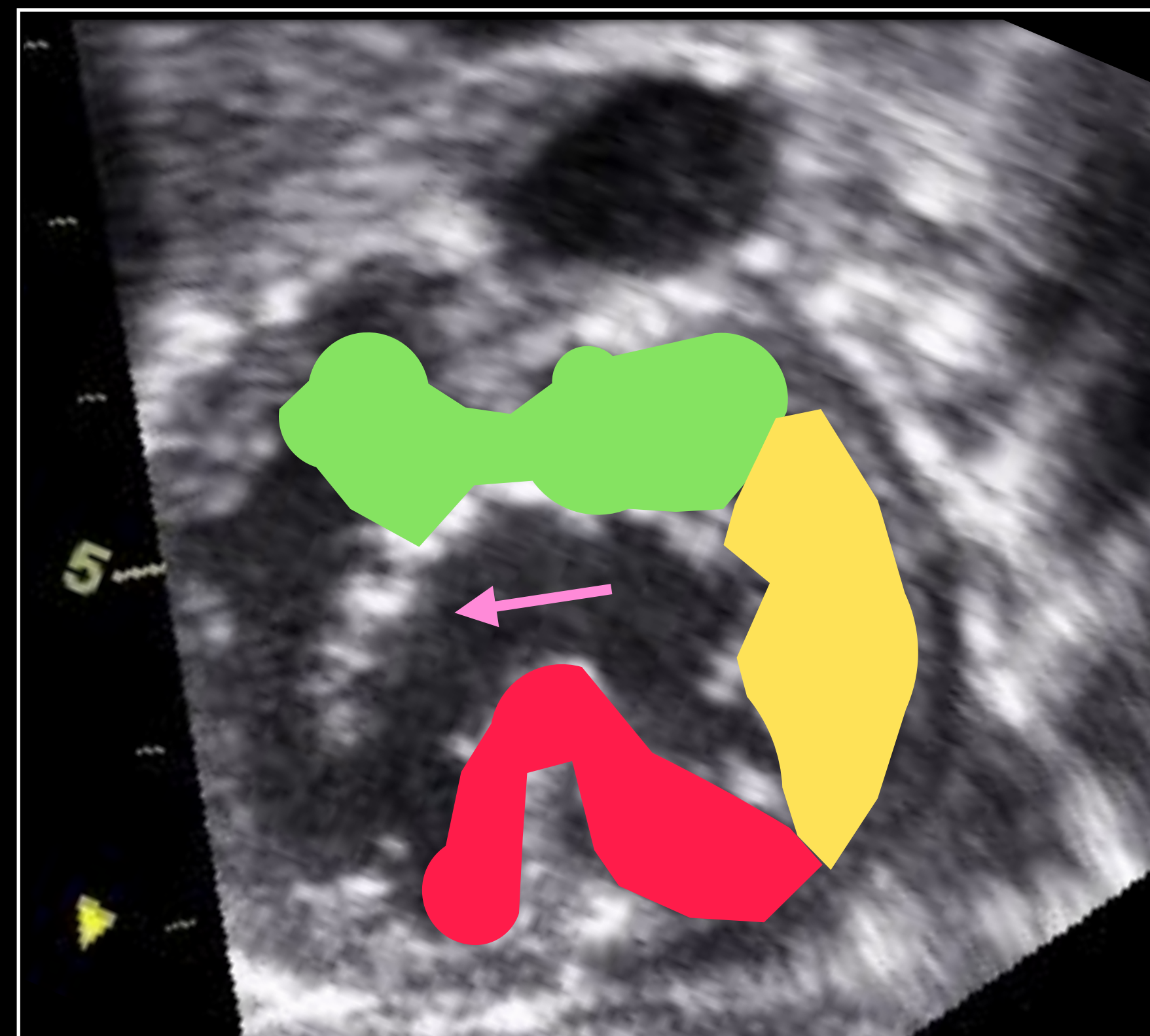
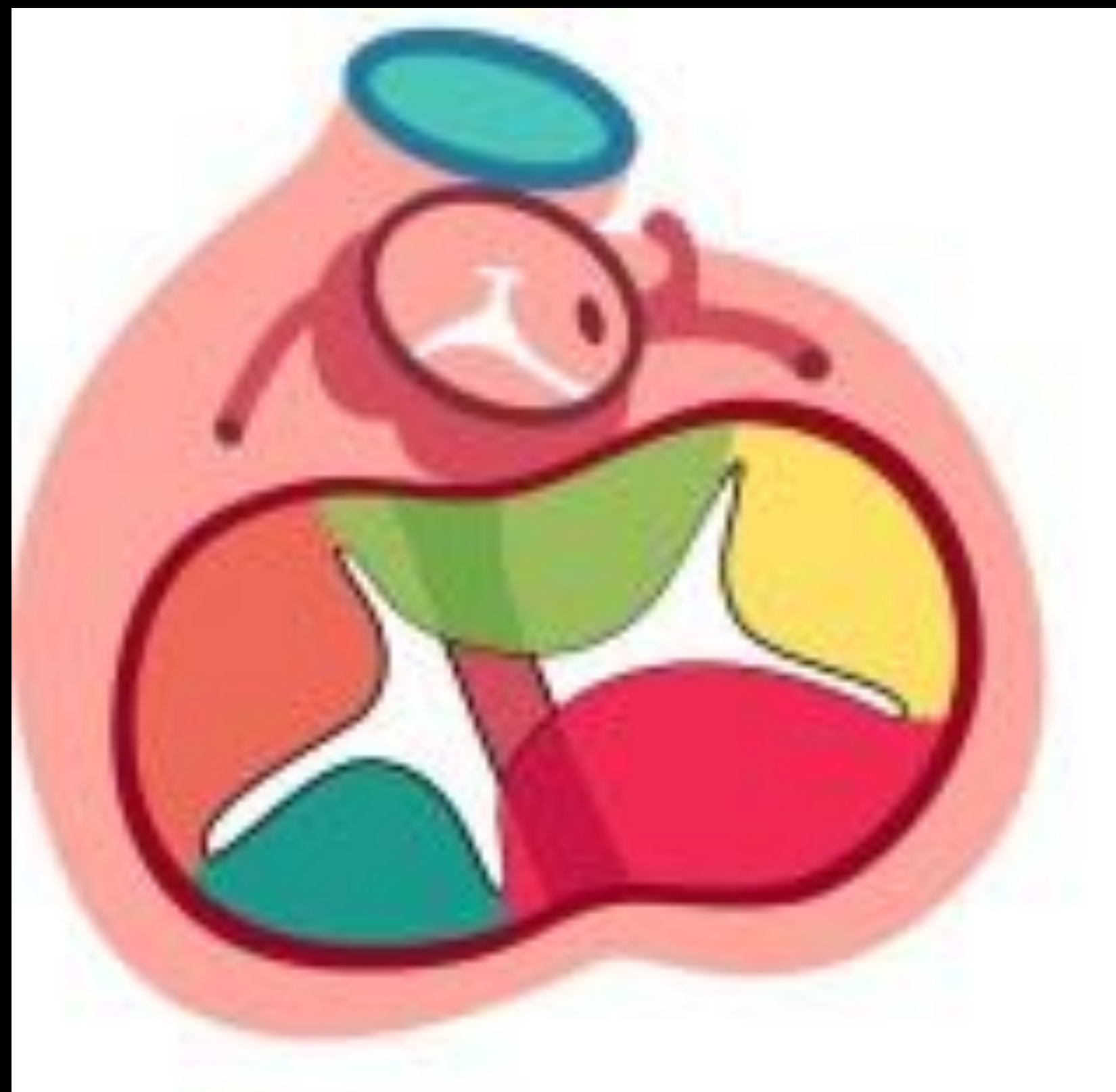## Malpositions of the papillary muscles



# Atrioventricular valves in AVSD

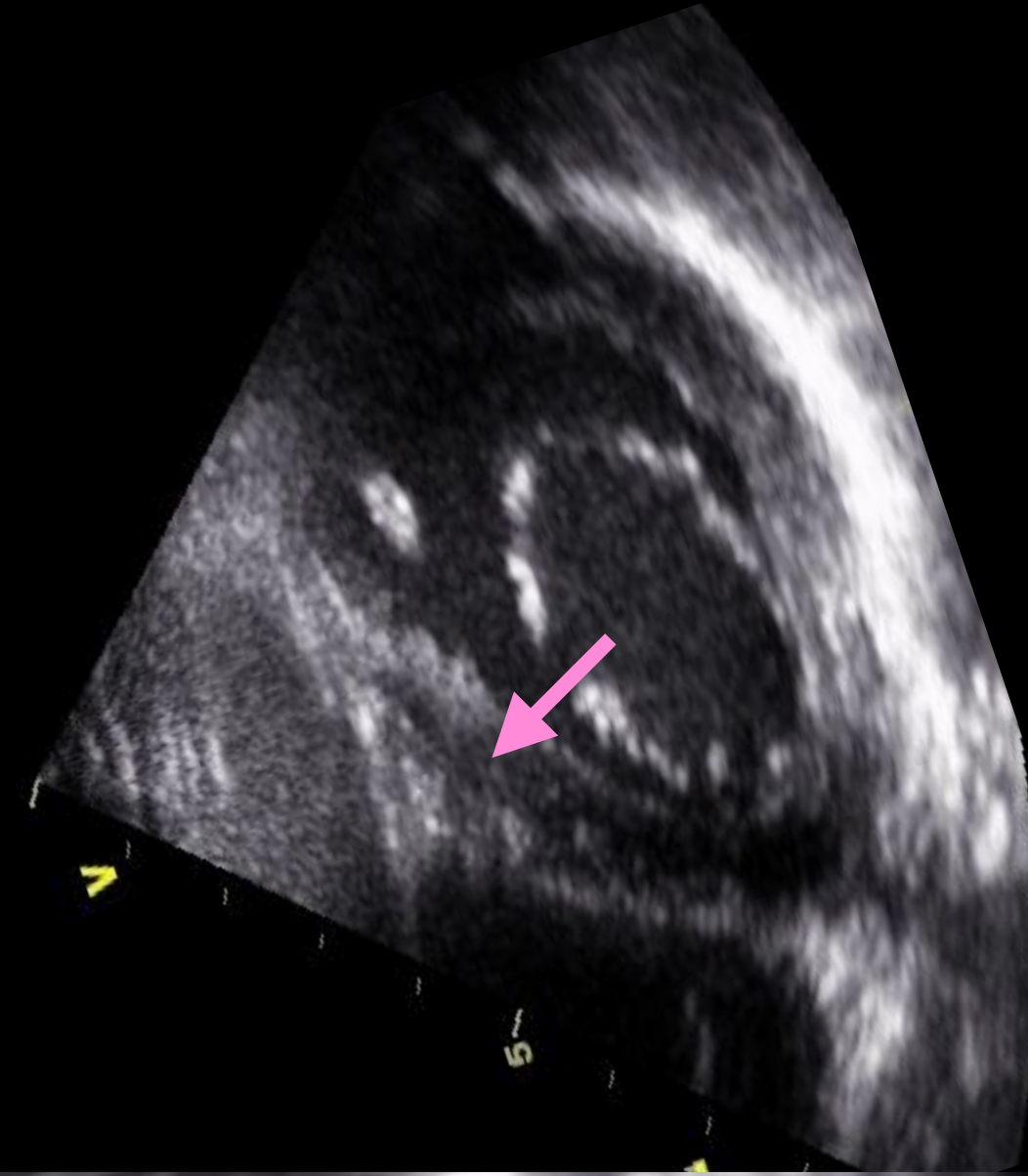
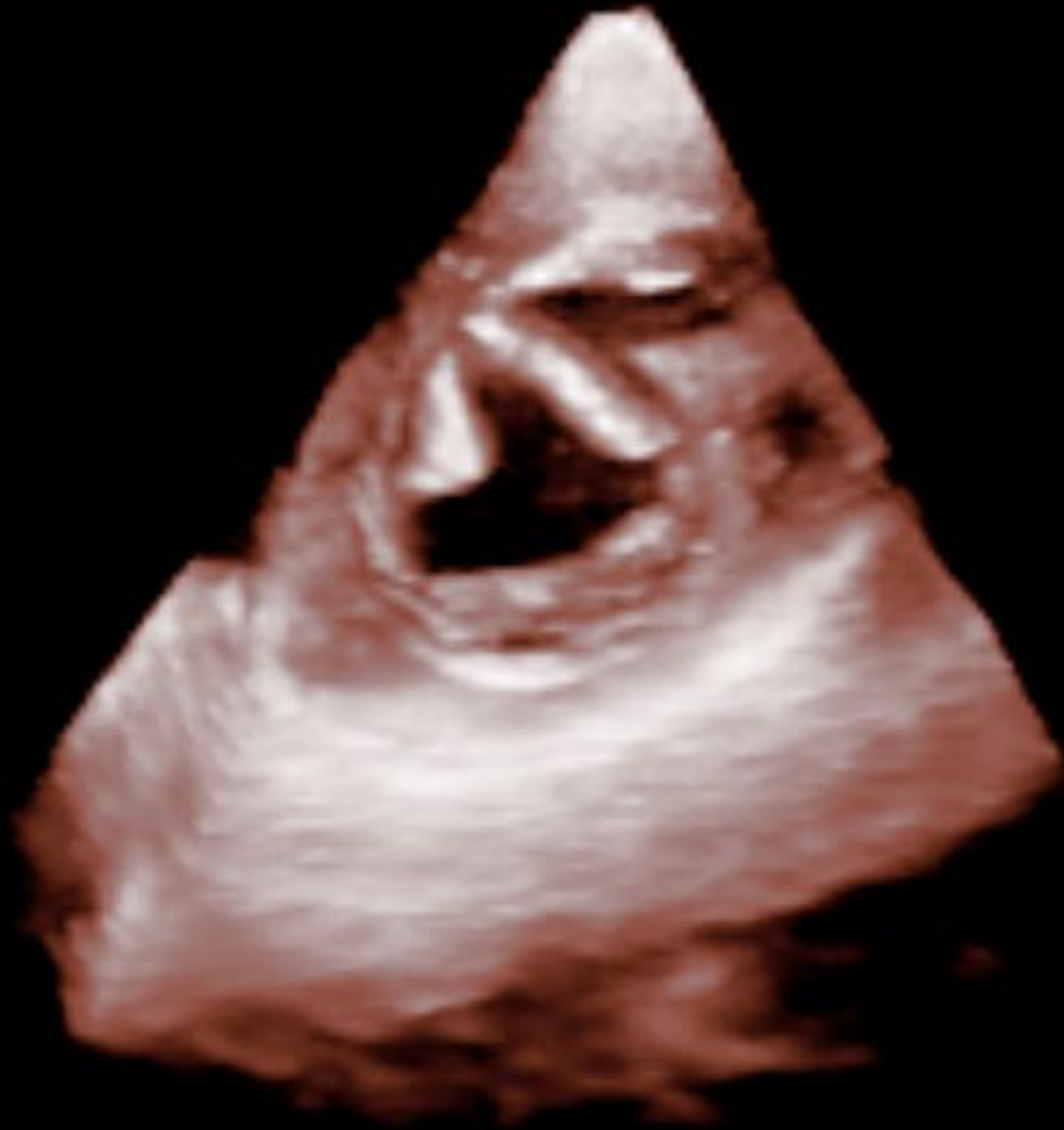
# Atrioventricular valves in AVSD

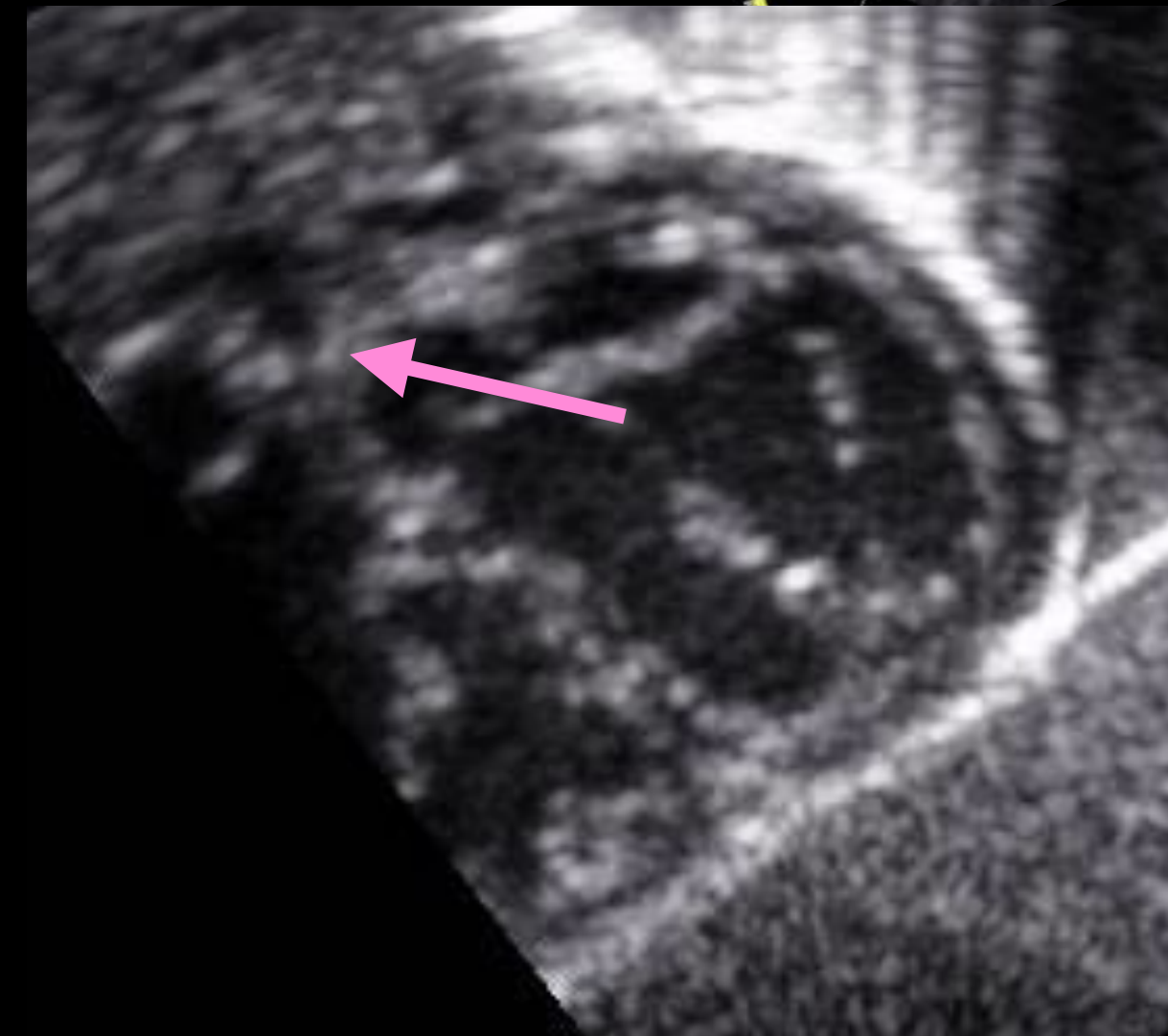



# Isolated mitral cleft

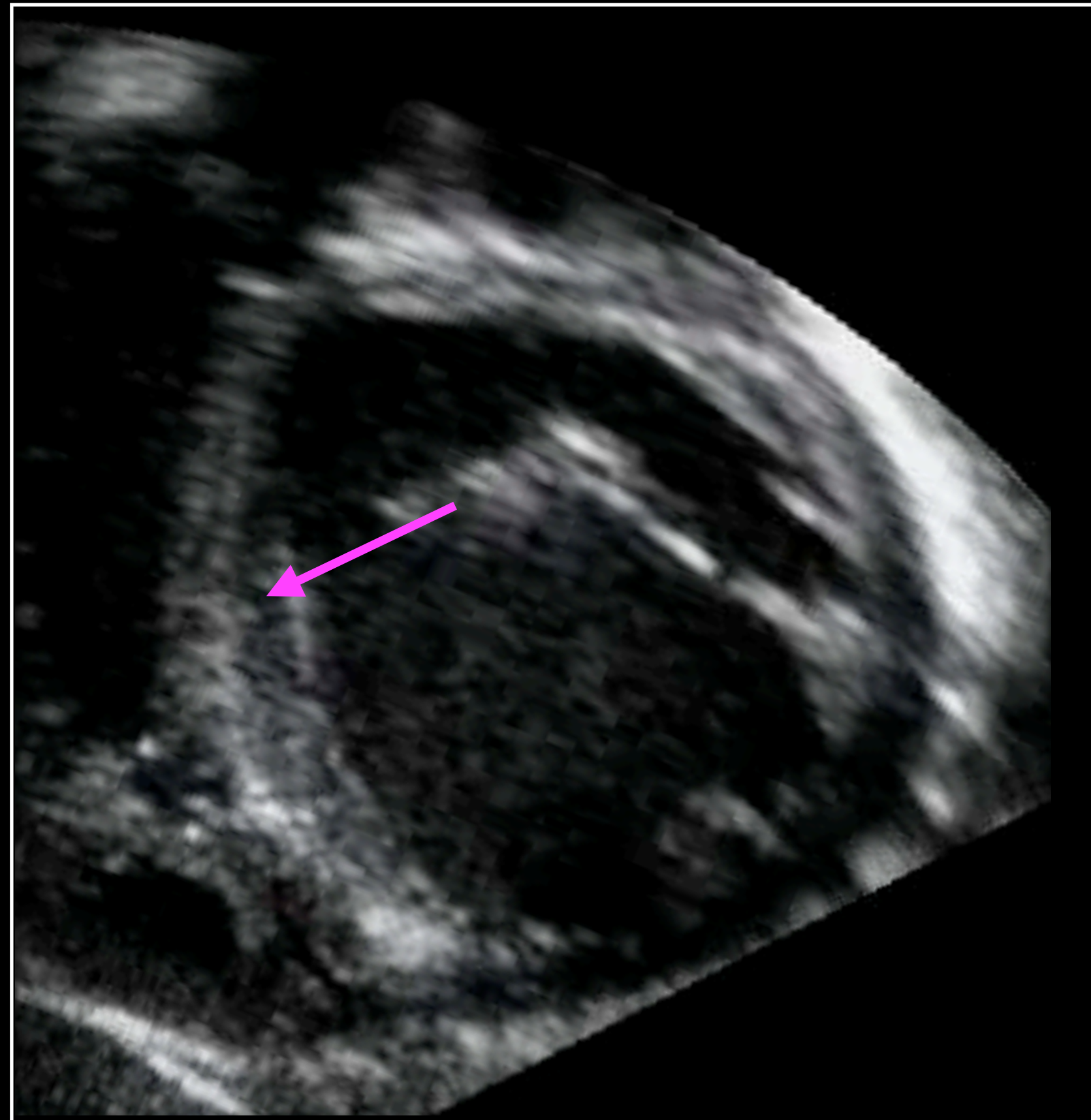


**AVSD type**

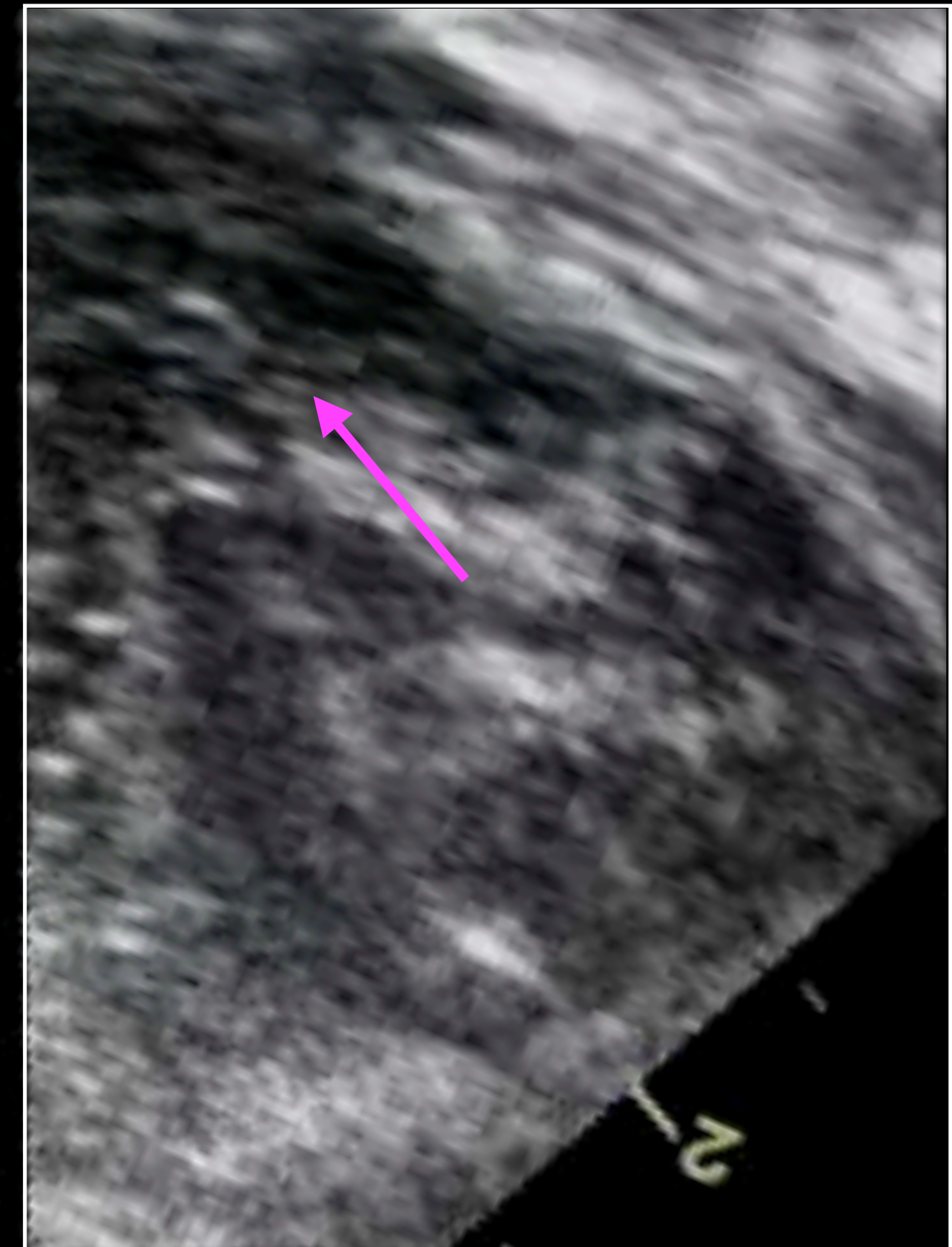


**Outlet type**

# Mitral clefts: two types

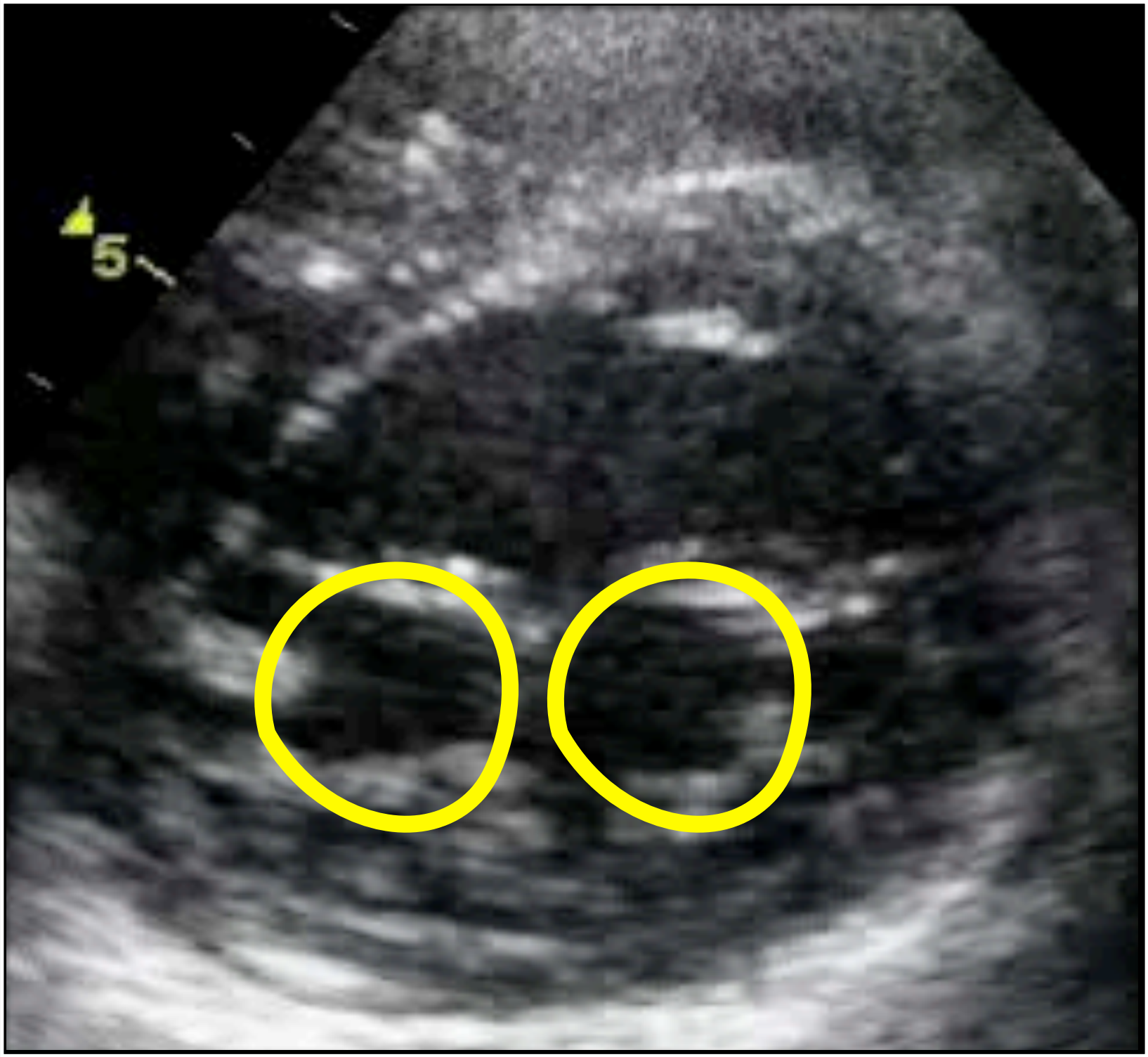
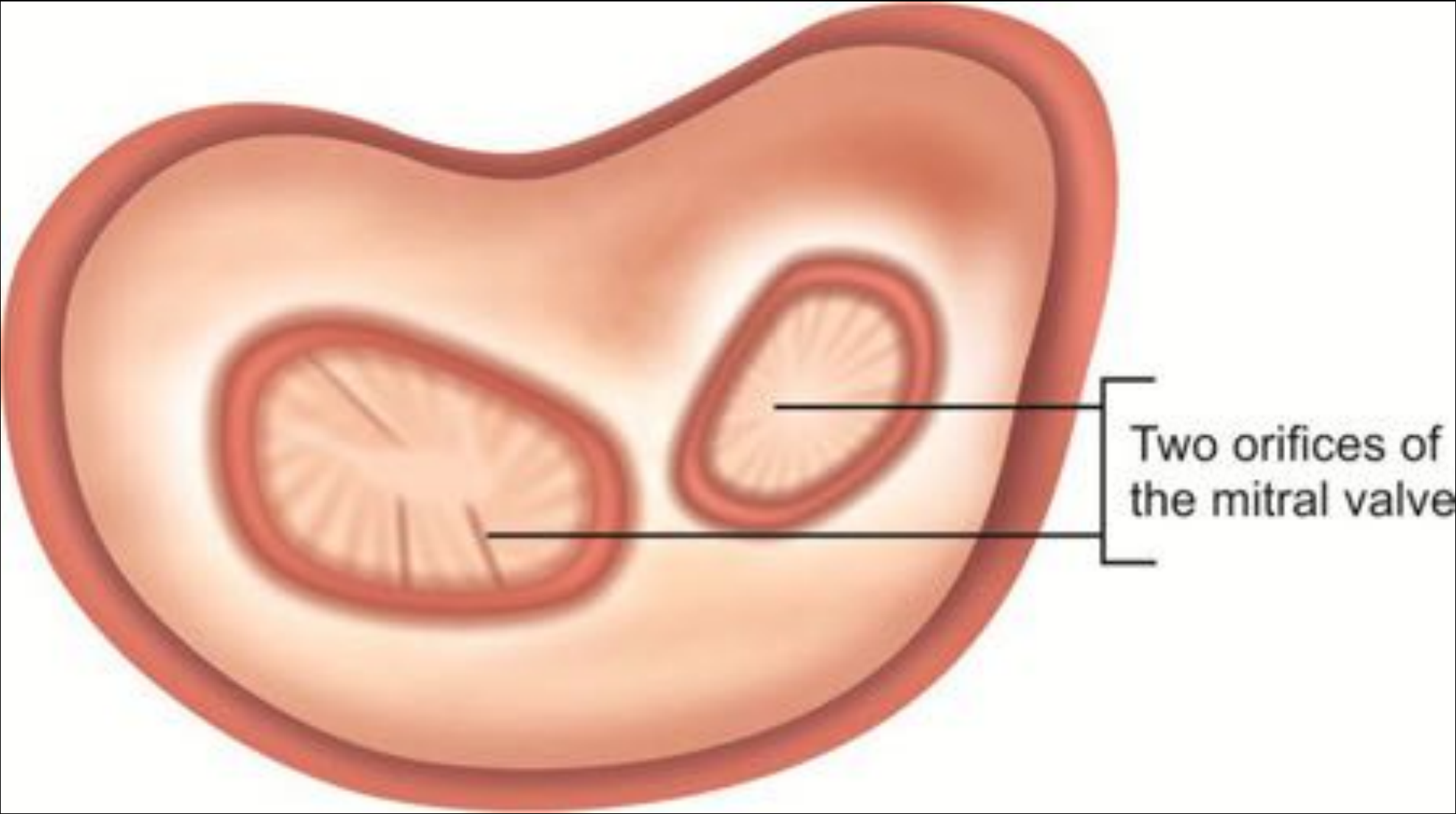



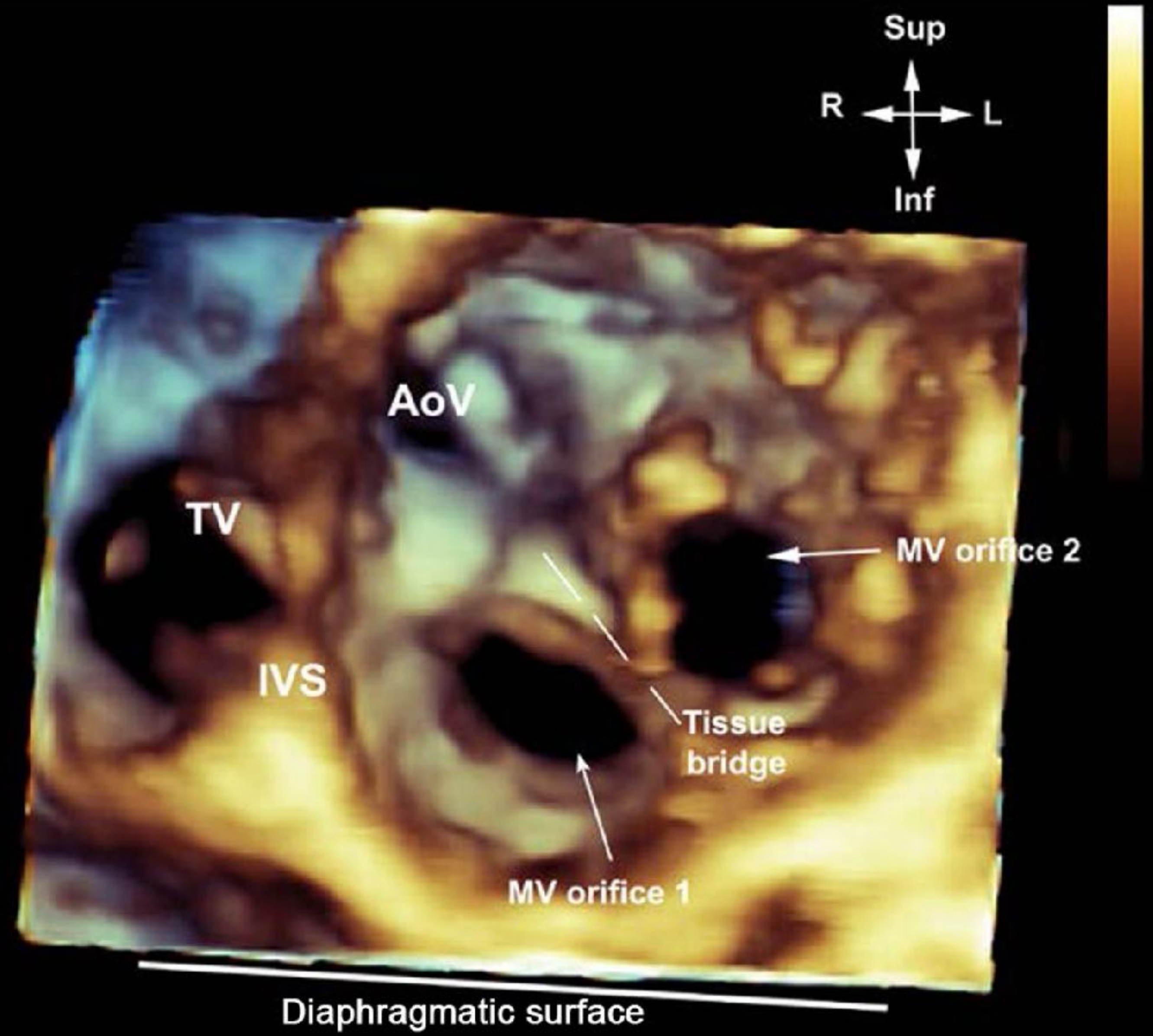
AVSD type



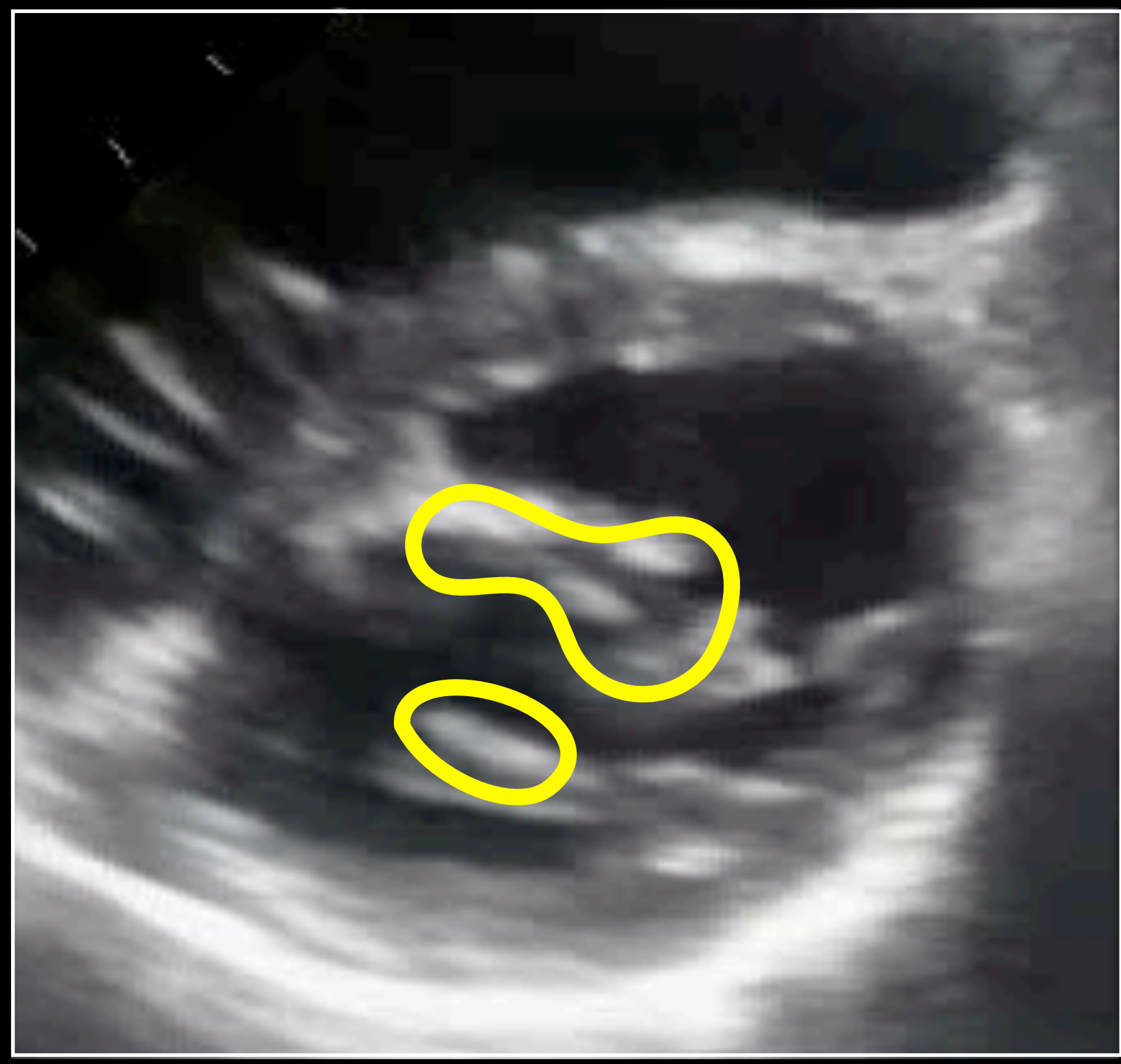
Outlet type

# Double orifice



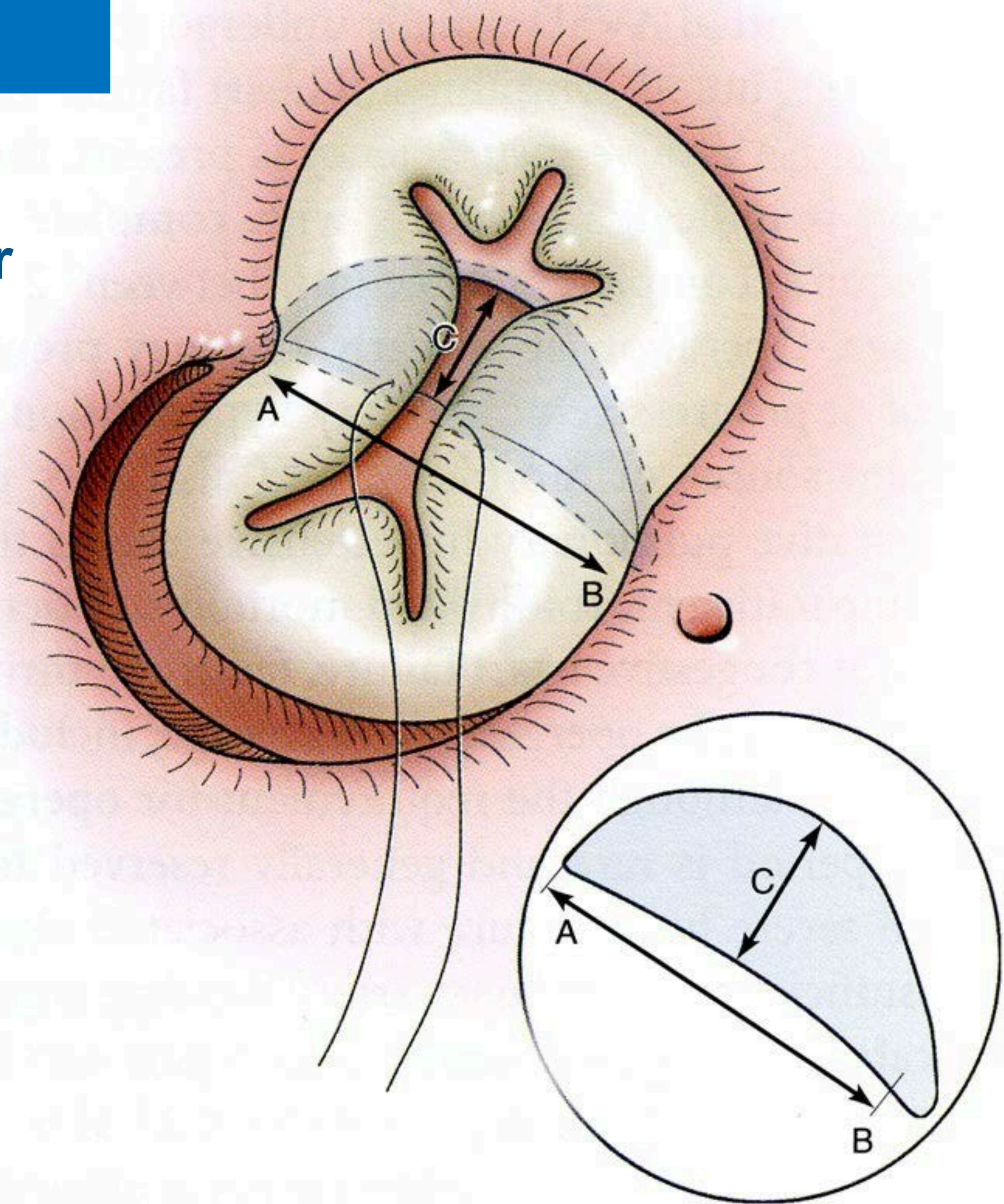


# Double orifice - Cleft of the anterior orifice



# Réparation des CAV

Le patch de CIV est inséré sur la crête septale

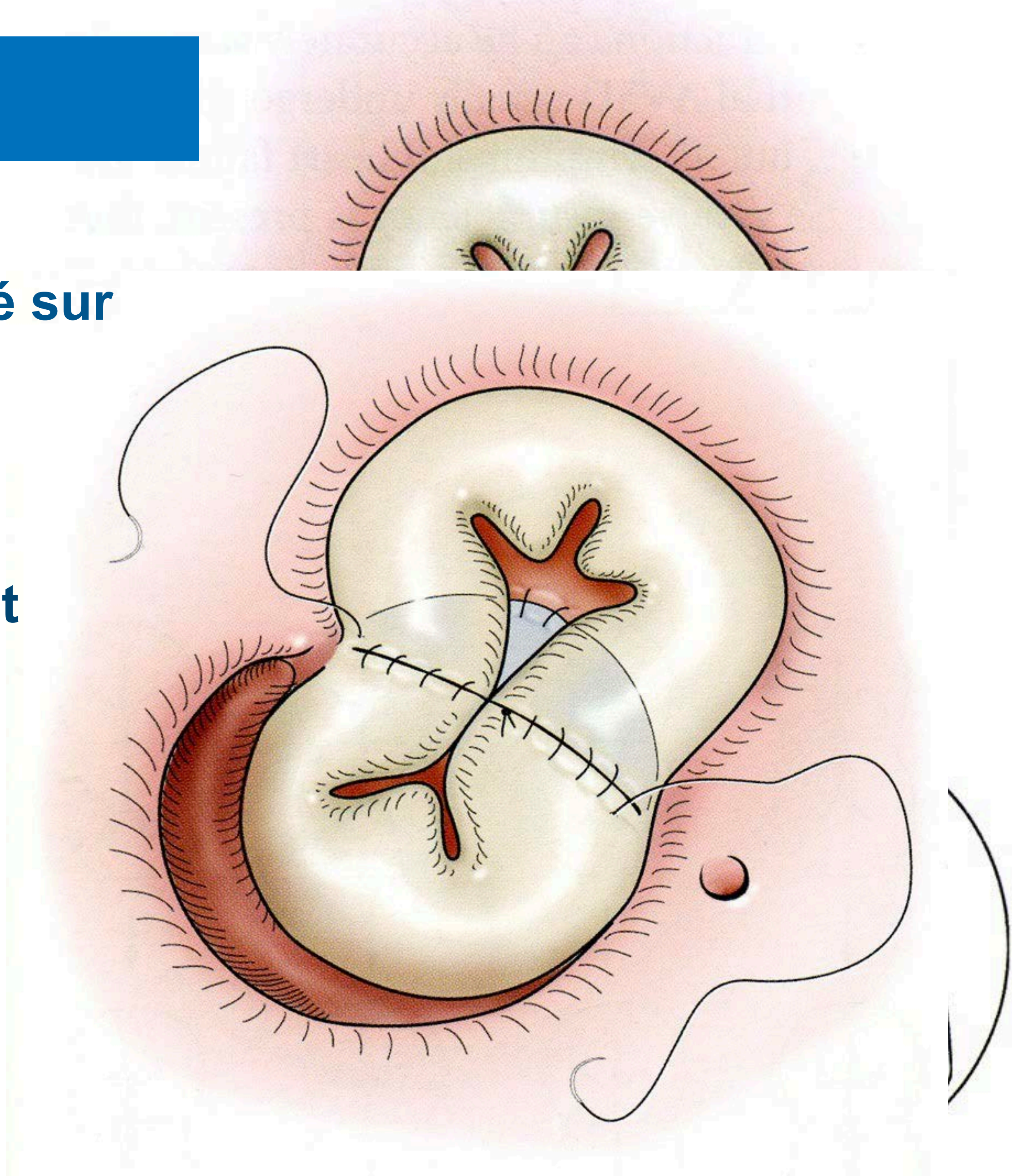


# Réparation des CAV

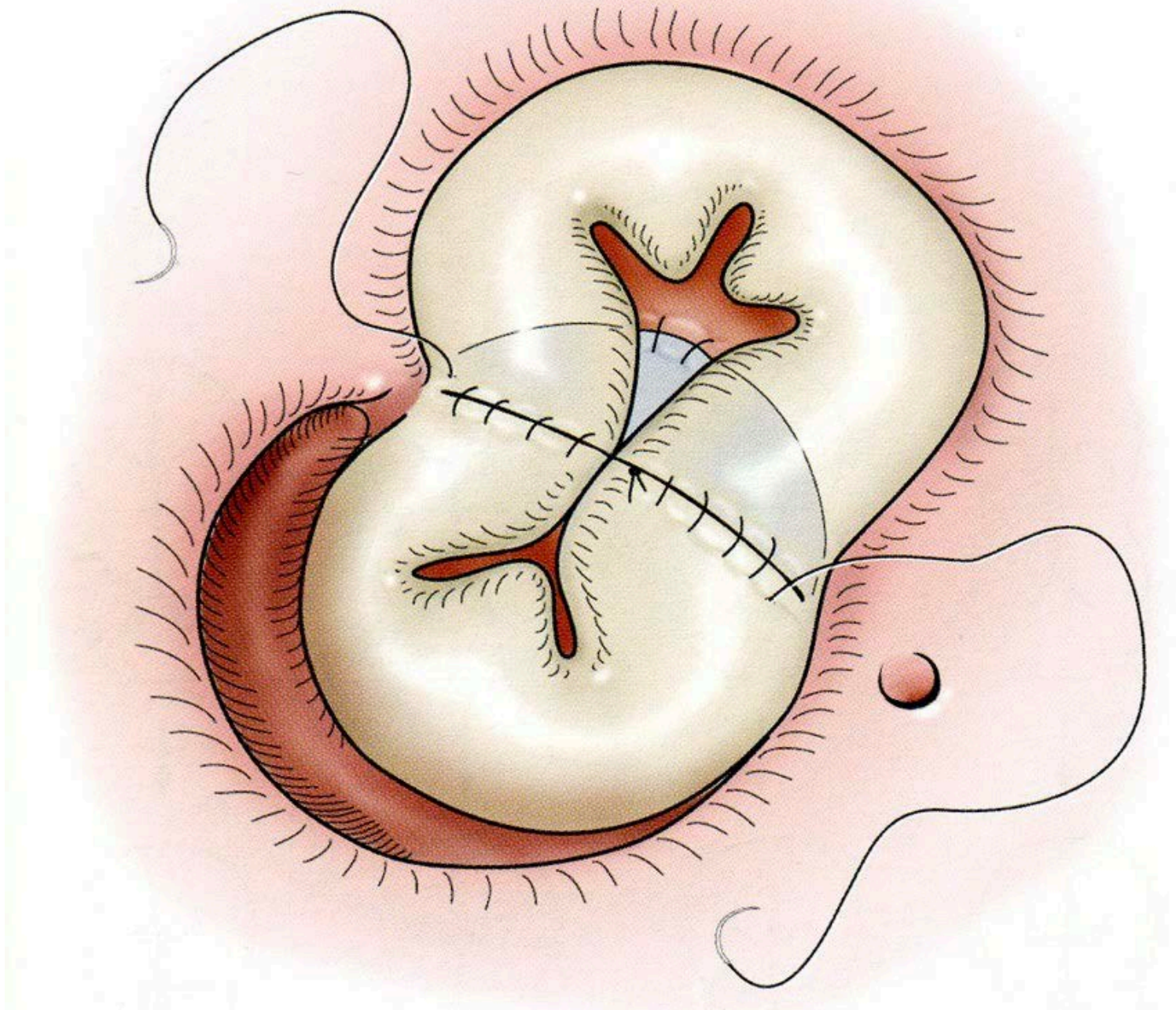
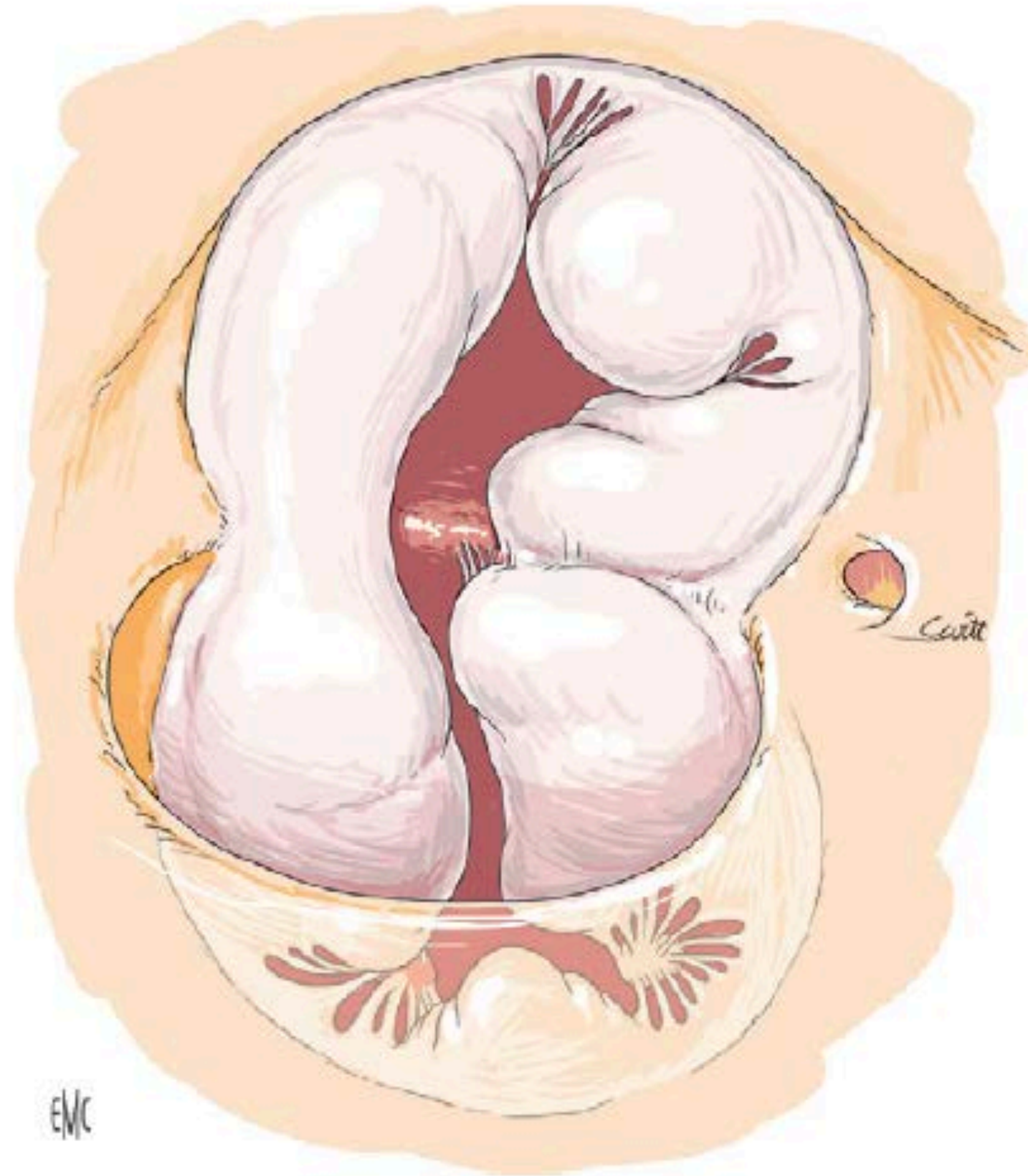**Le patch de CIV est inséré sur la crête septale**

**Puis**

**Les deux Hémivalves sont insérées sur le patch**



# Réparation des CAV

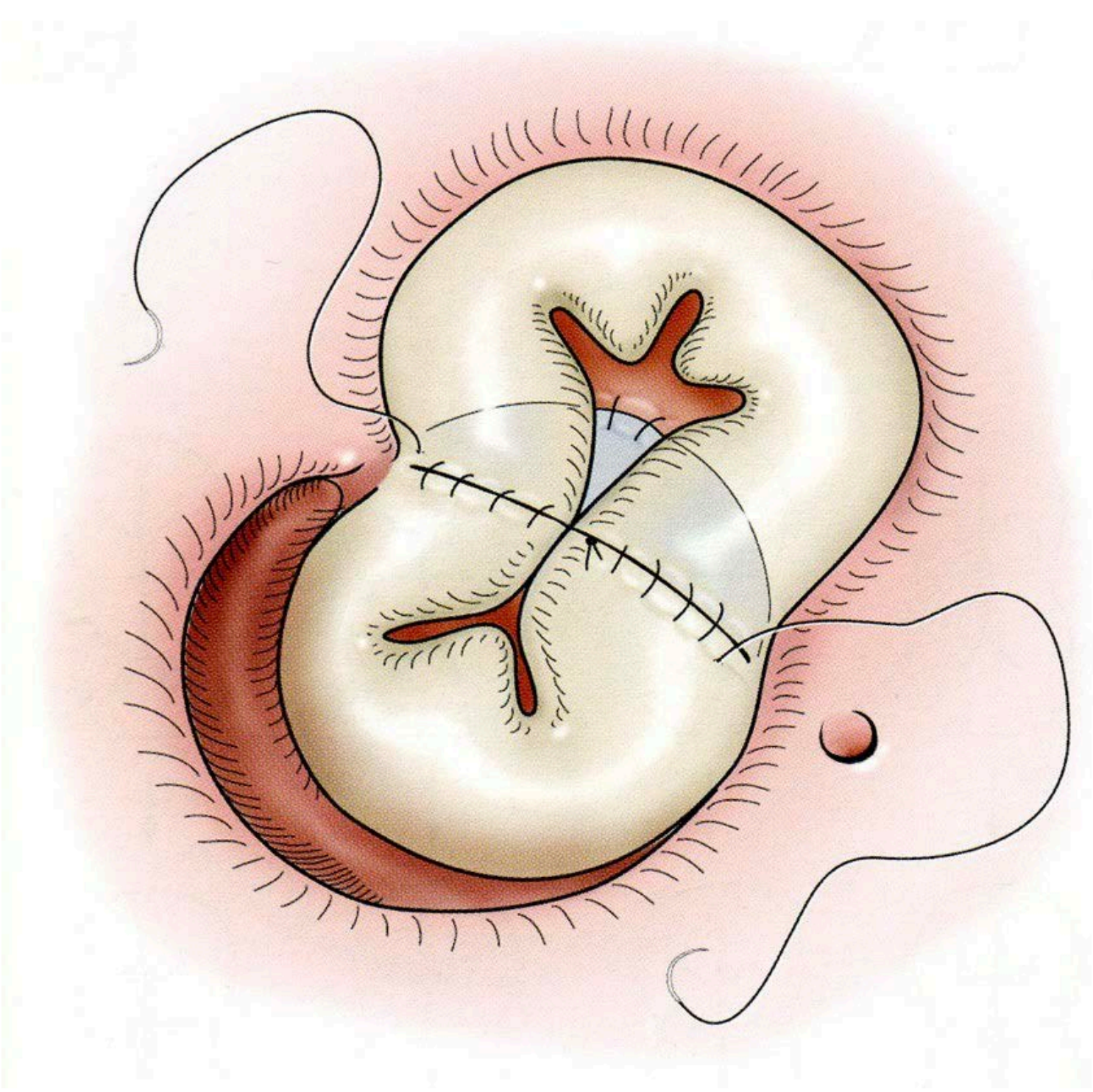
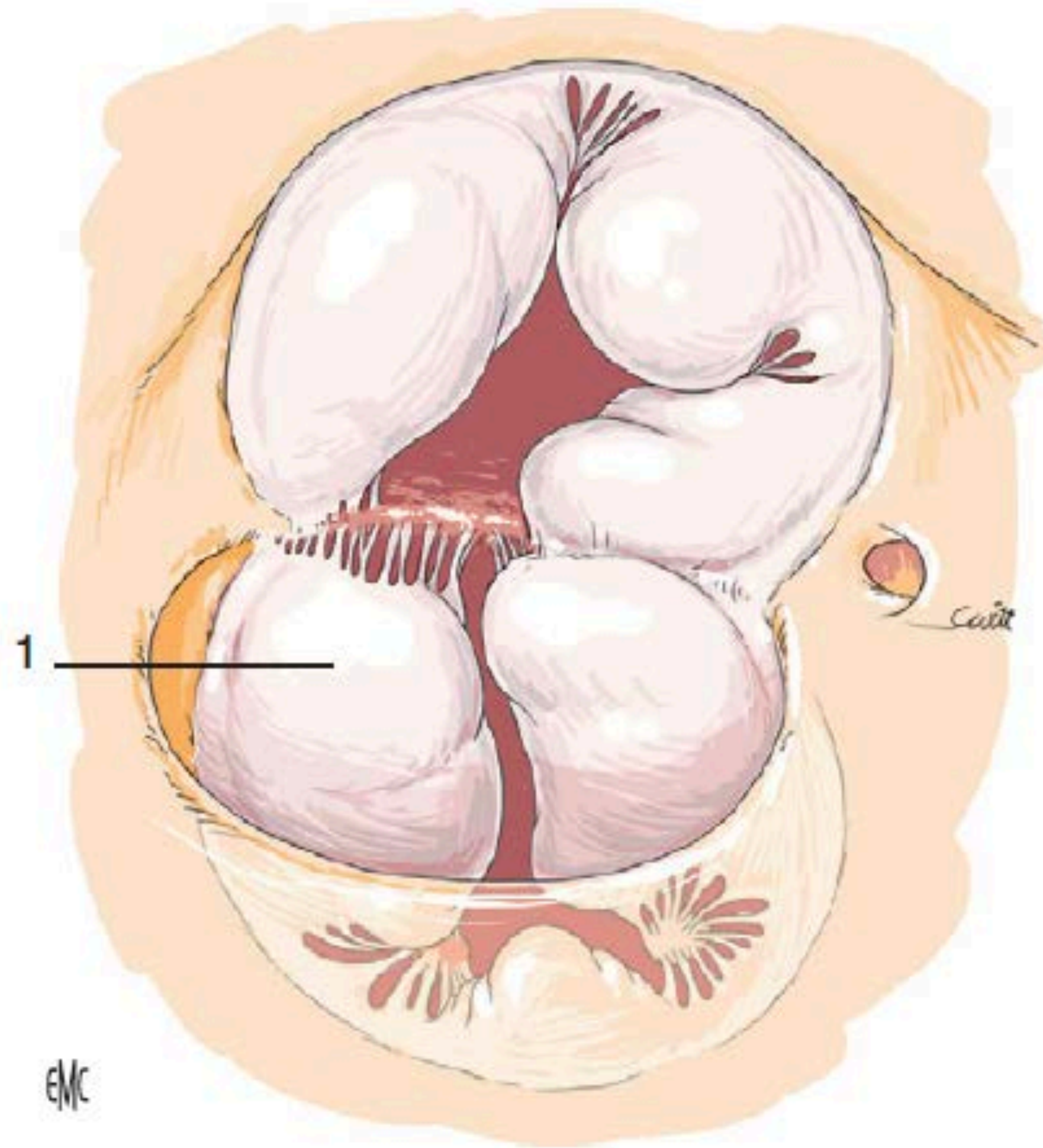


## Rastelli C

**Le patch de CIV est passé sous le bridging leaflet**



# Réparation des CAV



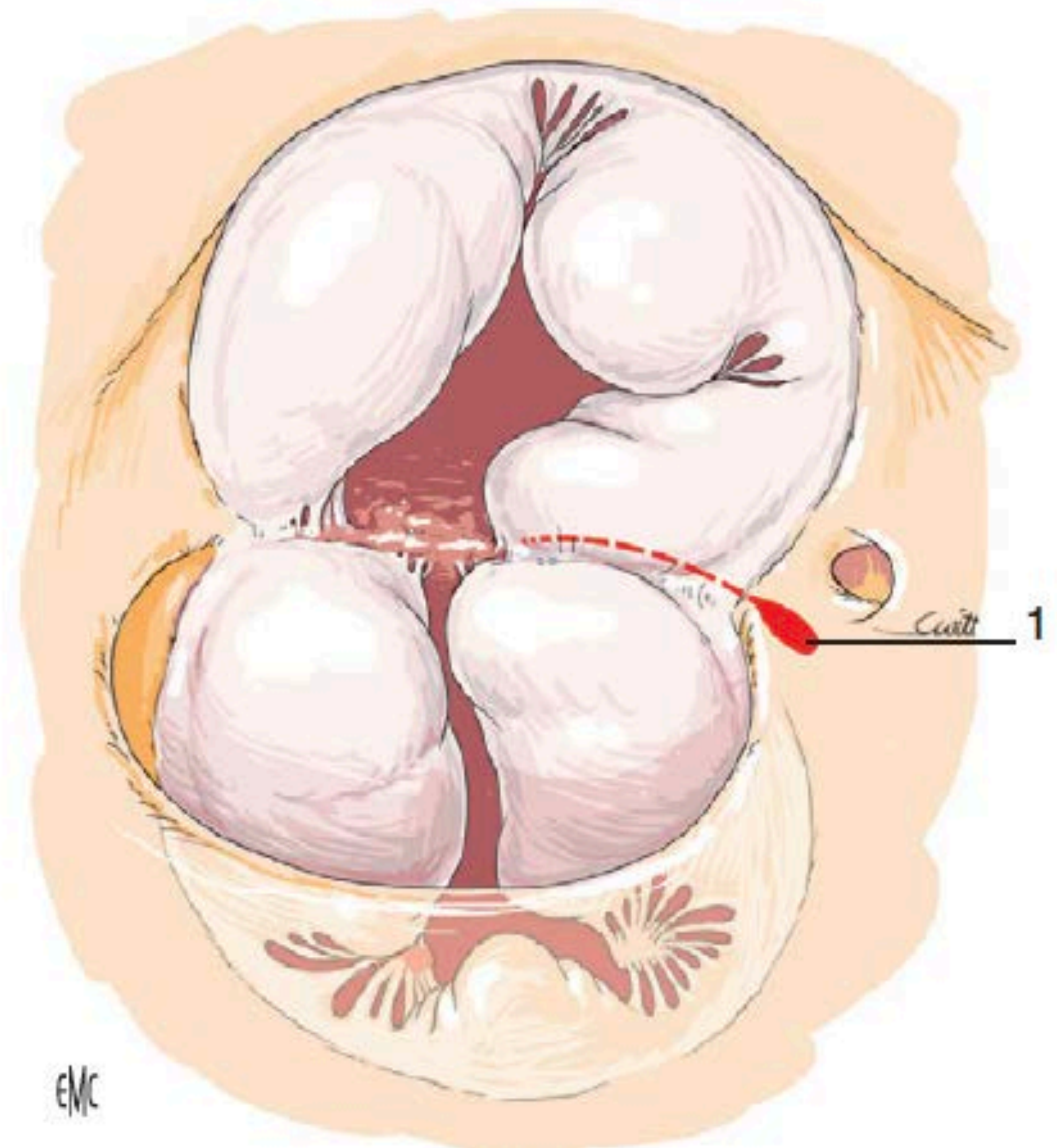
## Rastelli A

**Le patch de CIV laisse toutes les attaches septales du côté gauche**

# Réparation des CAV

CIA

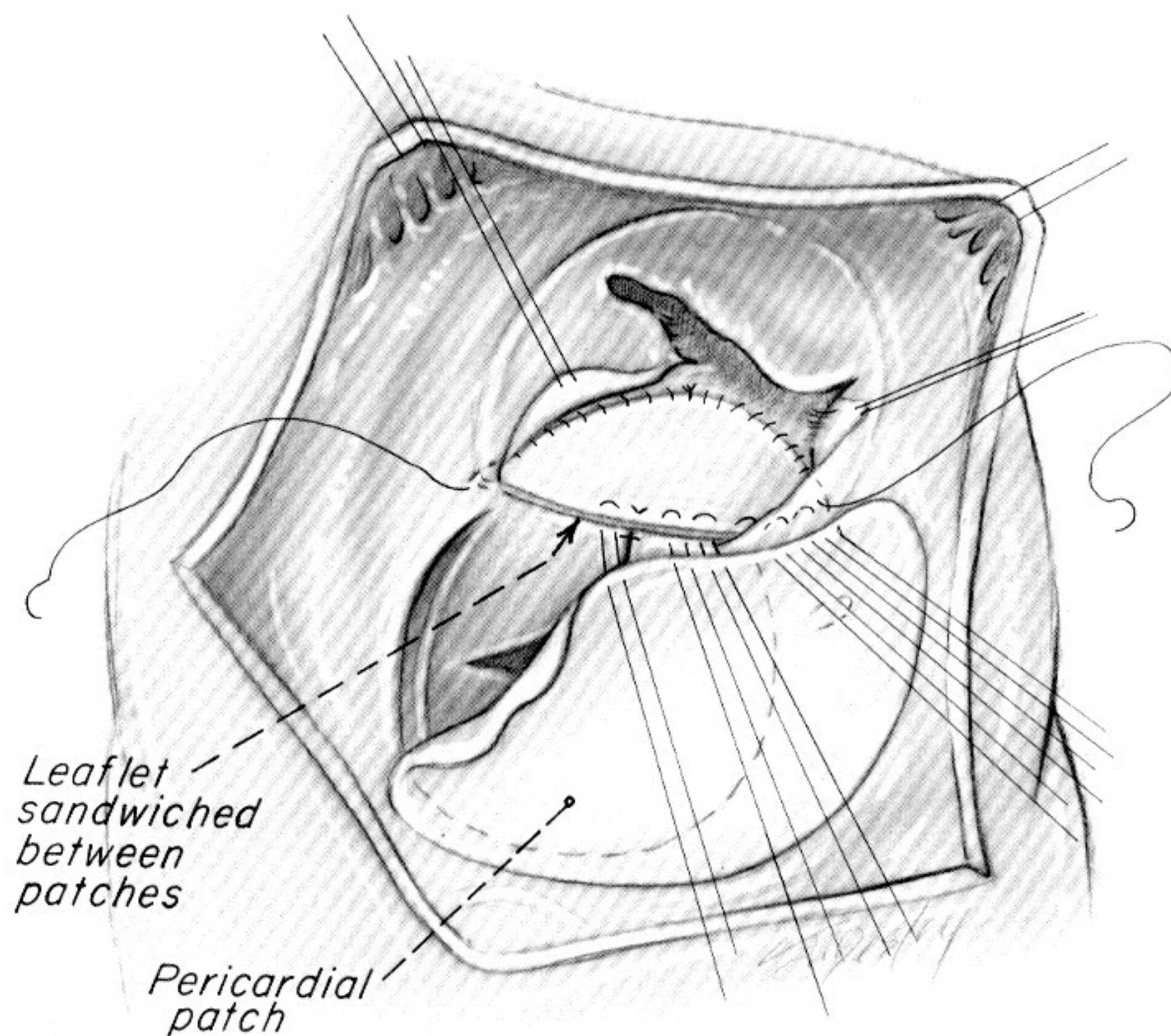
**Voies de conduction**



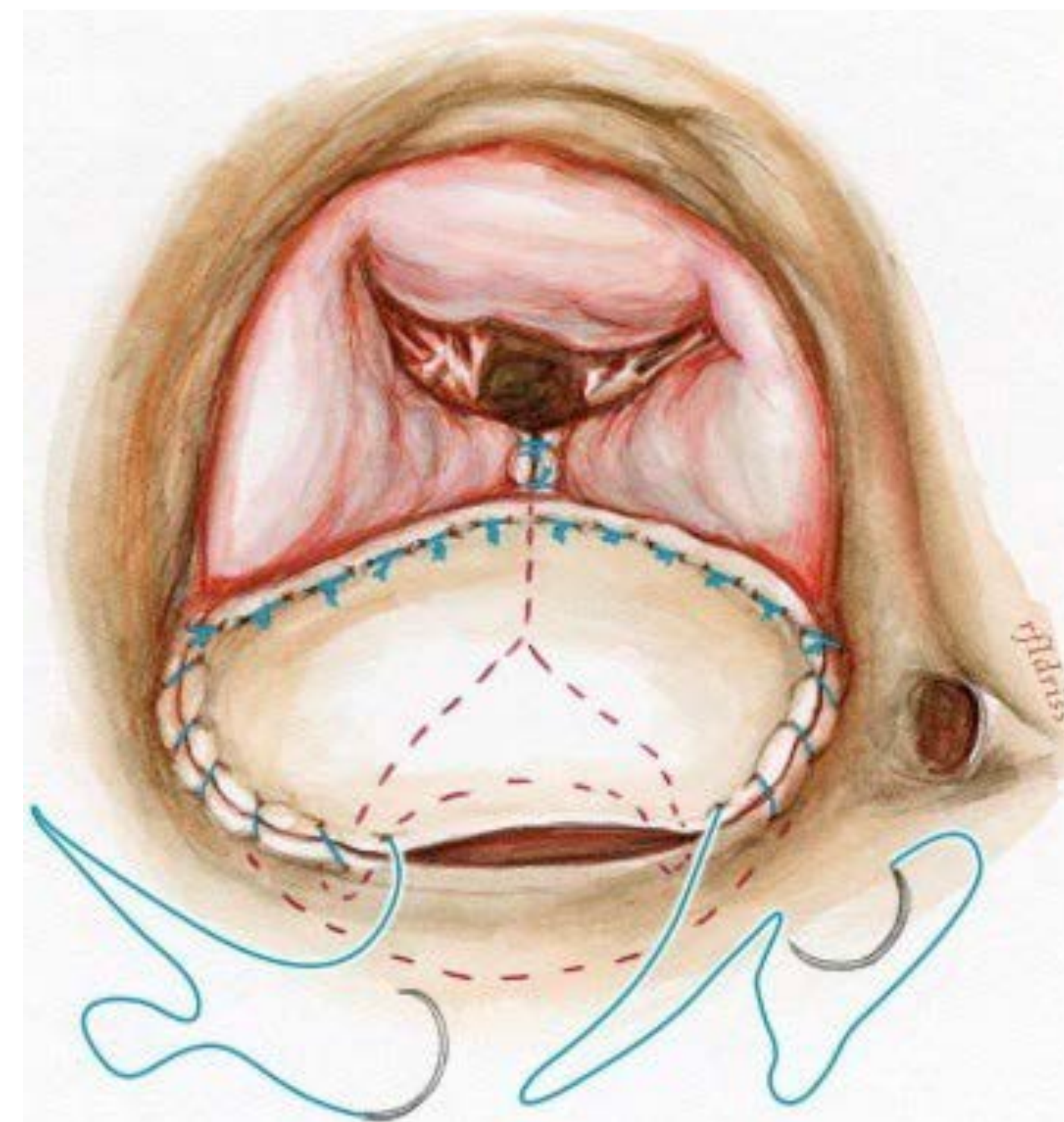
# Réparation des CAV

CIA Voies de conduction

A gauche

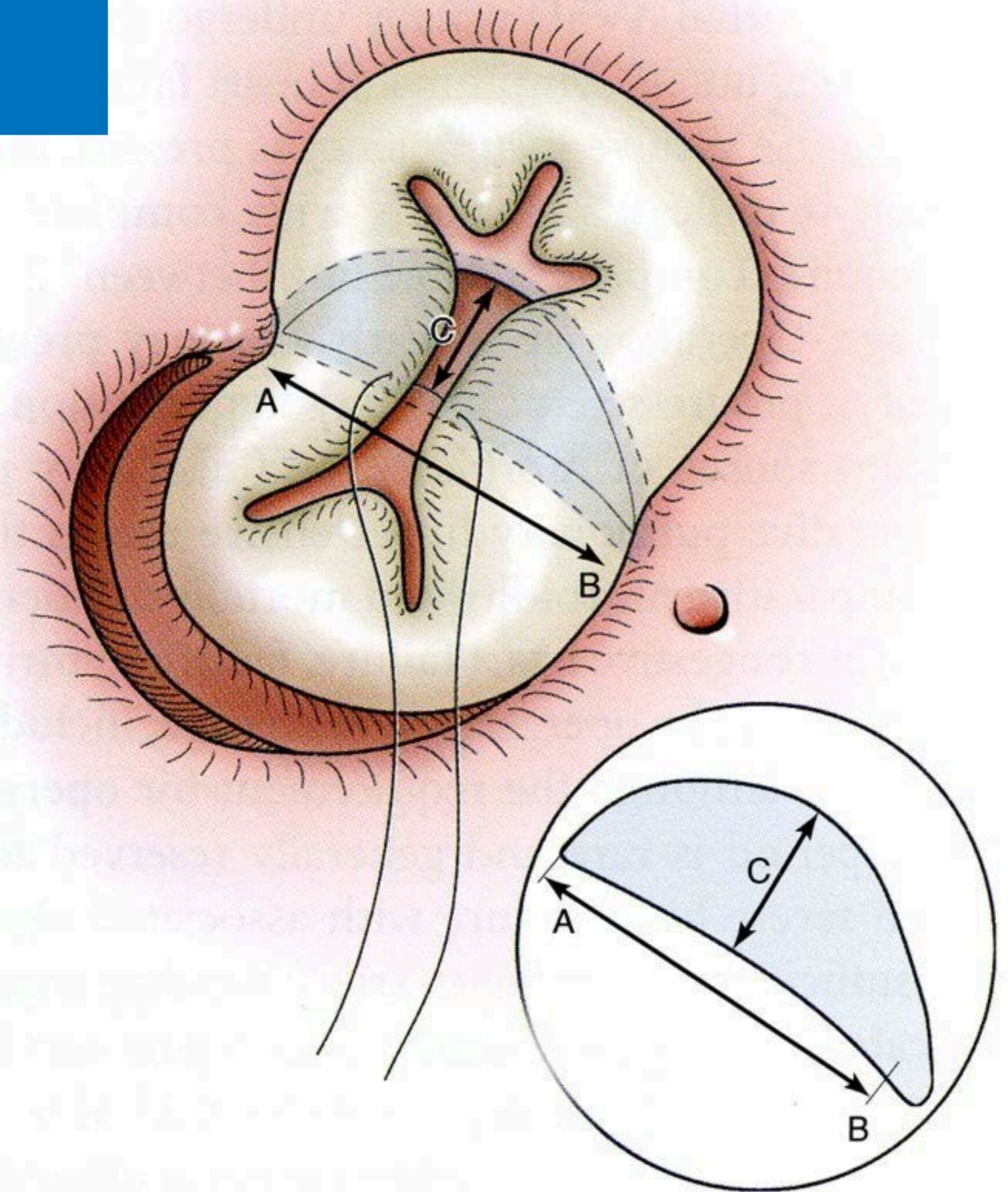


A droite

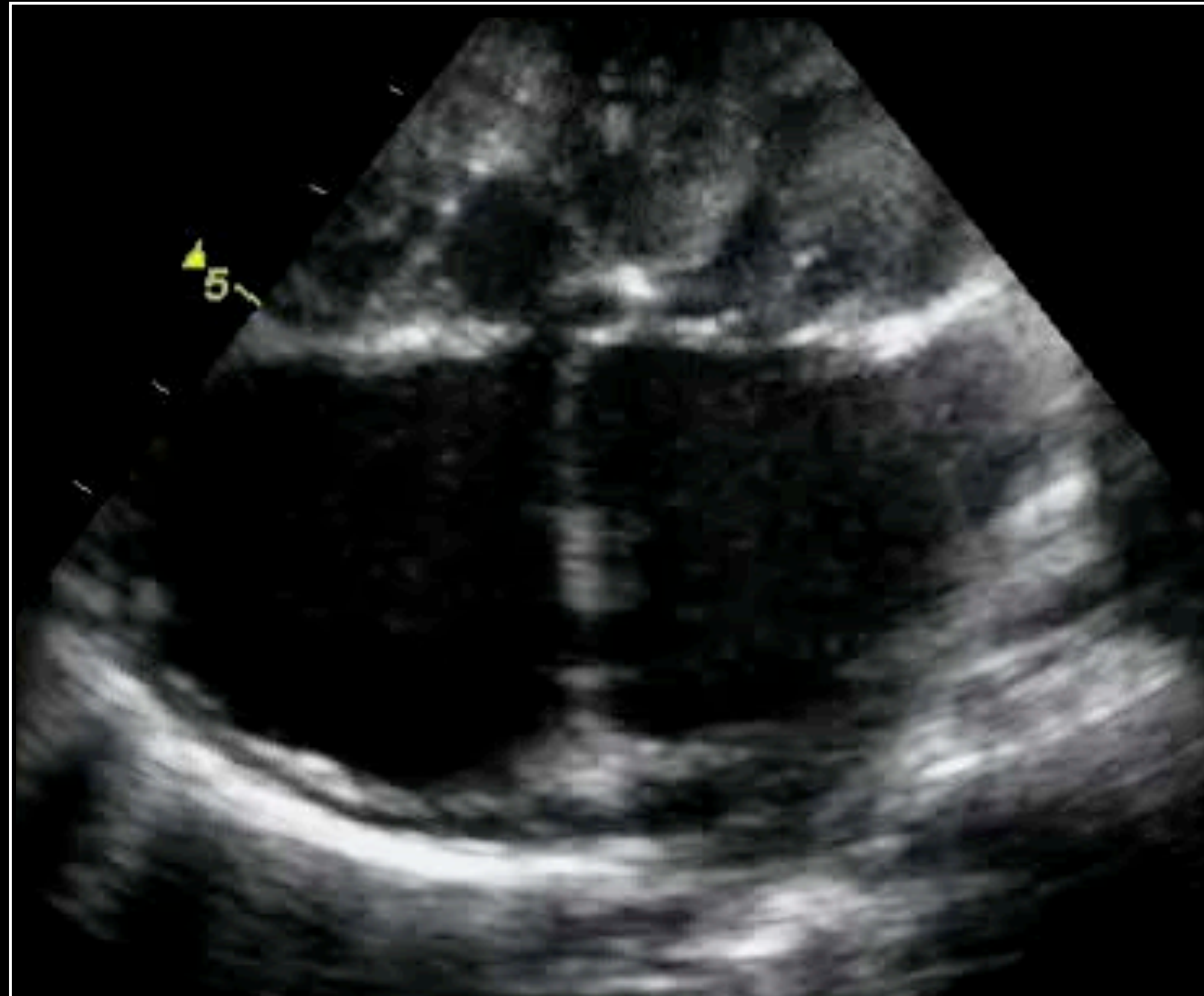


# Réparation des CAV

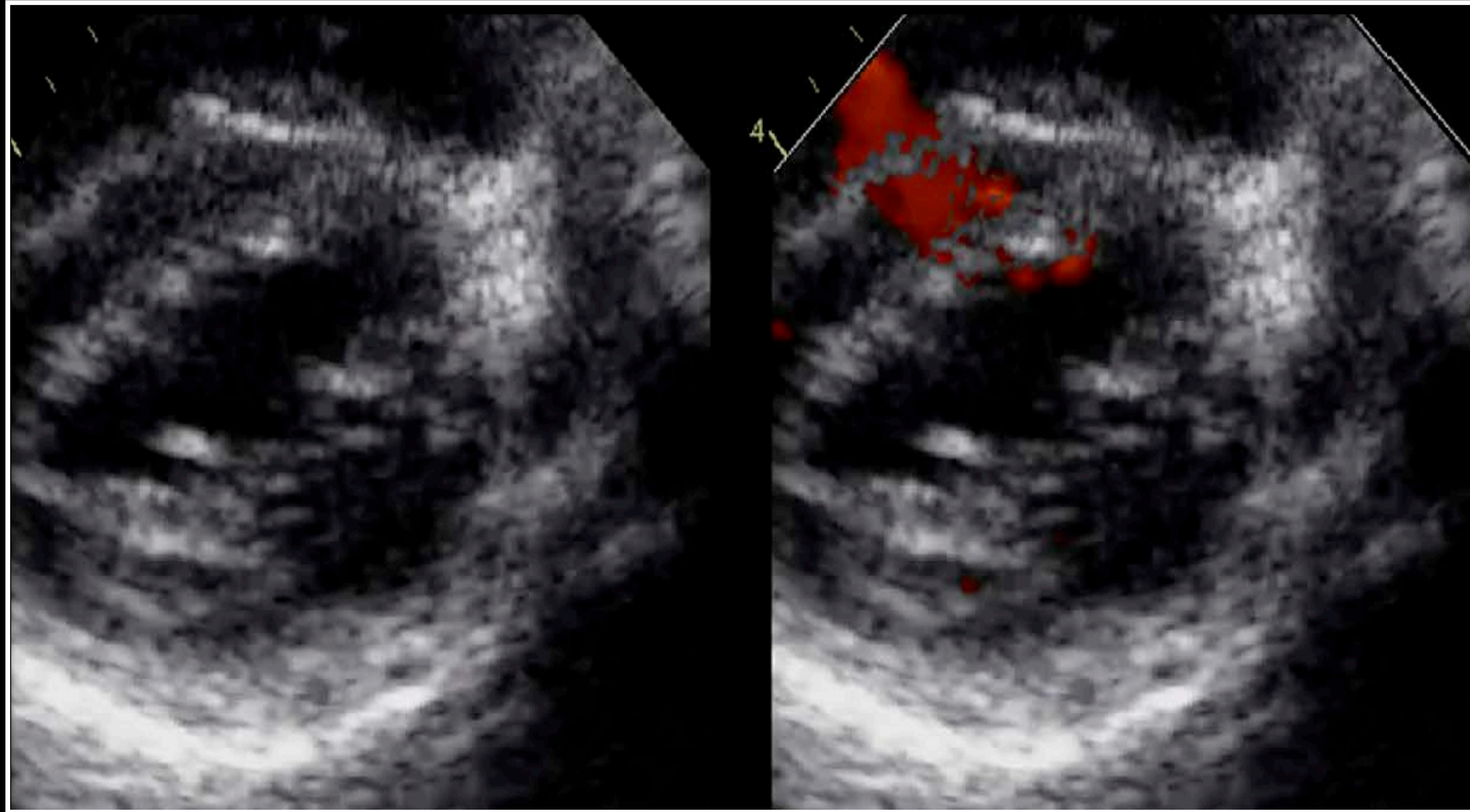
## Réparation des valves



# AVSD post-repair

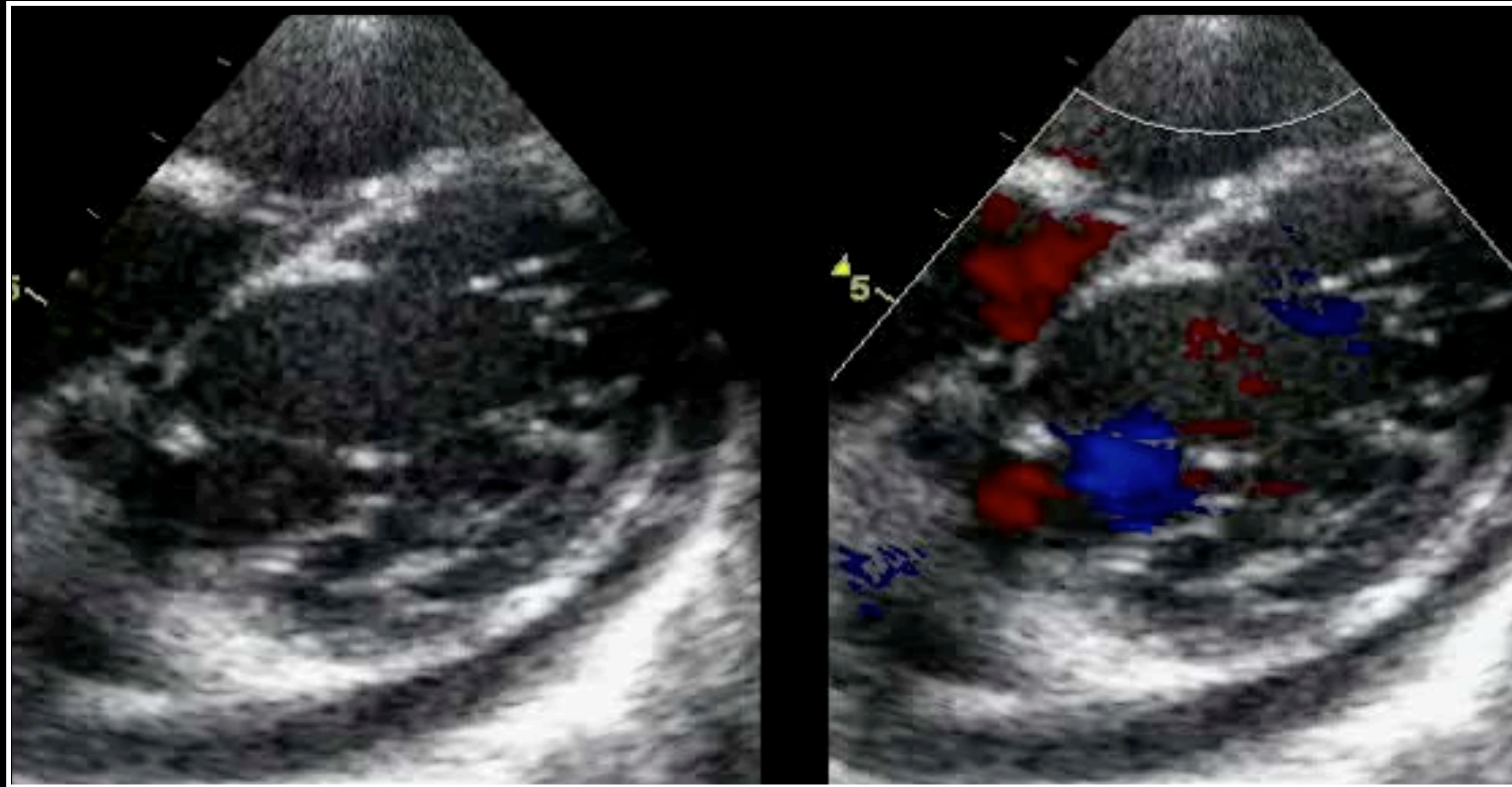


# AVSD post-repair



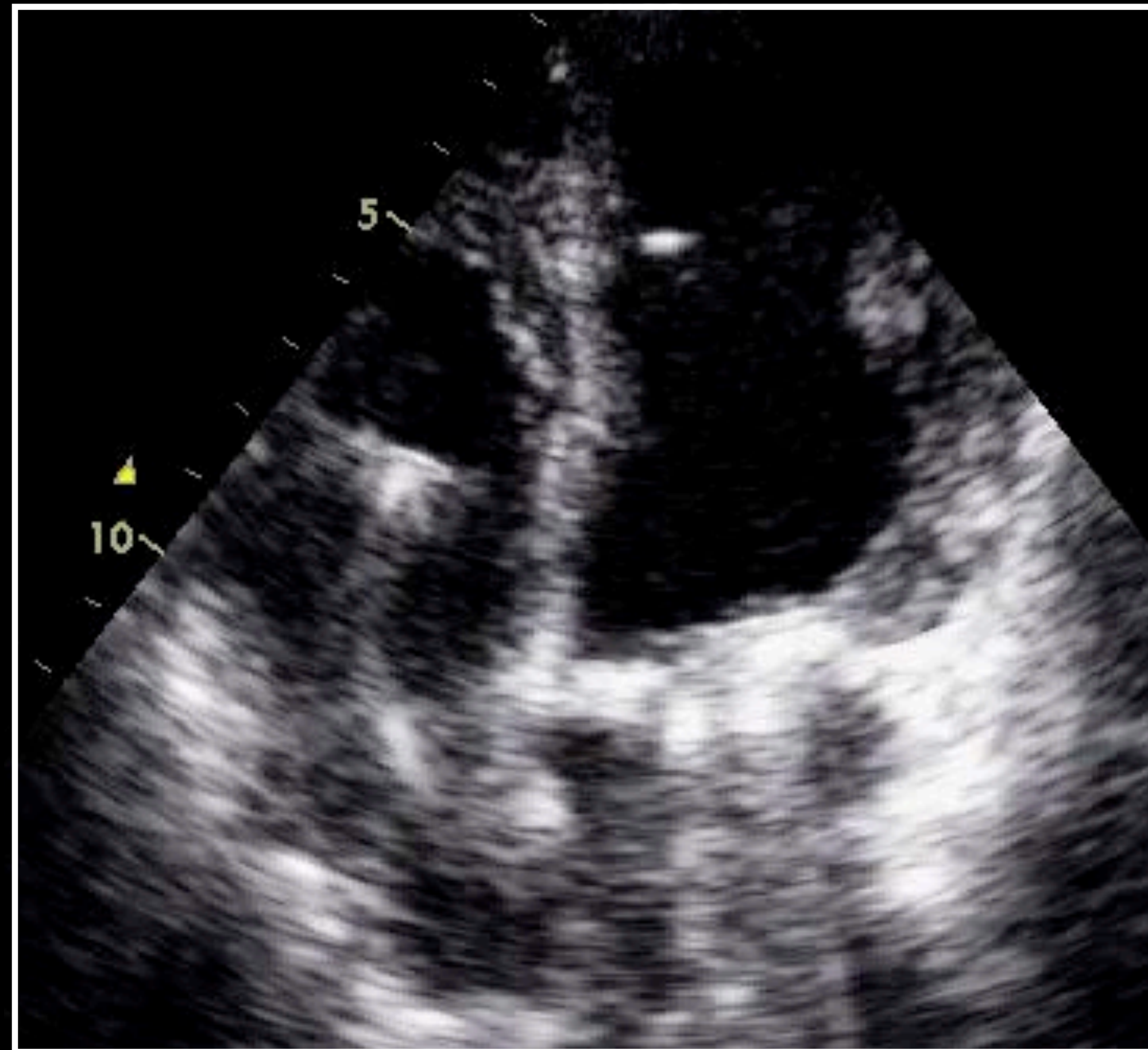
# AVSD post-repair

Mitral regurgitation - VSD leak



# AVSD post-repair

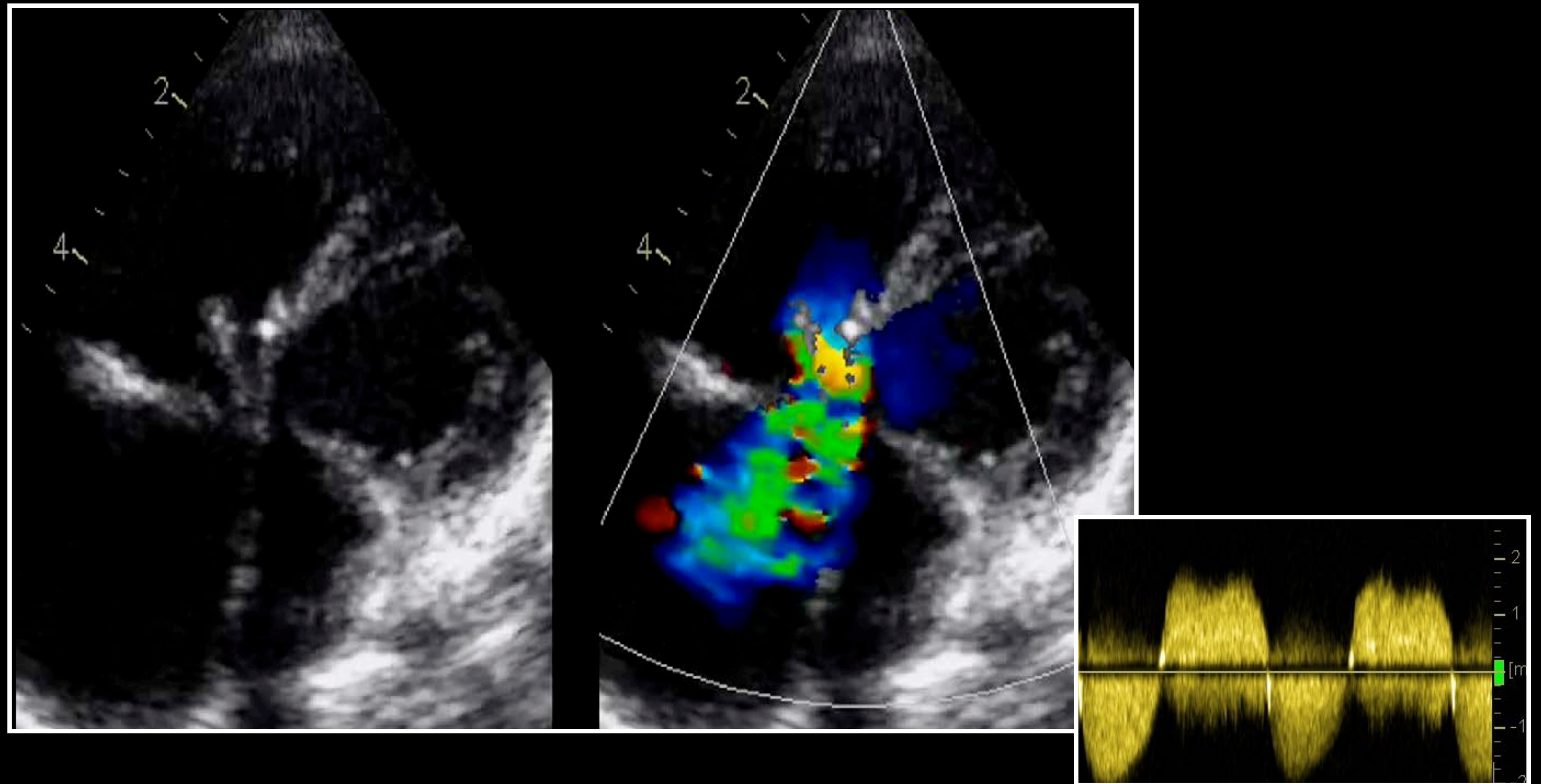
## Mitral prosthesis - Pace-maker





# AVSD post-repair

## Tricuspid regurgitation and stenosis





**CPC**  
**Cardiomyopathies**  
**Paris**  
**Centre**



Collective ignorance is our motivation  
Curiosity is our strength  
Research is our path

Individual experience is the brake  
Indifference is the weakness  
Argument from authority is the threat