

# Gastrointestinal Symptoms Followed by Shock in a Febrile 7-Year-Old Child during the COVID-19 Pandemic

Slimane Allali,<sup>a</sup> Jérémie F. Cohen ,<sup>a,b,\*</sup> Joséphine Brice,<sup>a</sup> Diala Khraiche,<sup>c</sup> and Julie Toubiana<sup>a,d</sup>

## CASE DESCRIPTION

In April 2020, during the national lockdown due to the coronavirus disease-2019 (COVID-19) pandemic, a 7-year-old boy of Congolese descent, without any relevant family or personal history, presented to the pediatric emergency department of our hospital in Paris, France, after 5 days of fever. He had developed a transient rash of upper extremities, abdominal pain, vomiting and diarrhea on the day of his admission. Physical examination revealed findings suggestive of an acute abdomen, cervical lymphadenopathy, and neck stiffness. Laboratory evaluations showed mild leukopenia (white blood cells  $5.1 \times 10^9/L$ ; reference,  $5.5\text{--}15.5 \times 10^9/L$ ), lymphopenia (lymphocytes  $0.3 \times 10^9/L$ ; reference,  $1.5\text{--}6.5 \times 10^9/L$ ), microcytic (mean corpuscular volume 59 fL; reference 77–86 fL) anemia (hemoglobin 8.6 g/dL; reference 11.5–13.5 g/dL), thrombocytopenia (platelets  $110 \times 10^9/L$ ; reference,  $175\text{--}420 \times 10^9/L$ ), hyponatremia (sodium 126 mmol/L; reference 136–146 mmol/L), and increased C-reactive protein level (CRP 101 mg/L; reference <6.0 mg/L). A lumbar puncture showed no cerebrospinal fluid abnormalities. An abdominal CT scan revealed moderate peritoneal effusion and gallbladder hydrops, together with basal lung opacities suggestive of COVID-19. Nasopharyngeal RT-PCR testing for severe acute respiratory syndrome coronavirus 2 (SARS-CoV-2) (SARS-CoV-2 R-GENE, Argene; bioMérieux) was positive.

A few hours after admission, the patient developed signs of shock with tachycardia (heart rate 140 bpm) and arterial hypotension (62/37 mmHg), requiring

## QUESTIONS TO CONSIDER

- What are the leading causes of shock with fever and rash in otherwise healthy children?
- What are the distinctive features of Kawasaki disease-like illness related to SARS-CoV-2 compared with classic Kawasaki disease?
- Why did the patient's symptoms resolve following IVIG infusion?

intravenous fluid resuscitation. The clinician in charge suspected septic shock or toxic shock syndrome and started empiric broad-spectrum intravenous antibiotic therapy, after collecting blood and urine bacteriological samples, which remained sterile. The patient was transferred to the pediatric intensive care unit. Echocardiography indicated signs of pericarditis, and myocarditis with posterolateral hypokinesia and reduced left ventricular ejection fraction (LVEF 30%, reference >50%). Concentrations of troponin I and B-type natriuretic peptide (BNP) were abnormally high, at 447 ng/L (reference, <26 ng/L) and 6503 ng/L (reference, <100 ng/L), respectively (Table 1). Vasoactive and inotropic agents (i.e., epinephrine and milrinone) were used for a mixed vasoplegic and cardiogenic shock. The patient needed mechanical ventilation for cardiovascular compromise.

On the 6th day of fever, the patient developed a strawberry tongue and erythema with cracking of lips, together with bilateral conjunctivitis. Kawasaki disease (KD) was suspected, and additional treatment with intravenous immunoglobulins (IVIG) was administered at a dose of 2 g/kg. Anti-SARS-CoV-2 IgG testing (Architect SARS-CoV-2 immunoassay; Abbott) was positive. Nasopharyngeal RT-PCR testing for SARS-CoV-2 was found negative on days 5 and 8 of the hospital stay. Nasopharyngeal testing for other viruses was negative. The patient reported no recent history of viral illness, but his mother had presented viral-like symptoms consistent with COVID-19 about 40 days before the onset of fever. The patient improved dramatically

<sup>a</sup>Department of General Pediatrics and Pediatric Infectious Diseases, Necker-Enfants-Malades University Hospital, Assistance Publique-Hôpitaux de Paris (AP-HP), Université de Paris, Paris, France; <sup>b</sup>Université de Paris, Centre of Research in Epidemiology and Statistics (CRESS), INSERM, F-75004 Paris, France; <sup>c</sup>M3C-Necker, Congenital and Pediatric Cardiology, Necker-Enfants Malades University Hospital, Assistance Publique-Hôpitaux de Paris (AP-HP), Université de Paris, Paris, France; <sup>d</sup>Institut Pasteur, Biodiversity and Epidemiology of Bacterial Pathogens, Paris, France.

\*Address correspondence to this author at: Department of General Pediatrics and Pediatric Infectious Diseases, Necker Hospital for Sick Children, 75015 Paris, France. Fax 33-0-143268979; email jeremie.cohen@inserm.fr.

Received August 12, 2020; accepted October 19, 2020.

DOI: 10.1093/clinchem/hvaa279

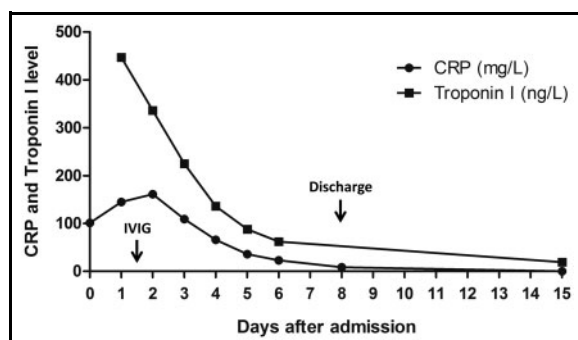
©American Association for Clinical Chemistry 2021. All rights reserved.

For permissions, please email: journals.permissions@oup.com.

**Table 1 Laboratory results.**

Marker	Reference interval <sup>a</sup>	Results <sup>b</sup>
White blood cells	5.5-15.5 x 10 <sup>9</sup> /L	5.1
Neutrophils	1.8-8.0 x 10 <sup>9</sup> /L	9.6
Lymphocytes	1.5-6.5 x 10 <sup>9</sup> /L	0.3
Hemoglobin	11.5-13.5 g/dL (1.15-1.35 g/L)	5.3 (0.53)
Platelets	175-420 x 10 <sup>9</sup> /L	108
C-reactive protein	<6.0 mg/L	160
Procalcitonin	<0.5 µg/L	31
IL-1β <sup>c</sup>	<15 pg/mL	5.8
IL-6 <sup>c</sup>	<8.5 pg/mL	162
TNF-α <sup>c</sup>	<20 pg/mL	75
Albumin	35-50 g/L	16
Sodium	136-146 mmol/L	126
Potassium	3.1-4.7 mmol/L	2.6
Creatinine	0.34-0.54 mg/dL (30-48 µmol/L)	0.45 (40)
Aspartate transaminase	9-45 Units/L	92
Alanine transaminase	7-40 Units/L	37
γ-glutamyl transferase	5-25 Units/L	72
Bilirubin, total	<1.0 mg/dL (<17 µmol/L)	0.35 (6)
Lipase	7-60 Units/L	527
Lactate dehydrogenase	125-243 Units/L	446
Lactate (venous plasma)	4.0-15.8 mg/dL (0.45-1.75 mmol/L)	33.3 (3.7)
D-dimers	<500 µg/L	5653
Fibrinogen	150-350 mg/dL (1.5-3.5 g/L)	470 (4.7)
Prothrombin time	>70%	48
Creatine kinase	30-180 units/L	561
High sensitivity cardiac troponin I <sup>d</sup>	<26 ng/L	447
B-type natriuretic peptide <sup>e</sup>	<100 ng/L	6503

<sup>a</sup>Results listed using conventional units (SI units);  
<sup>b</sup>Most abnormal value;  
<sup>c</sup>IL, interleukin; TNF, tumor necrosis factor;  
<sup>d</sup>Architect *STAT* High Sensitive Troponin-I (Abbott Laboratories): chemiluminescent microparticle immunoassay, imprecision profile with total CV ≤ 10% for sample values between 10 and 50 000 ng/L, limit of detection between 1.1 and 1.9 ng/L, concentration at 10% CV of 4.7 ng/L and at 99th percentile of 26.2 ng/L [i.e., 4.0% CV] (according to the manufacturer);  
<sup>e</sup>Architect BNP (Abbott Laboratories): chemiluminescent microparticle immunoassay, upper 95% confidence interval imprecision of ≤ 12% total CV (according to the manufacturer).



**Fig. 1.** Case timeline with key clinical events and levels of CRP and Troponin I. CRP: C-reactive protein level. IVIG: intravenous immunoglobulins.

after IVIG, with a pyrexia, resolution of clinical signs and normalization of LVEF within 36 hours. Troponin I and CRP concentrations decreased quickly (Fig. 1). Increased coronary visibility was observed on echocardiography on day 3, and left coronary dilation (Z-score 2 SD) on day 8 of hospital stay.

## DISCUSSION

This child was finally diagnosed with KD-like multisystem inflammatory syndrome, which was regarded as triggered by recent SARS-CoV-2 infection. This was one of the earliest cases, occurring even before the first alerts on KD-like illness related to SARS-CoV-2.

### Kawasaki Disease and Kawasaki Disease Shock Syndrome

KD is an acute multisystem vasculitis, affecting predominantly children < 5 years of age with an annual incidence of approximately 25 per 100 000 in Western countries, and a 10-fold higher incidence in Japan (1). KD is responsible for coronary artery aneurysms in around 25% of untreated cases and is the first cause of acquired heart disease in children in high-income countries (1). The diagnosis of complete KD is based on the presence of fever persisting for more than 4 days, together with at least 4 of the 5 following criteria: 1) oral changes (erythema and cracking of lips, strawberry tongue, and/or erythema of oral and pharyngeal mucosa), 2) cervical lymphadenopathy ( $\geq 1.5$  cm diameter), 3) bilateral conjunctivitis without exudate, 4) polymorphous exanthema, and 5) extremity changes (erythema and edema and/or periungual desquamation) (1). If criteria for complete KD are not met, the diagnosis of incomplete KD can be made on the presence of clinical, laboratory, and echocardiographic findings, such as extreme irritability, gastrointestinal symptoms,

desquamating rash, biological inflammation, anemia, hypoalbuminemia, liver test abnormalities, hyponatremia, myocarditis, or coronary artery abnormalities (1). Therefore, KD was highly probable in our patient, even at initial presentation.

Because he developed shock, the differential diagnosis included bacterial sepsis, toxic shock syndrome, and cardiogenic shock secondary to viral myocarditis. The negative results of bacterial cultures and the rapid decrease of inflammatory and cardiac biomarkers after IVIG infusion were not consistent with these hypotheses. KD shock syndrome (KDSS) is a severe complication of KD, which usually combines decreased peripheral vascular resistance and low left ventricular contractility in the context of myocarditis, thus requiring fluid resuscitation together with vasoactive and inotropic agents (2). KDSS affects 1.5% to 7% of patients with KD and is associated with older age, more frequent gastrointestinal symptoms, higher levels of inflammatory markers (e.g., CRP, procalcitonin (PCT) and IL-6), higher D-dimer, lower hemoglobin and albumin levels, more severe hyponatremia and hypokalemia, and more frequent coronary abnormalities than classic KD (3).

### Kawasaki Disease-Like Illness Related to SARS-CoV-2, MIS-C and PIMS-TS

During the COVID-19 pandemic, several pediatric teams reported cases of severe KD-like illness with myocarditis and shock in children and adolescents with laboratory evidence of recent SARS-CoV-2 infection (4–7). These cases with complete or incomplete criteria for KD were considered part of a new hyperinflammatory syndrome with multiorgan involvement, named “multisystem inflammatory syndrome in children” (MIS-C) in the United States (8), and “pediatric inflammatory multisystem syndrome temporally associated with SARS-CoV-2 infection” (PIMS-TS) in Europe (9).

Compared with classic KD, these patients are older, more frequently of Sub-Saharan African ancestry, more often have gastrointestinal involvement, and noticeably more shock and myocarditis. They also tend to display more profound lymphopenia and unusually high levels of inflammatory markers (6). The patient reported here illustrates well this severe form of KD-like illness related to SARS-CoV-2. Gallbladder hydrops, liver test abnormalities, and pancreatitis are classic features of KD, reflecting acute vasculitis. Hypoalbuminemia is also common in children with KD-like illness, and may, together with lymphopenia, be at least partly attributed to severe protein-losing enteropathy, although the most common cause in KD is decreased synthesis in the acute phase.

Macrophage activation syndrome is a rare complication of KD (1). It was reported in several patients with KD-like illness related to SARS-CoV-2 (5), but

## POINTS TO REMEMBER

- Kawasaki disease is a common vasculitis in childhood that may be responsible for shock in up to 7% of patients.
- An outbreak of severe Kawasaki disease-like illness with myocarditis and shock, very similar to Kawasaki disease shock syndrome, is observed during the COVID-19 pandemic in children and adolescents with laboratory evidence of a recent SARS-CoV-2 infection.
- Compared with classic Kawasaki disease, distinctive features of Kawasaki disease-like illness related to SARS-CoV-2 include older age, more frequent Sub-Saharan African ancestry, gastrointestinal involvement, shock, myocarditis, lymphopenia, and higher levels of inflammatory markers.
- Because severe gastrointestinal symptoms and shock can occur before the diagnosis becomes clear, it is essential to recognize the early signs of the disease, so that appropriate management, including IVIG and corticosteroids, can be initiated. Cardiovascular markers such as Troponin I and BNP may help in this situation.

was very unlikely in our patient because of his increased levels of fibrinogen. Hence, hyponatremia was more probably due to inappropriate release of antidiuretic hormone. Thrombocytopenia may be the consequence of increased platelet adhesion to the activated endothelium, but it also may be interpreted as a sign of disseminated intravascular coagulation, sometimes occurring in the first 2 weeks of KD. Also, thrombocytopenia is considered a risk factor for coronary artery abnormalities (1). Increased D-dimers and prolongation of prothrombin time were consistent with this hypothesis, but might also reflect coagulation abnormalities classically observed during SARS-CoV-2 infection.

Troponin I and BNP concentrations were increased in our patient, as reported in 80% of cases from our previously published series of KD-like illness related to SARS-CoV-2 (6), and decreased very quickly together with inflammatory markers after IVIG. This may reflect that myocarditis is due to inflammatory cell infiltration with myocardial edema rather than ischemia and necrosis (1). These biomarkers of myocardial injury may be particularly relevant, as Troponin I and N-terminal pro-BNP (NT-proBNP) concentrations were shown to be predictors of coronary artery lesions in KD (10).

The high concentrations of inflammatory markers in our patient may have contributed to the distributive component of shock, as described in KDSS and MIS-C (1, 3, 6). In adults, COVID-19 was found responsible for a cytokine storm with very high concentrations of proinflammatory cytokines. However, the positivity of IgG antibodies against SARS-CoV-2 in this patient, as reported in 90% of cases from our previously published series (6), was more suggestive of a strong post-viral immunological reaction, usually occurring 2–10 weeks after SARS-CoV-2 infection, than of a direct proinflammatory action of SARS-CoV-2. Rapid resolution of all clinical, laboratory, and imaging abnormalities after IVIG supported the hypothesis of KD-like multisystem acute vasculitis in our patient.

Besides intensive care support and IVIG, the treatment of KDSS relies on corticosteroids (3). This patient did not receive corticosteroids because, at this stage of the pandemic, the safety of steroids in patients with COVID-19 was disputed. The patient did not show resistance to IVIG, but he developed coronary dilation. We now recommend systematic additional corticosteroid treatment for KD-like illness related to SARS-CoV-2 with shock or myocarditis (6).

## CASE FOLLOW-UP

The patient was discharged home after 8 days of hospitalization with complete resolution of all symptoms and decreased CRP and PCT concentrations, at 8.5 mg/L and 1.0 µg/L, respectively, that were controlled at <0.5 mg/L and 0.04 µg/L one week later. Troponin I concentrations trended down, from 447 ng/L to 62 ng/L at day 7 of hospital stay, and 19 ng/L one week after discharge. Low dose aspirin (5 mg/kg/day) was maintained and echocardiography performed one month later showed complete normalization of coronary arteries and cardiac function, also confirmed by cardiac magnetic resonance imaging (MRI).

**Nonstandard Abbreviations:** COVID-19, coronavirus disease-2019; CRP, C-reactive protein; IVIG, intravenous immunoglobulins; KD, Kawasaki disease; KDSS, KD shock syndrome; MIS-C, multisystem inflammatory system in children; NT-proBNP, N-terminal pro-BNP; RT-PCR, reverse transcription polymerase chain reaction; SARS-CoV-2, severe acute respiratory syndrome coronavirus 2.

**Author Contributions:** All authors confirmed they have contributed to the intellectual content of this paper and have met the following 4 requirements: (a) significant contributions to the conception and design, acquisition of data, or analysis and interpretation of data; (b) drafting or revising the article for intellectual content; (c) final approval of the published article; and (d) agreement to be accountable for all aspects of the article thus ensuring that questions related to the accuracy or integrity of any part of the article are appropriately investigated and resolved.

**Authors' Disclosures or Potential Conflicts of Interest:** *No authors declared any potential conflicts of interest.*

**Acknowledgments:** The authors thank the patient and his parents. They also thank the staff from the units who were involved in the diagnosis and clinical care of the patient, especially the pediatric intensive care unit, as well as Prof. Martin Chalumeau, Prof. Christèle Gras-Leguen, Prof. Sylvain Renolleau, Prof. Marianne Leruez, Prof. Véronique Abadie, Dr. Melissa Taylor, Dr. Agathe Debray, and Dr. Yael Pinhas for their contribution during various stages of the patient management and manuscript preparation.

**Ethics:** The authors have obtained written parental consent for publication.

## References

1. McCrindle BW, Rowley AH, Newburger JW, Burns JC, Bolger AF, Gewitz M, et al Diagnosis, treatment, and long-term management of Kawasaki disease: a scientific statement for health professionals from the American Heart Association. *Circulation* 2017;135:e927.
2. Kanegaye JT, Wilder MS, Molkara D, Frazer JR, Pancheri J, Tremoulet AH, et al Recognition of a Kawasaki disease shock syndrome. *Pediatrics* 2009;123:e783.
3. Li Y, Zheng Q, Zou L, Wu J, Guo L, Teng L, et al Kawasaki disease shock syndrome: clinical characteristics and possible use of IL-6, IL-10 and IFN-gamma as biomarkers for early recognition. *Pediatr Rheumatol* 2019;17:1.
4. Riphagen S, Gomez X, Gonzalez-Martinez C, Wilkinson N, Theocharis P. Hyperinflammatory shock in children during COVID-19 pandemic. *The Lancet* 2020; 395:1607-8. 10.1016/S0140-6736(20)31094-1
5. Verdoni L, Mazza A, Gervasoni A, Martelli L, Ruggeri M, Ciuffreda M, et al An outbreak of severe Kawasaki-like disease at the Italian epicentre of the SARS-CoV-2 epidemic: an observational cohort study. *Lancet* 2020;395:1771-8.
6. Toubiana J, Poirault C, Corsia A, Bajolle F, Fourgeaud J, Angoulvant F, et al Kawasaki-like multisystem inflammatory syndrome in children during the covid-19 pandemic in Paris, France: prospective observational study. *BMJ* 2020;369:m2094.
7. Pouletty M, Borocco C, Ouldali N, Caseris M, Basmaci R, Lachaume N, et al Paediatric multisystem inflammatory syndrome temporally associated with SARS-CoV-2 mimicking Kawasaki disease (Kawa-COVID-19): a multicentre cohort. *Ann Rheum Dis* 2020; 79:999-1006.
8. Feldstein LR, Rose EB, Horwitz SM, Collins JP, Newhams MM, Son MBF, et al Multisystem inflammatory syndrome in U.S. children and adolescents. *N Engl J Med* 2020;383:334-6.
9. Whittaker E, Bamford A, Kenny J, Kaforou M, Jones CE, Shah P, et al Clinical characteristics of 58 children with a pediatric inflammatory multisystem syndrome temporally associated with SARS-CoV-2. *JAMA* 2020;324:259-69.
10. Xue M, Wang J. Utility of color Doppler echocardiography combined with clinical markers in diagnosis and prediction of prognosis of coronary artery lesions in Kawasaki disease. *Exp Ther Med* 2020;19:2597-603.

## Commentary on Gastrointestinal Symptoms Followed by Shock in a Febrile 7-Year-Old Child during the COVID-19 Pandemic

Paul O. Collinson\*

High-sensitivity cardiac troponin (cTn) assays are currently the best tool to detect subtle myocardial injury. More sensitive than myocardial imaging, high-sensitivity assays have been estimated to detect necrosis of 40 mg of myocardial tissue—the equivalent of detecting 1 sugar cube dropped into Loch Ness. In patients who are severely ill, increased cTn may occur because of myocardial infarction or ischemic or nonischemic myocardial injury. Increased cTn has been reported in adults with severe coronavirus disease 2019 (COVID-19) infection (1). As might be expected, cTn concentrations in these patients predict in-hospital death and correlate strongly with cardiac comorbidities (1). Conversely, COVID-19 infection in children is seen as a relatively benign condition with few, if any, significant adverse consequences. In this case report, Allali and colleagues

described an unusual presentation of COVID-19 commencing with gastrointestinal symptoms and rash and progressing to multisystem inflammatory syndrome resembling Kawasaki disease. They demonstrated that measurement of cTn using a high-sensitivity assay can be used to identify cardiac involvement and to monitor and guide treatment. The pathophysiology of COVID-19-associated myocardial injury is poorly understood. Notably, a multicenter cardiovascular pathology study did not demonstrate disrupted coronary artery plaque (2). In this study, multifocal myocarditis was identified in only 3 of 21 cases; 18 cases showed widespread interstitial macrophage infiltration of the myocardium without clearly associated myocardial injury, and 16 cases had increased troponin concentrations. Although there was no significant difference between those with or without myocarditis, there was a trend toward higher cTn concentrations with documented myocarditis. However, the authors considered that the etiology of myocardial injury in COVID-19 patients is not predominantly a viral myocarditis; rather, it reflects other pathophysiology, particularly the inflammatory state. Increased concentrations of C-reactive protein are a multivariate predictor of myocardial injury in COVID-19 infection (1).

Departments of Clinical Blood Sciences and Cardiology, St George's University Hospitals NHS Foundation Trust, London, UK

\*Address correspondence to this author at: Clinical Blood Sciences, St George's University Hospitals NHS Foundations Trust, Cranmer Terrace, London SW17 0QT, UK. Fax 011-208-725-6858; e-mail paul.collinson@ntlworld.com.

Received October 20, 2020; accepted October 28, 2020.

DOI: 10.1093/clinchem/hvaa291

©American Association for Clinical Chemistry 2021. All rights reserved.

For permissions, please email: journals.permissions@oup.com.